

<http://www.pjbs.org>

PJBS

ISSN 1028-8880

**Pakistan
Journal of Biological Sciences**

ANSI*net*

Asian Network for Scientific Information
308 Lasani Town, Sargodha Road, Faisalabad - Pakistan

RESEARCH ARTICLE

OPEN ACCESS

DOI: 10.3923/pjbs.2015.107.114

Toxicity Effect of Aflatoxin B1 on Reproductive System of Albino Male Rats

Abeer Fauzi Murad, Shaima Ahmed and Shaima Abeam

Department of Biology, College of Science for Women, Babylon University, Iraq

ARTICLE INFO

Article History:

Received: January 02, 2015

Accepted: May 06, 2015

Corresponding Author:

Abeer Fauzi Murad

Department of Biology,
College of Science for Women,
Babylon University, Iraq

ABSTRACT

Aspergillus flavus and *Aspergillus parasiticus* are two important molds that produce Aflatoxin (AF). Humans and animals can be exposed to aflatoxins by consuming foods contaminated with the products of these fungi. Aflatoxin B1 (AFB1) is one of the most common mycotoxins found in human foods. In general, acute toxicity by is AFB1 less likely to occur than chronic toxicity. The principal target organ for aflatoxins is liver which may lead to hepatocytes and necrosis and also can be carcinogenic and cause immunosuppression. AFB1 could be toxic to the male reproductive system in man as well as wild and domestic animals. According to this study the AFB1 effect on testis and sperm of male rats which revealed pathological changes in testis and epididymis, with the high dosage of AFB1 the edematous fluid inside the tumblers increases while there are significant ($p > 0.05$) decreases in the number of leydig cells, the height of seminiferous, as well as there was a significant decreasing in the number of spermatogenesis, spermatocytes and spermatids.

Key words: Toxicity, Aflatoxin B1, albino rats, epididymis, spermatogenesis

INTRODUCTION

Aflatoxins are secondary metabolites principally produced by *Aspergillus flavus* and *Aspergillus parasiticus* (Jacobsen *et al.*, 2007). Although twenty types of aflatoxins have been identified, only aflatoxin B1, B2, G1 and G2 are usually found together in feeds and feedstuffs in various proportions. However, AFB1 is the most toxic one. Direct consequences consumption of aflatoxins-contaminated feed include; decreased feed intake, feed rejection, poor feed conversion (Akande *et al.*, 2006), decreased body weight, increased disease incidence due to immune-suppression (Meissonnier *et al.*, 2006) and reduced reproductive capacities (El-Saad and Mahmoud, 2007) which leads to economic losses in agriculture and domestic animals (Wu, 2006). Also it can be carcinogenic, mutagenic, teratogenic, tremorgenic and hemorrhagic. It also cause damage in the central nervous system, liver or kidneys (Wangikar *et al.*, 2005; Akande *et al.*, 2006). Aflatoxins lead to acute toxicity with symptoms such as fever, oedema, vomiting, abdominal pain, inappetence and liver failure. During aflatoxicosis in rabbits, histopathological examination revealed vascular congestion, leucocytic

infiltration and degenerative changes in the affected organs during the initial stage of toxicosis. At its terminal stage, a coagulative necrosis, perivascular and per ductal fibro cellular reactions along with mononuclear-cellular infiltration and distortion of the hepatic chords were observed in the liver (Lakkawar *et al.*, 2004).

Exposure to aflatoxins is known to produce male reproductive toxic effects with several events which have been reported in previous studies. The target organs in causing male reproductive toxicity are the testicles and various aspects of spermatogenesis (Richburg, 2000). However, the epididymis can also be targeted by such reproductive toxicants (Akbarsha *et al.*, 2000; Krausz and Forti, 2000).

The seminiferous tubules show degeneration of the epithelium and reduction in the number of mature spermatids in aflatoxin treated rabbits (Lakkawar *et al.*, 2004). Generation of multinucleate giant spermatids or simplistic spermatids as one of the more symptoms of aflatoxicosis (Agnes and Akbarsha, 2003; Faridha *et al.*, 2007) were additionally observed.

This study shows the effect of aflatoxin B1 on male reproductive system in albino rats, it also focus on the

histological changes on testicles tissue and epididymis and some aspects of spermatogenesis and the consequent effects on cell counts and cell numbers.

MATERIAL AND METHODS

Animals: The experiment evaluated the chronic effects of oral administration of AFB1 on testis of adult male rats. Twenty adult male rats with a body weight of 250 ± 30 g were used. These rats were provided by the Center of Animal Housing of the Faculty of Science\Kufa University. The animals were placed in standard cages (2 animals per cage) for two weeks under 12 h light-dark cycle with 23-25°C room temperature for acclimation before beginning the study. All animals received standard laboratory animal's food and water *ad libitum* during the whole period of experiment.

Animals were divided randomly into two groups: Control group (C) and Experimental group (E) each containing 5 rats:

Group (E): The experimental group (E) was subdivided into three subgroups, each containing 5 rats as the following

Group (E1): Animals in this group received (15 μ L of AFB1/kg three times in the week) for 40 days

Group (E2): Animals in this group received (30 μ L of AFB1/kg three times in the week) for 40 days

Group (E3): Animals in this group received (45 μ L of AFB1/kg three times in the week) for 40 days

Group (C): Normal and apparently healthy rats that did not receive any type of treatment. All groups left for two weeks before killing

After oral administration of AFB1 which were obtained from Sigma chemical company, toxin doses were prepared in distilled water. Along with these dosages, a portion of testis and epididymis tissue from each group was preserved in a 10% formaldehyde solution for 24 h. Paraffin blocks were sectioned at 5 μ m thickness by rotary microtome for histopathological and histophotometric studies. Hemotoxylin and eosin were used for staining and later the microscopic slides of the testis and epididymis were photographed at a magnification of (X40, X10).

Morphometric examination: Microscopic examination of stained testicular and epididymis tissue sections was done for all groups. The following parameters were measured using a pre-calibrated ocular micrometer with stage micrometer to evaluate the extent of testicular and epididymis damage and the whole process was recorded through a list of figures, these parameters include:

- Diameter of the round seminiferous tubules. Thirty tubular profiles that were round or nearly round were chosen randomly and measured for each animal

- Height of the germinal epithelium was obtained in the same tubule sections utilized to determine tubular diameter
- Diameter of the epididymis tubules of caput epididymis were measured at 40X magnification
- Diameter lumen of epididymis tubules of caput epididymis were measured at 40X magnification
- Height of the germinal epithelium of caput epididymis were measured at 40X magnification
- Diameter lumen of epididymis tubules of caudal epididymis were measured at 10X magnification

Cell counts and cell numbers: To evaluate the efficiency of spermatogenesis, 50 seminiferous tubules selected from each group were evaluated for spermatogonia, spermatocytes and spermatids. The sertoli cell counts and the leydig cell numbers were evaluated in the interstitial tissue. The average of the different cell counts of each animal was used for the analysis. The evaluation of the all samples was performed at a constant magnification 40X with light microscopy. The Sertoli cell index was calculated by dividing the sum of the counted spermatogonia and spermatocytes via the sertoli cell numbers per tubule (Russell *et al.*, 1990).

RESULTS

The clinical signs recorded in AFB1 treated animals include hair fall, loss of appetite and marked decrease in body weights. However, the degeneration of spermatogonial cells lining seminiferous tubules, edema associated with marked atrophy of seminiferous tubules as well as focal hemorrhage and disturbed process of spermatogenesis as shown in Fig. 1. The study concludes that AFB1 causes pathological changes in epididymis including degeneration and necrosis of epithelial cells of sperm tubules and reduces the number of sperms inside the cavity of tubules as in the case of high concentration of toxin there was no sperm in the cavity. The changes at the top of epididymis include necrosis of epithelium cells of tubules and edema and the presence of edematous fluid inside the tumbles. These changes increased with high dosage of AFB1 Fig. 2 and 3.

As shown in Fig. 4a and b there is a significant ($p > 0.05$) decrease in the numbers of leydig cells and the height of seminiferous tubules in animals treated with (15, 30, 45 ppm) AFB1 in comparison with the control group. There was a significant reduction ($p > 0.05$) in the number and the index of sertoli cells as a result of AFB1 dosage when compared with control group Fig. 4c and d. The number of spermatogenesis, spermatocytes as well as spermatids is significantly ($p > 0.05$) reduced with the increasing of toxin concentration as seen in Fig. 5a-c. With the increase in the AFB1 dosage concentration, the diameter of caput epididymis were significantly ($p > 0.05$) decreased while the height of caput epididymis also highly reduced in the 30 and 45 ppm concentration of AFB1

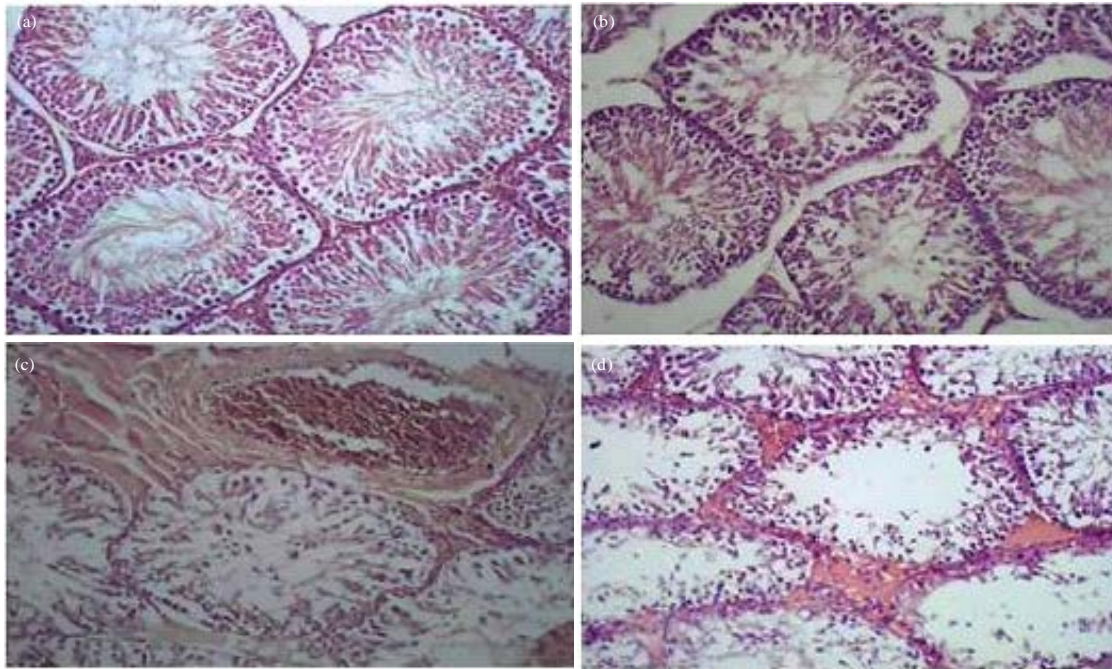


Fig. 1(a-d): Cross section in testicular male rats treated with AFB1 (200X), (a) Control treatment, (b) 15 ppm concentration notes the starting of degeneration of spermatogenesis, (c) 30 ppm concentration shows high degree of degeneration of spermatogenesis cells and (d) 45 ppm concentration shows focal hemorrhage and disturbed process of spermatogenesis

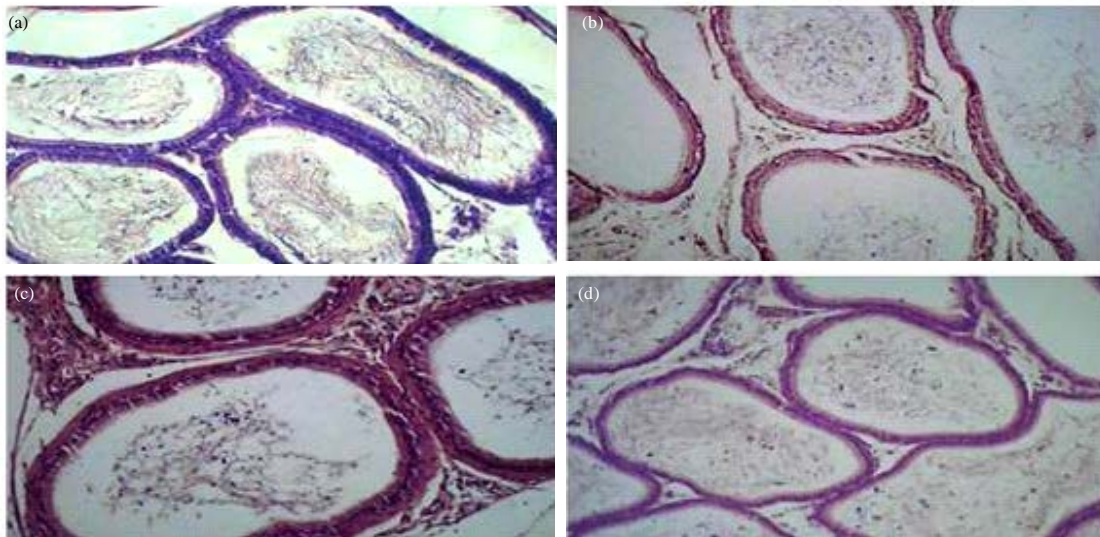


Fig. 2(a-d): Cross-section of epididymis tail of male rats treated with AFB1 (140X), (a) Control treatment, (b) 15 ppm concentration shows degeneration of epithelial cells and epithelializes seminiferous tubules to the tail of the epididymis, (c) 30 ppm concentration shows necrosis of the epithelium and decrease in sperm number and (d) 45 ppm concentration shows increasing necrosis of the epithelium and decrease in sperm number

treatment as shown in Fig. 6a-d indicate that AFB1 causes significant ($p>0.05$) reduction in the diameters rate of lumen

caput epididymis (head cavity) and the diameters rate of lumen cauda epididymis with the increase in toxin concentration.

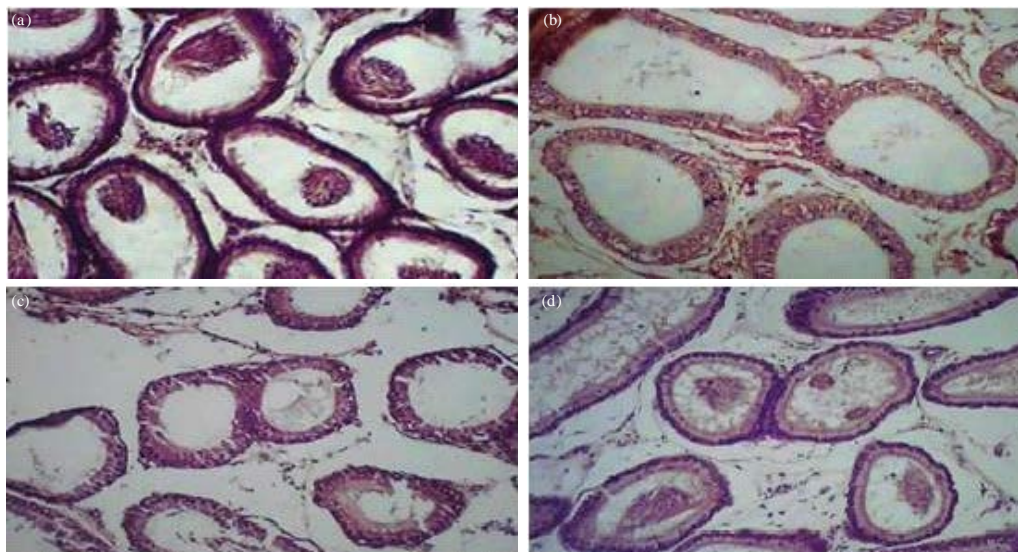


Fig. 3(a-d): Cross-section at the top of epididymis of male rats treated with AFB1 140X. (a) Control treatment, (b) 15 ppm concentration shows necrosis in tubule epithelium and there is no sperm, (c) 30 ppm concentration revealed necrosis of tubules epithelium and the presence of edematous fluid inside tubule and (d) 45 ppm concentration, in addition to the previous symptoms notes spread of edematous liquid inside the tubules the absence of the sperm inside the tubules

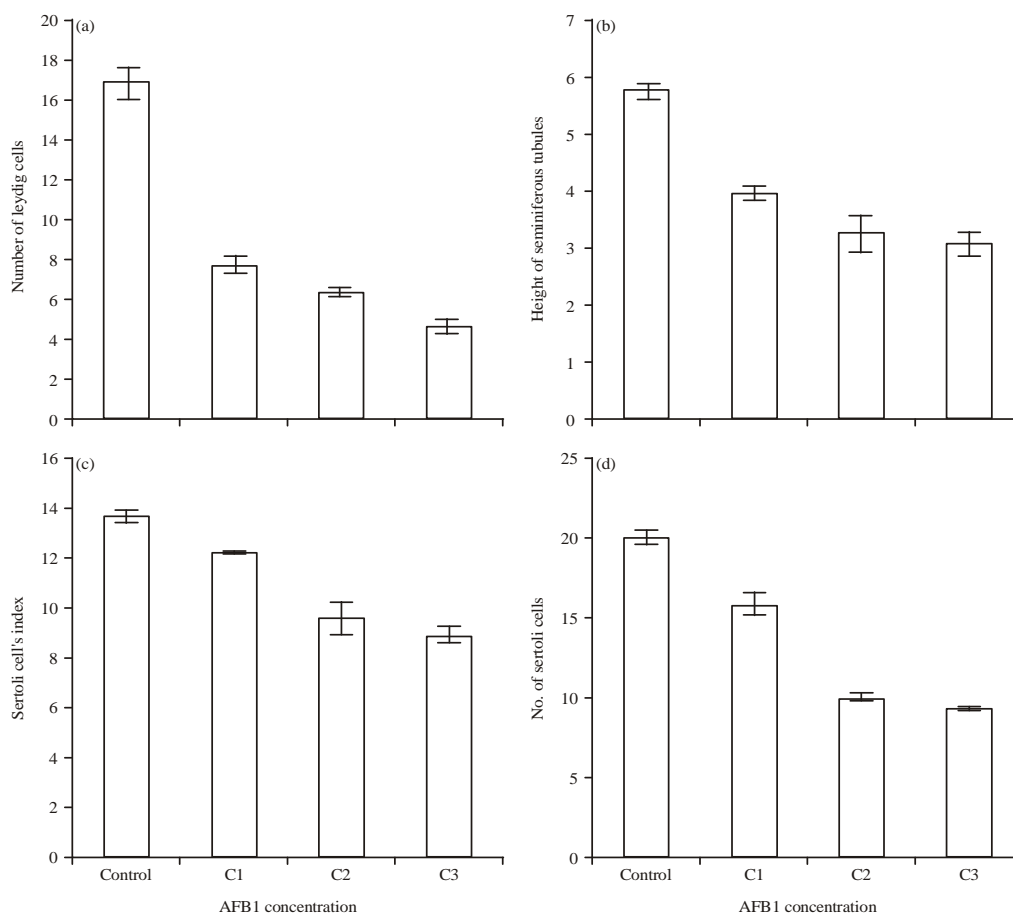


Fig. 4(a-d): Comparison of (a) No. of Leydig cells, (b) Height of seminiferous tubules, (c) Index and (d) $p > 0.05$ No. of Sertoli cells with AFB1 concentration at $p > 0.05$, C1: 15 ppm, C2: 30 ppm, C3: 45 ppm

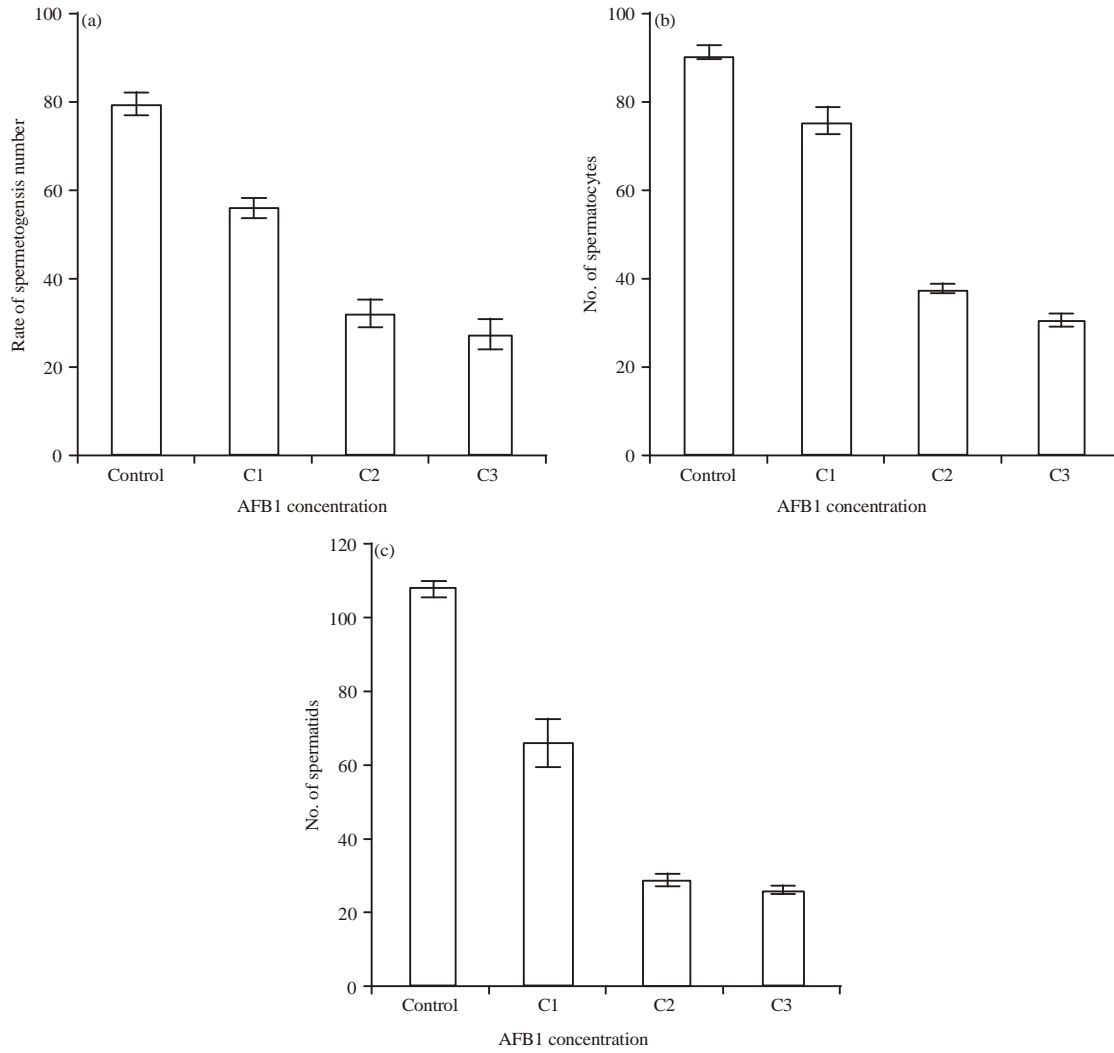


Fig. 5(a-c): Comparison of (a) Rate of spermatogenesis number, (b) Rate number of spermatocytes and (c) No. of spermatids with AFB1 concentration at $p > 0.05$, C1:15 ppm of AFB1, C2:30 ppm AFB1, C3:45 ppm AFB1

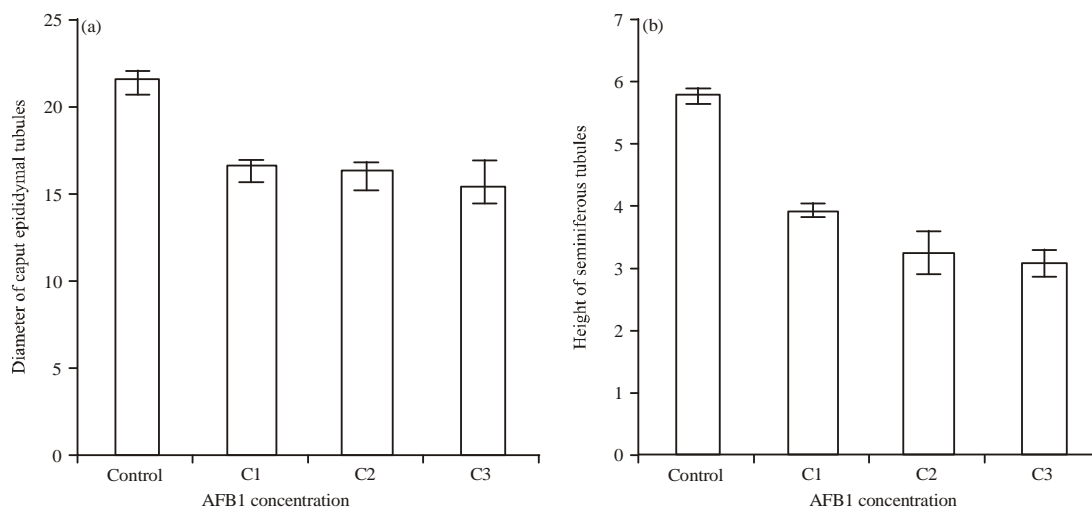


Fig. 6(a-d): Continue

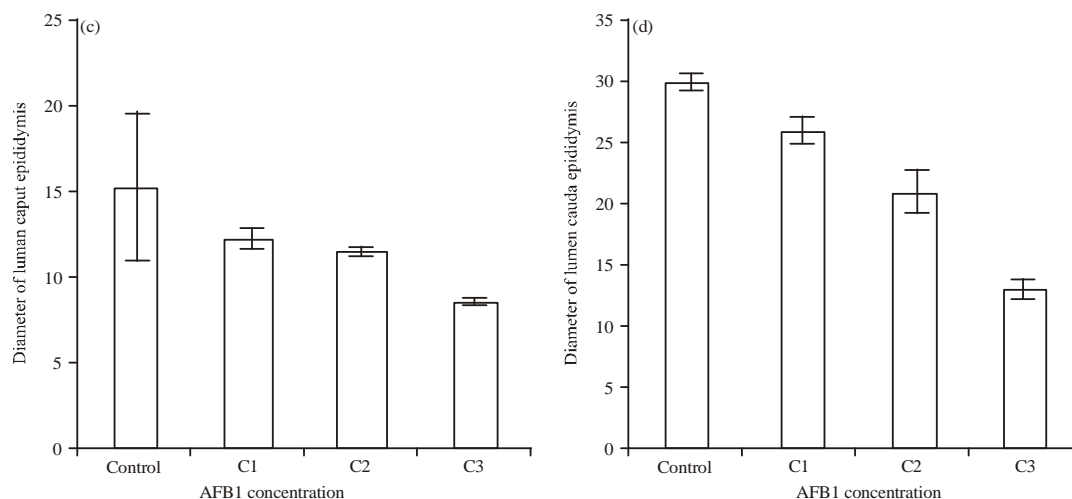


Fig. 6(a-d): Comparison of (a) Diameter of caput epididymis tubules, (b) Height of caput epididymis, (c) Diameters rate of lumen caput epididymis and (d) Diameters rate of lumen cauda epididymis, with AFB1 concentration at $p > 0.05$, C1:15 ppm, C2:30 ppm, C3:45 ppm

DISCUSSION

As it was explained in the result, AFB1 causes pathological changes in testicles and epididymis including degeneration and necrosis of epithelial cells of sperm tubules and reduces the number of sperms. One of the earliest studies indicating morbidity of reproductive efficiency due to AF toxicity was done by Maryamma and Sivadas (1975) who reported that continuous feeding of a diet containing 0.7 ppm AF produces testicular degeneration in male goats. There have been other reports which indicate that AFB1 causes delay in physiological and behavioral sexual maturation and also delays testicular development in Japanese quail (Doerr and Ottinger, 1980). It has been additionally discovered that AFB1 decreases semen volume and testis weight and leads to the disruption of the germinal epithelium in mature male white Leghorn chicks (Sharlin *et al.*, 1980).

The testicular changes in this study are harmonious with the result of earlier studies (Lakkawar *et al.*, 2004; Faridha *et al.*, 2007). Faridha *et al.* (2007) for example fed adult male rats with aflatoxin diet for prolonged period, showed regressive changes of different intensity in the germinal epithelium of the seminiferous tubules resulting in a severe dystrophic alteration of the spermatogenic epithelium along with edematous changes in the interstitial tissue. Another study by El-Shewy and Ebrahim (2004) revealed the degeneration of lining epithelium of seminiferous tubules and congestion of testicular blood vessels with intertubular oedema in the rats treated with AFB1. Moreover, coagulative necrosis of entire lining epithelium of some seminiferous tubules replaced by homogenous eosinophilic debris in their lumina was also noticed.

In a similar study, Agnes and Akbarsha (2003) reported that the prevalence of cell ruins in the sperm suspension of

mice treated for 35 and 45 days with AFB1 proves that this toxin affects the albino mouse epididymal sperm concentration. Another study suggested that the decreased sperm count might indicate severe impact of AFB1 on spermatogenesis. Thus, aflatoxin has direct effect on sperm (Salem *et al.*, 2001). Tajik *et al.* (2007) showed that aflatoxin has direct spermatotoxic effects on ejaculatory and epididymal ram sperm.

The present experiment also showed that AFB1 reduces significantly the numbers of leydig cells, the height of seminiferous tubules, the number and the index of sertoli cells, the diameter of caput epididymis and lumen caput epididymis. The number of spermatogenesis, spermatocytes as well as spermatids is also reduced.

According to a study by Nair and Verma (2000), following the intraperitoneal injection of AFB1 at the rate of 25 and 50 mg/mice/day for a duration of 48 days, the population of germ cells in the seminiferous tubules was disrupted, decreased considerably and became disorganized. In these animals, degenerative changes in leydig cells were also observed. Moreover, significant changes in sperm count at the tail of epididymis were noticed along with a reduction in sperm motility. This study confirms that toxicity with AFB1 causes adverse histological changes in seminiferous tubules and these changes involve both the spermatogenic cell series and interstitial tissue (Leydig cells). In a similar experiment that involved roosters treated with AF at 5, 10 and 20 ppm concentrations in the diet for 8 weeks, the testis were atrophied, the incidence of abnormal spermatozoa increased and the epithelium was desquamated. No spermatogenesis occurred in several birds. The size and thickness of the generative layer and the level of plasma testosterone also decreased (Ortatatli *et al.*, 2002). Disruption of androgen synthesis and sperm function was observed in male mice treated AFB1 at 50-60 mg kg⁻¹ body weight/day for

30 days (Egbunike, 1979, 1982; Egbunike *et al.*, 1980; Ikegwuonu *et al.*, 1980). In a study done on mice by Faridha *et al.* (2006) histopathological changes were noted in the testis appearance of small to large vacuoles in the epithelium including decrease or absence of elongating spermatids. Due to the effect of AFB1-treatment on the leydig cells, there were regression of testis, morbidness of spermatogenesis and loss of germ cells. Continuous feeding on a diet containing 0.7 ppm aflatoxin caused regression of testis, impairment of spermatogenesis, premature loss of germ cells and pathological changes in the leydig cells (Ortatatli *et al.*, 2002). Agnes and Akbarsha (2003) have similarly reported the effects of AFB1 on albino mouse epididymis sperm concentration.

The clinical signs recorded in animals treated with AFB1 include hair fall, loss of appetite and marked decrease in body weights. This result agrees with another study done by Lakkawar *et al.* (2004).

CONCLUSION

Aflatoxins are extremely potent mycotoxins which produce serious health hazards in different animal species. It has also been reported that aflatoxins have a deleterious effect on the reproductive systems of a wide spectrum of domestic animals. This study shares the opinion that the presence of AFB1 in feed and feedstuff at graded doses induced severe toxicity and damage in the testis in male rats and causes different histopathological changes in testis tissue and epididymis and also reduce the number of spermatogenesis, spermatocytes, spermatids, leydig cells and sertoli cells.

REFERENCES

Agnes, V.F. and M.A. Akbarsha, 2003. Spermatotoxic effect of aflatoxin B₁ in the albino mouse. *Food Chem. Toxicol.*, 41: 119-130.

Akande, K.E., M.M. Abubakar, T.A. Adegbola and S.E. Bogoro, 2006. Nutritional and health implications of mycotoxins in animal feeds: A review. *Pak. J. Nutr.*, 5: 398-403.

Akbarsha, M.A., H.I. Averal, R. Girija, S. Anandhi and A.F. Banu, 2000. Male reproductive toxicity of vincristine: Ultrastructural changes in the epididymal epithelial apical cell. *Cytobios*, 102: 85-93.

Doerr, J.A. and M.A. Ottinger, 1980. Delayed reproductive development resulting from aflatoxicosis in juvenile Japanese quail. *Poult. Sci.*, 59: 1995-2001.

Egbunike, G.N., 1979. The effects of micro doses of aflatoxin B₁ on sperm production rates, epididymal sperm abnormality and fertility in the rat. *Zentralblatt fur Veterinarmedizin Reihe A*, 26: 66-72.

Egbunike, G.N., G.O. Emerole, T.A. Aire and F.I. Ikegwuonu, 1980. Sperm production rates, sperm physiology and fertility in rats chronically treated with sublethal doses of aflatoxin B₁. *Andrologia*, 12: 467-475.

Egbunike, G.N., 1982. Steroidogenic and spermatogenic potentials of the male rat after acute treatment with aflatoxin B₁. *Andrologia*, 14: 440-446.

El-Saad, A.S.A. and H.M. Mahmoud, 2007. Phytic acid exposure alters aflatoxinB1-induced reproductive and oxidative toxicity in Albino rats (*Rattus norvegicus*). *Evidence-Based Complement. Altern. Med.*, 6: 331-341.

El-Shewy, E.A. and M.F. Ebrahim, 2004. Ameliorative effect of vitamin E against the toxicity of aflatoxin B1 on rats with special reference to its effect on male fertility. *Proceedings of the 1st Annual Conference FVM*, September 2004, Moshtohor, pp: 189-214.

Faridha, A., K. Faisal and M.A. Akbarsha, 2006. Duration-dependent histopathological and histometric changes in the testis of aflatoxin B₁-treated mice. *J. Endocrinol. Reprod.*, 102: 117-133.

Faridha, A., K. Faisal and M.A. Akbarsha, 2007. Aflatoxin treatment brings about generation of multinucleate giant spermatids (symplasts) through opening of cytoplasmic bridges: Light and transmission electron microscopic study in Swiss mouse. *Reprod. Toxicol.*, 24: 403-408.

Ikegwuonu, F.I., G.N. Egbunike, G.O. Emerole and T.A. Aire, 1980. The effects of aflatoxin B₁ on some testicular and kidney enzyme activity in rat. *Toxicology*, 17: 9-16.

Jacobsen, B.J., R.W. Coppock and M.S. Mostrom, 2007. *Mycotoxins and mycotoxicoses*. Montana State University Extension Publication EBO174, Montana State University, Bozeman, MT.

Krausz, C. and G. Forti, 2000. Clinical Aspects of Male Infertility. In: *The Genetic Basis of Male Infertility*, McElreavey, K., (Ed.). Springer Science and Business Media, New York, USA., ISBN-13: 9783540662648, pp: 121.

Lakkawar, A.W., S.K. Chattopadhyay and T.S. Johri, 2004. Experimental aflatoxin B₁ toxicosis in young rabbits-a clinical and patho-anatomical study. *Slov. Vet. Res.*, 41: 73-81.

Maryamma, K.I. and C.G. Sivasdas, 1975. Aflatoxicosis in goats: An experimental study. *Indian Vet. J.*, 52: 385-392.

Meissonnier, G.M., D.E. Marin, P. Galtier, G. Bertin, I. Taranu and I.P. Oswald, 2006. Modulation of the Immune Response by a Group of Fungal Food Contaminant, the Aflatoxins. In: *Nutrition and Immunity*, Mengheri, E., M. Roselli, M.S. Britti and A. Finamore (Eds.). Research Signpost, Kerala, India, pp: 147-166.

Nair, A. and R.J. Verma, 2000. Effect of aflatoxin on histoarchitecture of testis of male mouse and its amelioration by vitamin E. *Indian J. Toxicol.*, 114: 452-462.

Ortatatli, M., M.K. Ciftci, M. Tuzcu and A. Kaya, 2002. The effects of aflatoxin on the reproductive system of roosters. *Res. Vet. Sci.*, 72: 29-36.

Richburg, J.H., 2000. The relevance of spontaneous-and chemically-induced alterations in testicular germ cell apoptosis to toxicology. *Toxicol. Lett.*, 112, 113: 79-86.

- Russell, L.D., R.A. Ettlin, A.P. Hikim and E.D. Clegg, 1990. The Classification and Timing of Spermatogenesis. In: Histological and Histopathological Evaluation of the Testis, Lonnie, D.R. and R. Ettlin (Eds.). Cache River Press, Clearwater, FL., ISBN-13: 978-0962742200.
- Salem, M.H., K.I. Kamel, M.I. Yousef, G.A. Hassan and F.D. EL-Nouty, 2001. Protective role of ascorbic acid to enhance semen quality of rabbits treated with sublethal doses of aflatoxin B₁. *Toxicology*, 162: 209-218.
- Sharlin, J.S., B. Howarth Jr. and R.D. Wyatt, 1980. Effect of dietary aflatoxin on reproductive performance of mature White Leghorn males. *Poult. Sci.*, 59: 1311-1315.
- Tajik, P., P. Mirshokraee and A. Khosravi, 2007. Effects of different concentrations of aflatoxin B on ram epididymal and ejaculatory sperm viability and motility *in vitro*. *Pak. J. Biol. Sci.*, 10: 4500-4504.
- Wangikar, P.B., P. Dwivedi, N. Sinha, A.K. Sharma and A.G. Telang, 2005. Teratogenic effects in rabbits of simultaneous exposure to ochratoxin A and aflatoxin B₁ with special reference to microscopic effects. *Toxicology*, 215: 37-47.
- Wu, F., 2006. Economic Impact of Fumonisin and Aflatoxin Regulations on Global Corn and Peanut Markets. In: The Mycotoxin Factbook: Food and Feed Topics, Barug, D., D. Bhatnagar, H.P. Van Egmond, J.W. Van Der Kamp, W.A. Van Osenbruggen and A. Visconti (Eds.). Wageningen Academic Pub., Netherlands, ISBN-13: 978-9086860067, pp: 83-94.