

Precautionary Effect of *Ginkgo biloba* Against Mercury-Induced Acute Nephro-Hepatotoxicity in male Rats

Shaima Obead Abd-Allh

Biology department- collage of science for woman –Babylon university
shaimabio99@gmail.com

Abstract

Mercury (II) is an important factor in nephro-hepatotoxicity that can enter the body through marine diets and amalgams. The present study was designed to investigate the protective effect of the *Ginkgo biloba* leaves (GB) extract on acute mercury intoxication on the liver and kidney. Rats were divided into six groups. Group I as control; group II and III rats were injected intraperitoneal with GB extract at dose of (200,400) mg/kg.b.wt/day for twenty five days, group IV rats were given orally of mercuric chloride at dose (5 mg/kg b.wt) for five days ,group V were given mercuric chloride (5 mg/kg) for five days then rats received GB extract at dose (200 mg/kg/day) intraperitoneal for twenty five day ,and groupe VI rats were orally given mercuric chloride (5 mg/kg) for five days then rats received GB extract at dose (400 mg/kg/day) intraperitoneal for twenty five day, Twenty four hrs after last treatment all rats were euthanized ,all groups were treated daily . Mercury induced a significant increase in malondialdehyde (MDA) and a significant reduction in reduced glutathione (GSH) levels in tissue liver and kidney, significant changes in serum hepatic and renal function parameters (, alkaline phosphatase (ALP), total protein, , uric acid and creatinine.), Mercury founded marked degenerative and necrotic alterations in kidneys and liver tissue . *Ginkgo biloba* returned MDA and GSH to the normal values, improved the mercury-induced serum biochemical changes of kidney and liver functions as well as histopathological & histophotometry alteration. Our results suggest that acute mercury intoxication induced marked nephro-hepatic deleterious effects which were corrected by *ginkgo biloba* treatment.

Keywords: *Ginkgo biloba* , mercury , nephro-hepatotoxicity , reduced glutathione , malondialdehyde .

الخلاصة

يعد الزئبق من العوامل البيئية المهمة التي تدخل الى الجسم عن طريق الاغذية البحرية والذي يسبب سمية واضحة للكبد والكلية على حد سواء.

الدراسة الحالية صممت للتحري عن الدور الوقائي للمستخلص المائي لاوراق نبات الجنكة بابلوبا ضد التسمم الحاد للكبد والكلية المتسبب عن التعرض للزئبق . قسمت حيوانات التجربة الى ستة مجاميع ، المجموعة الاولى عدت كمجموعة سيطرة عوملت بالمحلول الملحي الفسيولوجي ، المجموعة الثانية والثالثة حقنت تحت الغشاء البريتوني بالمستخلص المائي لاوراق نبات الجنكة ولمدة خمسة وعشرون يوماً وبالتركيز (200و400) مايكروغرام /كغم /يوم على التوالي ، المجموعة الرابعة اعطيت فموياً كلوريد الزئبق عند الجرعة 5 مايكروغرام /كغم من وزن الجسم لمدة خمسة ايام ، اما المجموعة الخامسة فقد اعطيت فموياً كلوريد الزئبق عند الجرعة 5ماكروغرام /كغم لمدة خمسة ايام ثم حقنت تحت الغشاء البريتوني بالمستخلص المائي لاوراق نبات الجنكة ولمدة 25 يوم عند التركيز 200مايكروغرام /كغم / يوم ، فيما استلمت المجموعة السادسة كلوريد الزئبق لمدة خمسة ايام ثم حقنت بالمستخلص المائي لاوراق نبات الجنكة عند التركيز 400مايكروغرام /كغم /يوم تحت الغشاء البريتوني . جميع المجاميع عوملت يومياً حسب الجرعة المقررة . بعد 24 ساعة على اخر جرعة معطاة جميع الحيوانات شرحت واجريت عليها معايير الدراسة. سببت المعاملة بالزئبق زيادة معنوية في مستوى المالونديهايد ونقصان معنوي في مستوى الكلوتاثيون في انسجد الكبد والكلية وكذلك تغيرات واضحة في الاختبارات الكيموحياتية والتي عدت كمعيار لكفاءة وظيفة الكبد والكلية والمتمثلة بقياس مستوى الفوسفاتيز القاعدي ومستوى البروتين الكلي كدليل حول كفاءة وظيفة الكبد وقياس مستوى حامض اليوريك والكرياتين كدليل لكفاءة وظيفة الكلية .فضلاً عن حدوث تغيرات نسجية واضحة في انسجة الكبد والكلية . المعاملة بالمستخلص المائي لاوراق نبات الجنكة اعادت المستوى الطبيعي لكل من المالونديهايد والكلوتاثيون ، حسنت من التغيرات التي احدثها الزئبق في مستوى الاختبارات الكيموحياتية ، فضلاً عن التحسن في خلايا وانسجة الكبد والكلية.النتائج الحالية اقترحت بأن المستخلص المائي لاوراق نبات الجنكة قادر على اصلاح الضرر المتسبب عن التسمم بالزئبق في الكبد والكلية.

الكلمات المفتاحية : جنكة بابلوبا ، الزئبق ، التسمم الكلوي-الكبد ، الكلوتاثيون ، المالونديهايد.

Introduction

The metabolic activities of vital organ such as kidney, liver and, brain are characterized for Health condition of an animal and human then as the Liver plays a pivotal role in regulating various physiological processes in the body such as metabolism, secretion , storage.(Mohamed,*et al.*2014) and the metabolism of endogenous and exogenous molecules and it eases their detoxification and elimination . for maintaining the homeostasis of the body(Mroueh *et al.*, 2004) because the liver is the primary biotransformation site of many xenobiotics. therefore The liver has key importance in toxicological processes .

Human activities are mainly responsible for promoting the pollution in the environment by introducing of unwanted toxic compounds. There is an accumulating contamination of water sources and food chain with these compounds. Four principle categories of pollutants, which jeopardize the environments, are radio nucleotides, petroleum hydrocarbons, pesticides and heavy metals. Among these, heavy metals are the most dangerous ones because of their stability in the biological system (Lu, 1996). Hence, industrial pollution of the environment with metal compounds is becoming a significant problem (Foulkes, 1990)

Mercury (Hg) is a highly toxic metal (Al-Othman *et al.*, 2011; Nabi *et al.*, 2010), causes a variety of adverse health effects including immune, renal, dermatologic , development sequel neurological, reproductive and respiratory (Risher and Amler, 2005). and can cause biochemical damage to tissues through diverse mechanisms such as lipid peroxidation (Huang *et al.*, 1996), altering protein synthesis (Yee and Choi, 1996) and via binding to thiol groups (Zalups, 2000). Many studies *in vivo* and *in vitro* have demonstrated that mercury induced lipid peroxidation, suggesting the involvement of oxidative stress in its cytotoxicity (Necib, *et al.*2013)and leading to increase in levels of reactive oxygen species (ROS). Reactive oxygen species (ROS) are involved in many cellular metabolic and signaling processes. ROS easily react with most biological macromolecules causing their degradation and destruction. ROS can cause cellular injury through their actions on phospholipids, proteins, and nucleic acids. High oxidative stress leads to depletion of enzymatic and nonenzymatic antioxidants. The unsaturated lipid molecules of cell membranes are particularly susceptible to this damaging free radicals process and readily contribute to the uncontrolled chain reaction.(Singh ,*et al.*2014). The toxicity of Hg depends on the form of the Hg compounds (elemental, inorganic, and organic). Inorganic Hg is a potential hepatotoxic and accumulates predominantly in the kidneys, causing acute renal failure.(Tanaka-Kagawa, *et al.*1998; Emanuelli, *et al.*1996) Therefore, liver damage inflicted by hepatotoxic agents and Liver function impaired (Mroueh *et al.*, 2004).

Alterations in kidney structure and function are frequently encountered in severe liver diseases (Lundh, 1964) but the relationship between the hepatic and renal disorders is not clear. The possibilities are that the agent(s) precipitating the liver disease may affect the kidney directly or that the renal lesions develop as a secondary phenomenon to the altered liver function(Kumar *et al.*, 2012; Xu *et al.*, 2004).

Mercury is proven to be a potential oxidant in the category of environmental factors. Therefore, there is a need to provide protection against mercury induced toxicity. Nephro-hepatoprotective studies showed that plants have active ingredients that are capable of free radical scavenging in living systems.

Ginkgo biloba is a popular herb used in traditional Chinese medicine. Ginkgo was first mentioned in the Shen Nong Ben Cao Jing, taken into account the oldest tree species on earth, with maidenhair trees having been illustrious to measure over a median of one, thousand years or a lot of (Bystrianyk ,2010). The leaves of the ginkgo tree, conjointly referred to as fern, area unit the supply of this herb, as a medical plant for ameliorative the state of mind, blood circulation, and metabolic process operate (Chan *et al.* 2007), whereas in

current Chinese drugs, maidenhair tree is especially accustomed calm wheezy, stop pain, and treat hypercholesteremia, high blood pressure, artery un wellness, heart condition, and vessel unwellness (Huang *et al*,2013). Recently, the extract from *G. biloba* leaves has been among the foremost ordinarily prescribed flavouring dietary remedy within the United States , France, and Germany., maidenhair tree has been shown to possess inhibitor activity and to assist within the interference and treatment of diseases related to free radicals together with cancers (Suzuki *et al.*, 2004), . the two teams of serious compounds found in maidenhair tree area unit flavonoids, like myricetin and quercetin, which give for the antioxiant action, and terpenes that facilitate inhibit the formation of blood clots. These compounds decrease the injury that happens as a result of free radicals (Bystrianyk ,2010).(this herb is not found in Iraq)

To the best of our knowledge, there are no studies concerning the nephro-hepatoprotective effect of *gingko biloba* against mercury intoxication. Therefore, the present study was carried out to investigate (1) the adverse effect of acute mercury intoxication on the kidneys as well as liver based on serum biochemical parameters, oxidative stress and histopathological alterations and (2) The probable alleviating effect of *gingko biloba* against acute mercury.

Materials and Methods

Animal Care

male Wistar Albino rats approximately 3-5 months old ,weighing 180-250g were obtained from Collage of Science –Kufa university ,Iraq. The experimental animals were acclimatized to the laboratory conditions for 10 days prior to the initiation of experimental treatments. They were caged in a quite temperature-controlled room ($27\pm 1^{\circ}\text{C}$) and quarters under a 12-hour light-dark cycle. and had free access to water and standard diet.

Preparation of aqueous extract of *G. biloba*:

Fine quality of *G. biloba* leaves (al-Kawther herb in Hilla city -Babylon) were used for preparation 200 μg or 400 μg of an aqueous extract, 40 mg or 80 mg of *G. biloba* leaves were crushed, added to 100mL cold water And mixed in an electric mixture for 20 minutes. The mixture was centrifuged, and the clear supernatant was carefully removed and kept in a refrigerator at $2-8^{\circ}\text{C}$ as a final extract for subsequent experimental treatments.

Experimental design

Adult male albino rats weighing about 180-250 g were used for the study according scheme(1)

Scheme 1 : Experimental design

Groups	treatment
Group I (n=4)	Control animals
Group II (n=4)	animals treated intraperitoneal with plant extract only (200mg/kg bwt/day) for 25 days.
Group III (n=4)	animals treated intraperitoneal with plant extract only (400mg/kg bwt) for 25 days.
Group IV(n=4)	(stress control)Mercuric chloride given orally at dose 5mg/kg for 5 day .
Group V(n=4)	rats treated with Mercuric chloride orally at dose 5mg/kg for 5 day+ injected intraperitoneal with plant extract of GB (200mg/kg b.wt /day) for 25 days.
Group VI (n=4)	rats treated with Mercuric chloride orally at dose 5mg/kg for 5 day + injected intraperitoneal with plant extract of GB (400mg/kg b.wt/day) for 25 days

Doses and route of administration

Normal control group (I) received orally 0.5mL normal physiological saline for five days and intraperitoneally 1 mL normal physiological saline for 25days. groups (II and III) were treated of 1ml intraperitoneal with each concentration of extract for 25 days.,group (IV) treat orally 0.5 ml of Hg₂cl at dose 5mg/kg for 5 day,group(V&VI) recieved 0.5 ml with Mercuric chloride orally at dose 5mg/kg for 5 day + treated 1ml intraperitoneal with plant extract of GB (either 200 or 400mg/kg b.wt) for 25 days.

Blood collection and serum separation:

Blood samples were withdrawn from the heart of each animal, 24 h after the last treatment under anesthesia with diethyl ether according to the method of Cocchetto and Bjornsson (1983). Blood was allowed to clot, and then centrifuged at 3000 rpm for 15 min to separate serum, which kept at -20 °C till biochemical analysis.

Tissue Preparation

Immediately after blood sampling, animals were sacrificed and the liver and kidney of each animal were dissected out, a part of liver and kidney was fixed in 10% formalin and embedded in paraffin wax blocks. Sections of 5 μ m thick were stained with hematoxylin and eosin (H&E), then examined under light microscope for determination of pathological changes (Suzuki and Suzuki, 1998), and the other part was used for Malondialdehyde (MDA)& glutathione (GSH) assayed.

Antioxidant parameters

About 500 mg of liver, kidney was homogenized with ice -cold in 4 mL of buffer solution of phosphate buffered saline (w/v: 500 mg tissue with 4ml PBS, PH 7.4) homogenates were centrifuged at 10.000 xg for 15 min at 4°C and the resultant supernatant was used for determination of: Lipid Peroxidation (**LPO**): LPO as Malondialdehyde (MDA), Reduced Glutathione (GSH).

Malondialdehyde, as a product of polyunsaturated fatty acids oxidation was determined (Moron *et al*,1979)using thiobarbituric acid reactive substances (TBARS) were measured spectrophotometrically, after the reaction with thiobarbituric acid in acidic medium for 30 min with heating. To form chromogen complex reactive product, the absorbance of the resultant pink product can be measured at 532 nm and its concentration was calculated using

the extinction coefficient value $1.56 \times 10^5 \text{ M}^{-1} \text{ cm}^{-1}$ and results are expressed as nmol MDA/g tissue .

Glutathione was assayed using dithiobis-2-nitrobenzoic acid (DTNB) in PBS. The reaction color was read at 412 nm. (Moron *et al*,1979) (GSH levels were calculated using an extinction coefficient of $13600 \text{ M}^{-1} \text{ cm}^{-1}$. Results are expressed in μmol GSH/g tissue.

Serum Biochemical Parameters:

The activities of the alkaline phosphatase (ALP)], total protein , creatinine and uric acid were determined in serum using commercial kits from Bio Merieux, France.

Histopathological and histophotometry investigation

diameter of central vein of liver ,glomerulus diameter and collecting tubules diameter of kidney .all diameters measurement by using ocular lens.

The histopathological Evaluation of Kidneys. In order to compare the relationship between the presence of renal injury, all slides were read only for the presence or absence of nephrosis. For this study, nephrosis was defined as the presence of tubular epithelial degeneration and/or necrosis.

Individual cell necrosis was the criterion for identification of the earliest histopathologic change. The severity of nephrosis was recorded using a grading scale of 0 to 4 which was related to a subjective impression of the extent of cortical tubular involvement, as follows:

0 = indistinguishable from controls

1 = minimal, $\leq 25\%$ tubules affected

2 = mild, $. 25\% \geq 50\%$ tubules affected

3 = moderate, $. 50\% \geq 75\%$ tubules affected

4 = marked, $. 75\%$ tubules affected.

This grading scale was adapted from the NTP Technical Report (National Toxicology Program, 1993).

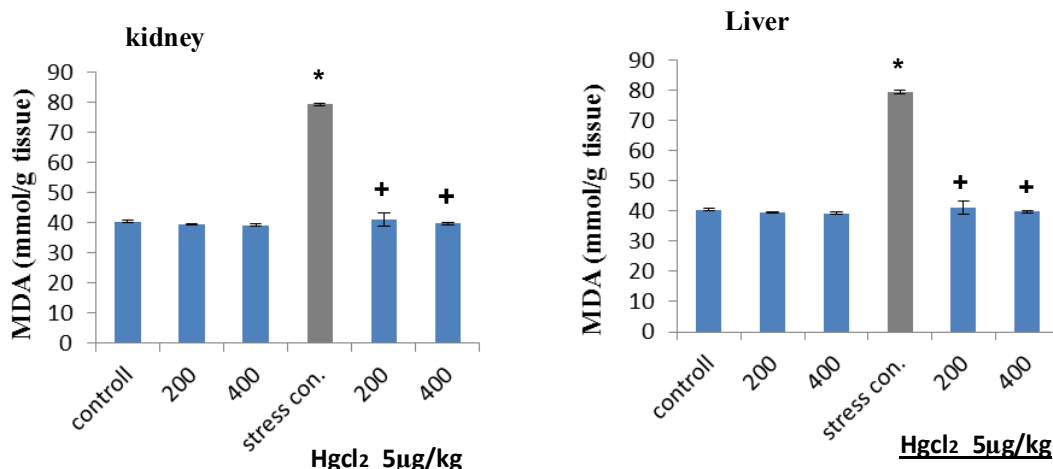
Statistical Analysis

Statistical Package for Social Sciences(SPSS) version 16 was used for statistical analysis of these data. Mean \pm standard error of the all parameter studying was calculated for each group. The groups were compared using ANOVA (Analysis of Variance) and post hoc tests were applied where necessary. Value of $P < 0.05$ was considered statistically significant.

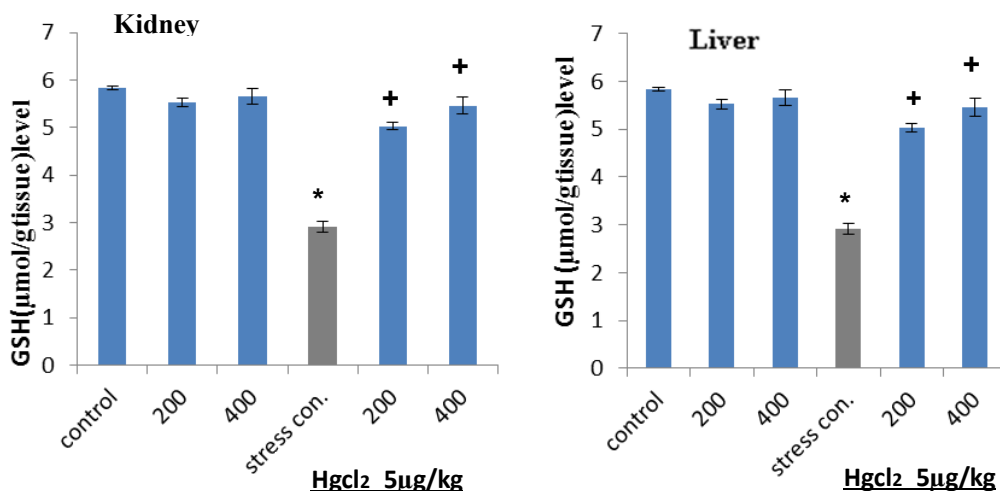
Results and Discussion

Effect of *G.biloba* on liver, kidney lipid peroxidation (LPO), and glutathione levels (GSH) in rats treated by mercuric chloride

Compared to the control group, LPO markedly increased in the Hg-treated rats as exhibited a significant increase ($P < 0.05$) in MDA level in liver and kidney tissue .whereas the groups *G.biloba*+ Hg- treated and *G.biloba*-treated rats (both concentration) expressed normal levels MDA in relation to the control rats, and decrease level of MDA in relationship to the group treat with Hgcl₂ (figure 1). Moreover, Figure (2) shows that GSH level in tissue significantly decreased ($P < 0.05$) in the Hg-treated rats Conversely,. no significant alterations in GSH levels in *G. biloba*+Hg and *G.biloba* -treated rats..



Figure(1)Changes in MDA(mmol/g tissue)level in treatment groups .values are M± S.E.,* P≤0.05 compared to control group, + P≤0.05 compared to stress con.



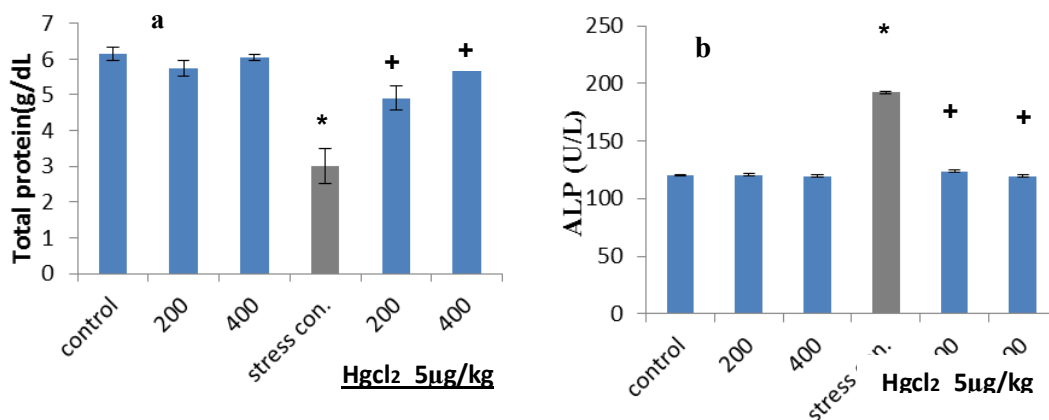
Figure(2)Changes in GSH(μmol/g tissue)level in treatment groups .values are M± S.E.,* P≤0.05 compared to control group, + P≤0.05 compared to stress con.

The inorganic mercury intoxication leads to structural and functional alterations in liver, kidney and other tissues (Radi and Farghaly, 2000), Because Mercury exposure induces lipid peroxidation detected by increasing thiobarbituric acid reactive substances (TBARS) in tissues of kidneys, liver and brain (Huang *et al* ,1996).also Mercuric ion, one of strongest thiol-binding agents and can cause biochemical damage to tissues through diverse mechanisms including enhancement of lipid peroxidation (LPO) and reduction of antioxidant enzymes (Rao and Chhunchha, 2009).The present study revealed that mercuric chloride intoxication causes a significant increase in lipid peroxidation within increase hepatic and renal MDA levels which are the major primary products LPO of polyunsaturated fatty acids and of free radical mediated . The observed increase in peroxide levels in rats treated with HgCl₂ may indicate oxidative stress which is harmful to cells and tissues liver and kidney (Linden *et al.*, 2008),these findings are also reported by(Sener *et al.*2007). also Our investigation demonstrates that the treatment of rats with HgCl₂ decreased hepatic and

nephritic GSH level significantly. The principal toxic effects of mercury involve interactions with a large number of cellular processes, including formation of complexes with free thiol teams, which may cause oxidative stress (Stacey and Kappus, 1982). Glutathione, as carrier of mercury and an antioxidant, has specific roles in protective the body from mercury toxicity. GSH binds with mercury, forms a complex that prevents mercury from binding to cellular proteins and inflicting injury to each enzyme and tissue (Kromidas, *et al.*, 1990). As a result of binding of mercury to glutathione and subsequent elimination of intracellular glutathione, levels of GSH are lowered in the cell and reduced the antioxidant potential of the cell. Agarwal *et al.* (2010a,2010b) additionally reported a significant reduction of GSH levels in liver, kidney and brain tissues. treatment the animals that offer mercury with *Ginkgo biloba* leaves extract attenuated the Hg-induced oxidative damage. Hence treatment with *G.biloba* significantly restored increased MDA and decreased GSH levels to the normal values This could be attributed to the excellent antioxidant properties of *G.biloba*, these results agreement with (senser *et al* ,2007). This property. seems to be due to its ability to scavenge free radicals. to get activity of *G. biloba* to existence The two main pharmacologically active groups of compounds present in the *Ginkgo* leaf extract are the flavonoids (quercitin and kaempferol) and the terpenoids (ginkgolides and bilobalide) (Smith and Luo 2004). There are two proposed mechanisms of action *G.biloba* are (1) directly scavenging free radicals and (2) indirectly inhibiting formation of free radicals. The Ginkgo leaf extract can scavenge reactive oxygen species (ROS) such as hydroxylradicals (OH[·]), peroxy radical (ROO[·]), superoxide anion radical (O₂^{-·}), nitric oxide radical (NO[·]), hydrogen peroxide (H₂O₂), and ferryl ion species (Mahaevan an Y. Park ,2008), *Ginkgo* leaf extract can also enhance activities of antioxidant enzymes such as superoxide dismutase (SOD), glutathione peroxidase, catalase, and/or heme-oxygenase-1, thereby indirectly contributing as an antioxidant (DeFeudis *et al* 2003; Song *et al* 2000). It has been suggested that ginkgo leaf extract increases expression of mitochondrial enzymes like NADH dehydrogenases, which might influence ROS generation within the mitochondria.

Effect of *G.biloba* on serum biochemical parameters in rats treated by mercuric chloride

Figure(3 a&b) shows that the Hg-treated and Hg + *G. biloba* treated(at concentration 200 mg/kg) rats displayed a significant increase ($P < 0.05$) in serum ALP enzyme activity, also significant reduction in the total protein level compared to the control. In spite of The changes were less in the Hg + *G. biloba* treated(200mg/kg) rats. furthermore significant decrease ($P \leq 0.05$) in serum ALP activity and significant increase ($P < 0.05$) in serum total protein in Hg + *G.biloba* (both concentration) compared to control stress (Hg) group.

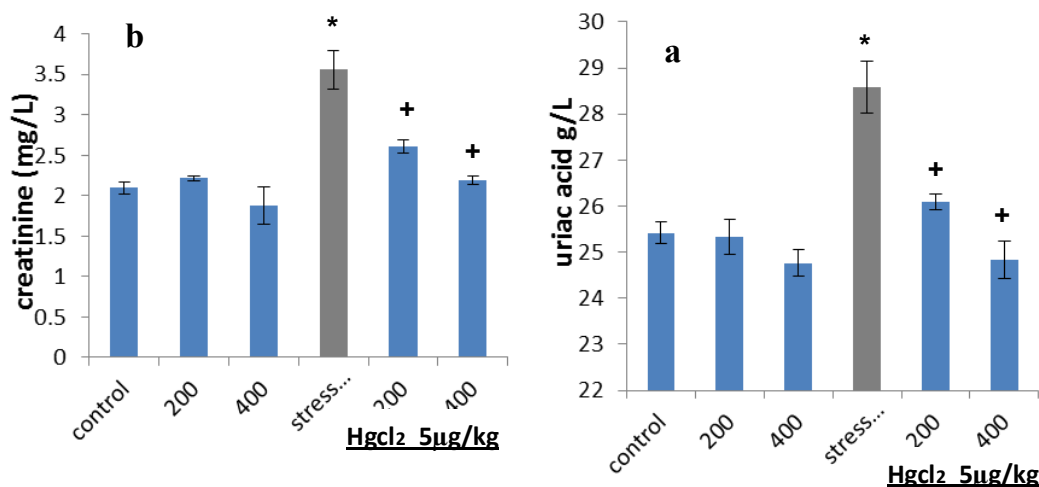


Figure(3) Changes in Total protein(g/dl) (a) and ALP (U/L) (b) level in treatment groups. values are M± S.E., * $P \leq 0.05$ compared to control group, + $P \leq 0.05$ compared to stress con.

,serum ALP activities have significant elevation when compared to control groups ,these result were consistent with those studies (Sankar *et al*,2009) elevated levels of serum ALP (liver marker enzyme) are indicative of cellular leakage and loss of functional integrity of cellular membrane in liver(Drotman and Lawhorn,1978) serum ALP level is related to the function of hepatic cell ,the increase in ALP serum is due to increase its synthesis in the presence of increased biliary pressure (Muriel *et al*,1992). There were significant restorations enzyme level after treatment with *G.biloba* .the reversal of increased serum ALP enzyme in Hgcl2 induced liver damage by the extract may be due to the prevention of the leakage of intracellular enzymes by its membrane stabilizing activity. Hepatoprotective activity may be due to presence of compounds in this extract with high antioxidant capacity are flavonoid and terpenoid .this agreement with (Cha'ves-morates *et al*,2010).

The liver is known to play a significant role in the serum protein synthesis, being the source of plasma albumin and fibrinogen and also the other important components like α and β -globulin. The reduction in the TP is attributed to the initial damage produced and localized in the endoplasmic reticulum which results in the loss of cytochrome P-450 enzymes leading to its functional failure with a decrease in protein synthesis . treatment with *G.biloba* enhanced the synthesis of TP which accelerates the regeneration process and the protection of liver cells that is clearly demonstrated in the present study. Therefore, the increased level of TP in serum indicates the hepatoprotective activity. Moreover, Zhang *et al.* (2004) reported that *G.biloba* has a protective effect on hepatic cell and the mechanisms may involve its inhibition on platelet-activating factor and lipid peroxidation.

Figure (4 a&b)displays that the Hg-treated and Hg + *G. biloba* treated(at concentration 200 mg/kg) There was a significant increase ($P < 0.05$) in creatinine serum levels and a significant increase ($P < 0.05$) in uriac acid serum levels compared to the control ,also significant reduction ($P < 0.05$) in serum creatinine ,uriac acid Hg + *G.biloba* (both concentration) compared to control stress (Hg) group. *G. biloba*-treated rats did not show any alterations in the biochemical parameters.



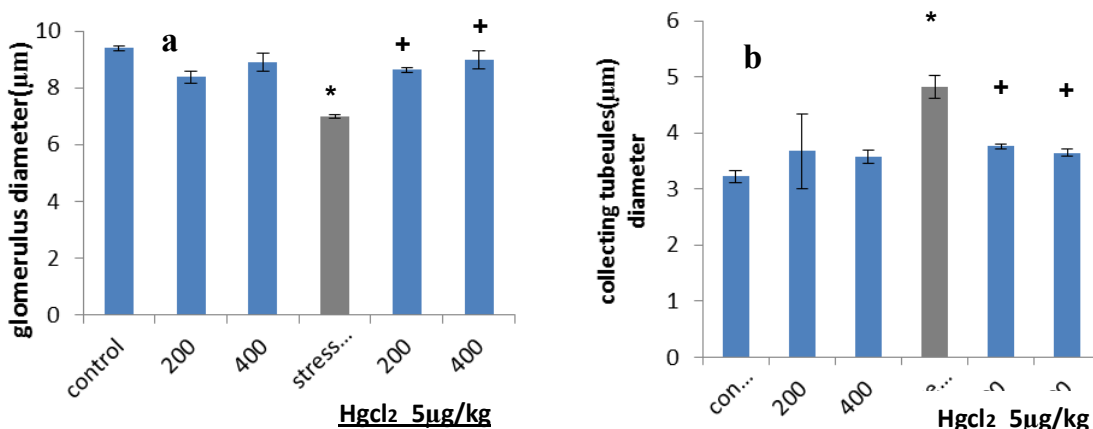
Figure(4)Changes in uriac acide(g/L) (a) and creatinine (mg/L) (b) level in treatment groups .values are M \pm S.E., * $P \leq 0.05$ compared to control group, + $P \leq 0.05$ compared to stress con.

The kidneys are the primary target organ for accumulation and toxicity of inorganic mercury , In fact as little as 1 hour, 50% of an administered dose of inorganic mercury is present in the kidney(Zalups,1993). Within the kidney, the majority of mercuric ions were detected in the cortex which is the primary site of accumulation of mercuric ions (Zalups,2000).our result demonstrate increase in serum creatinine and uric acid levels in

mercury- treated rats that indicate marked nephrotoxicity Studies in animals have established that tubular injury plays a central role in the reduction of glomerular filtration rate in acute tubular necrosis. Two major tubular abnormalities may well be involved in the decrease in glomerular function in mercuric chloride treated rats: Obstruction and back leak of glomerular Filtrate (Girardi and Elias, 1995). The alterations in glomerular function in mercuric chloride treated rats may also be secondary to ROS(reactive oxygen species), which induce mesangial cells contraction, altering the filtration surface area and modifying the ultrafiltration coefficient factors that decrease the glomerular filtration rat (Zalups, 2000; Stohs and Bagchi, 1995;). ,treatment with *G.biloba* protected against Hg-induced nephrotoxicity. This was manifested by decreased serum creatinine and uric acid levels and diminished the intensity of the renal lesions.

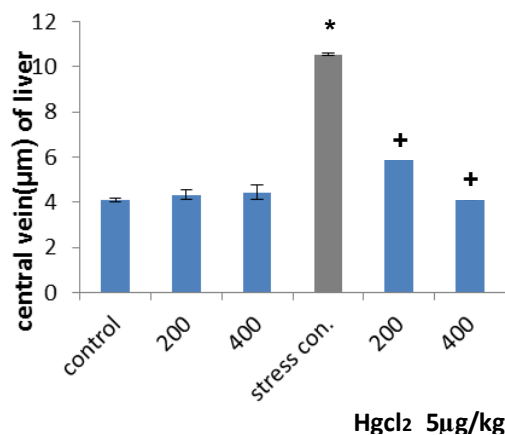
Effect of *G.biloba* on Renal - Hepato histophotometry investication in rats tissues treated by mercuric chloride

This study shows significant increase ($P<0.05$) in glomerulus and collecting tubules diameter of Hg – treat group and , whereas the groups *G.biloba*+Hg- treated and *G.biloba*-treated rats (both concentration) expressed normal values in relation to the control rats. Figure (5). also the present results showed significant increase ($P <0.05$) in central vein diameter of liver tissue of all Hg- treatment groups in spite of the increase is less in (Hg +*G. biloba* both concentration),Figure (6) show no significant alterations in *G.biloba* -treated rats..



Figure(5)Changes in glomerulus(a) and collecting tubules diameter (µm)(b) of kidney tissue in treatment groups .values are M± S.E.,* $P\leq 0.05$ compared to control group, + $P<0.05$ compared to stress con.

Figure(6)Changes in central vein(µm)diameter of liver tissue in treatment groups .values are M± S.E.,* $P\leq 0.05$ compared to control group, + $P\leq 0.05$ compared to stress con.



Effect of *G.biloba* on Renal - Hepato histopathology investigation in rats tissue treated by mercuric chloride :

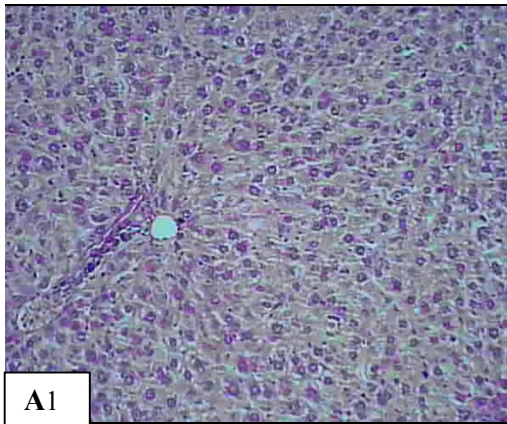
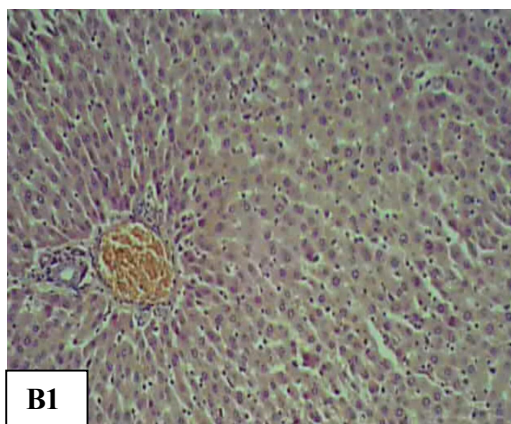
Microscopically, liver from control rat group showed the normal histological structure of hepatic lobule and portal vein Fig. (A1) Liver tissues in Hgcl2 intoxicated rats showed vacuolation in some hepatocytes, congestion within central veins and some sinusoids Fig.(B1&C1). focal area of hepatic necrosis associated with mononuclear cells infiltration and ballooned and degeneration hepatocytes and pyknosis of their nuclei Fig. (D1). Liver tissues of rats group received *G.biloba* (E1&F1) and recovery groups(treatment of rats withHgcl2+ *G.biloba*) showed apparent normal histological structur and apparent normal parenchyma cells, Figs. (G1&H1).

On the other hand Histopathological changes in the kidneys of all groups were graded according to a histopathological scoring index and the results were scored as described in the Materials and Methods section. nephrotic changes are summarized in Table(1), There were no obvious renal histological alterations in the control group (histopathological scoring index) mercury treatment caused proximal tubular necrosis in all group treatment ,in animal which received plant extract one animale grade 1 , mercury +*G.biloba* administration improved the histopathological disorders but not completely prevent them and resulted in decreased histological damage

Control group show normal histological structure of kidney(A2). kidney from stress group illustrated congestion of glomerular tufts, hemorrhage in the interstitial tissue ,vacuolization of epithelial lining renal tubules Figs. (B2 &C2) Treatment of *G.biloba* alon exhibited apparent normal renal parenchyma and no histopathological changes. Fig. (D2&E2) also Kidney tissue of the groups *G.biloba*+Hg- treated showed apparent normal histological structur and apparent normal parenchyma cells, Figs. (F2&G2).

TABLE(1)
Histopathological scoring obtained from light microscopic analysis
of kidney sections of all treatment groups.

	0	1	2	3	4
Group (I) n=4	4	0	0	0	0
Group (II) n=4	0	0	0	0	4
Group (III) n=4	4	0	0	0	0
Group (IV) n=4	3	1	0	0	0
Group (V) n=4	2	2	0	0	0
Group (VI) n=4	3	1	0	0	0



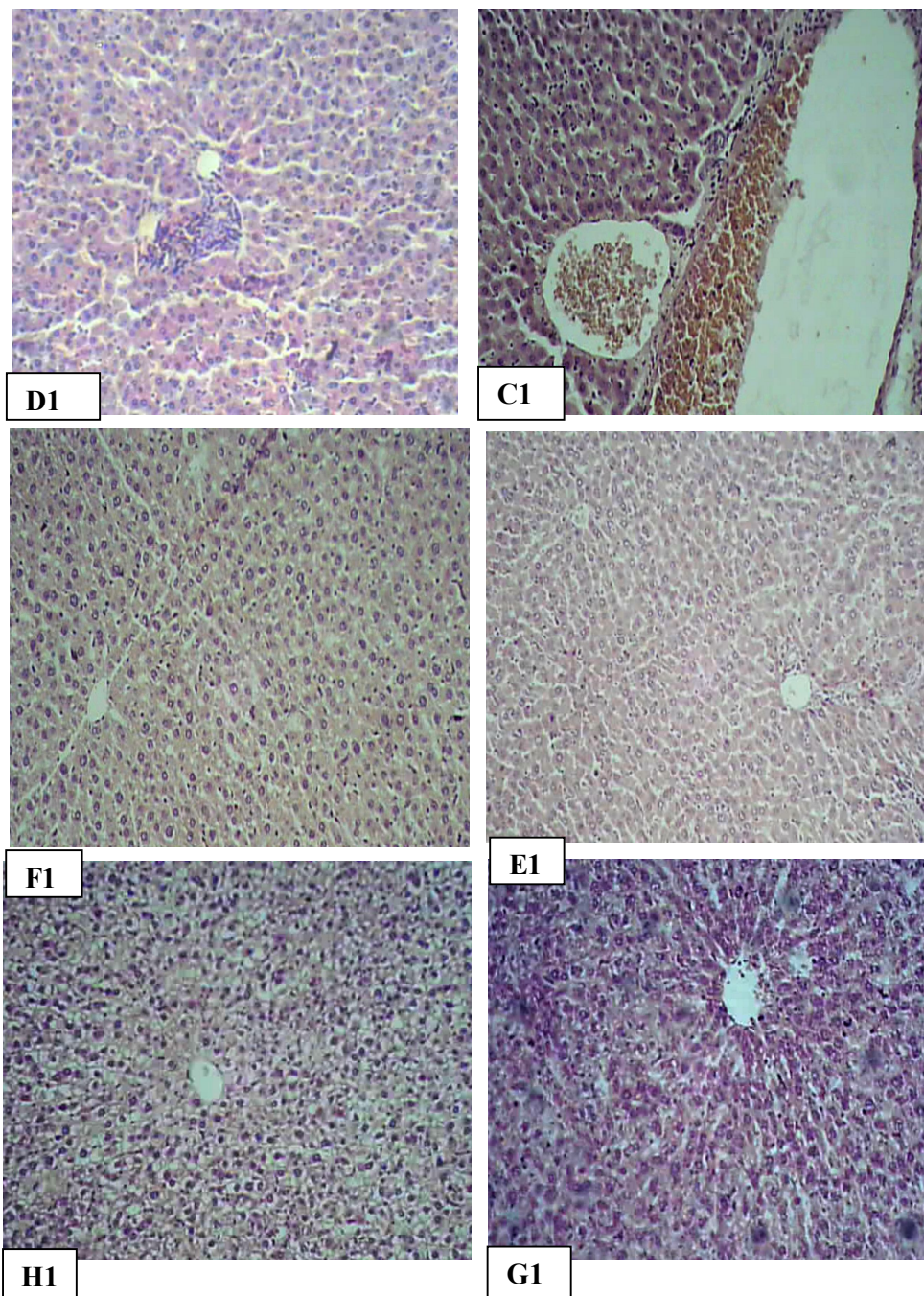


Figure (1) Photomicrograph of liver stained with H.E. (200X): (A) Normal hepatic histoarchitecture, (B ,C &D) Mercury-treated rats show congestion within central veins and some sinusoids and mononuclear cells infiltration . (E &F) are group received *G.biloba* . (H &G) are recovery group ..in image (E,F,G&H)no histopathological changes.

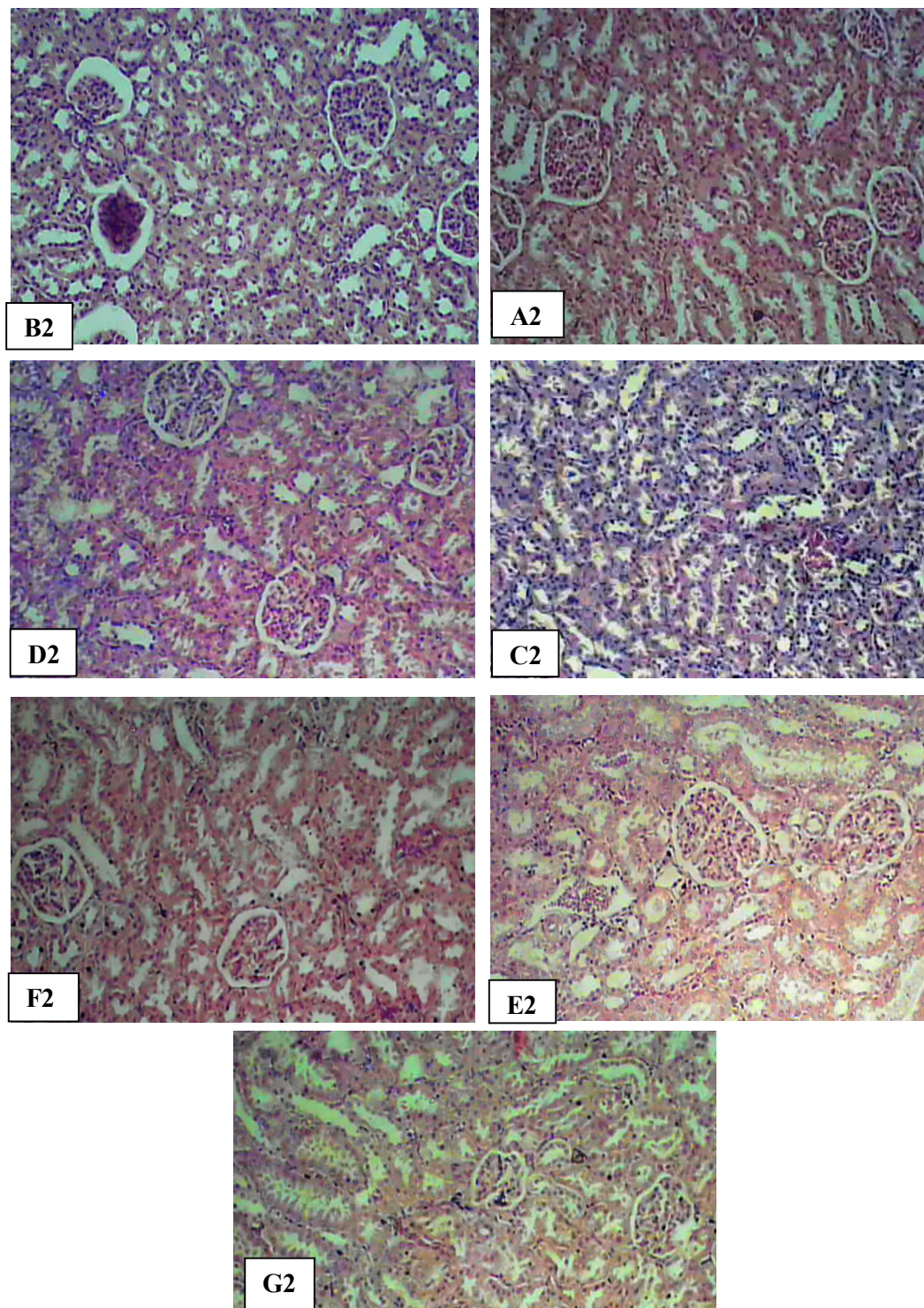


Figure (2) Photomicrograph of kidney stained with H.E. (200X): (A) Normal renal histology structure, (B &C) Mercury-treated rats show congestion of glomerular tufts, hemorrhage in the interstitial tissue ,vacuolization of epithelial lining renal tubules. (D &E) are group received *G.biloba* . (F &G) are recovery group; in image (D,E,F&H)no histopathological changes

Histological results were in agreement with the measured activities of serum liver enzymes and provided supportive evidence for the biochemical analysis, in the current study, histopathological examination of the liver tissues showed congestion in portal vein with infiltration of mononuclear inflammatory cells, necrosis, vacuolar degeneration and kupffer cells activation and increase in central vein diameter in mercury group. These finding relates with high activities of serum liver enzyme activities found in the Hgcl₂ group (Gupta *et al.* 2011). Liver sections of rats treated with Hgcl₂+ *G.biloba* showed regeneration of normal liver architecture. This may be explained by the constituents of *G.biloba* are scavengers of free radicals, and inhibit lipid peroxidation and protects cells and tissues against oxidative stress induced by free radicals.

Also Our histopathological findings in the kidney tissue of Hg-treated rats revealed severe diffuse acute necrosis of tubular epithelium, shedding of tubular epithelium lumina of the renal tubules ,decrease in glomerulurs and collected tubules diameter and interstitial edema as result of tubular leakage. The interaction of mercury with protein sulfhydryl groups is thought to play an important role in nephrotoxicity induced by mercury at cellular analysis level (Zalups,2000). These results agree with Naidu *et al.* (2000) which investigated the effect of 300 mg Ginko biloba extract/kg on gentamicin-induced nephrotoxicity in male Wister rats .also Fukaya& Kanno (1999). investigated *Ginko biloba* extract significantly improved the urea level and the pathological scoring, Changes in mitochondrial morphology and function are very early event which follow mercuric chloride administration, which suggests that mitochondrial dysfunction and oxidative stress have an important role in mercury induced renal toxicity. Our findings were similar to those reported by (Al-Saleh *et al.*,(2005) Alam *et al.*(2007)., Sharma *et al.*(2007), Augusti *et al.*(2008). and Agarwal *et al.* (2010a,2010b) These results were supported by enhanced serum creatinine and uric acid levels in mercury- treated rats that indicate marked nephrotoxicity ,treatment with *G.biloba* protected against Hg-induced nephrotoxicity. This was manifested by decreased serum creatinine and uric acid levels and diminished the intensity of the renal lesions.

However, the rats treated with ginkgo showed a significant protective effect for the liver and kidneys against the negative effects of mercury. This shielding effect also increased with the greater quantity of used. "Gingko biloba" .

In conclusion, the present results demonstrated that *G.biloba* was effective in the prevention of mercury induced acute toxic effects in rat liver & kidney , which were proven by biological evaluation, biochemical analysis, and further supported by the histological examinations in the liver ,kidney tissues. This nephro- hepatoprotective activity is both preventive and curative. As a possible mechanism an aqueous extract of *G. biloba* leaf consists of many chemical constituents which could scavenge oxidative free radicals, inhibit lipid peroxidation, possess antioxidant activity and then alleviate acute toxicity. This absence of toxicity of *G.biloba* should be taken into account if safety measures for public health are to be implemented in response to increased ingestion of this herbal by human populations, given that *G.biloba* has been clinically prescribed for the treatment of various diseases. Further studies are required to isolate the active constituents in aqueous extract responsible for nephro- hepatoprotective activity and developing new drugs to treat drug/chemical-induced toxicity.

Reference:

- Agarwal, A.; Goel, S.; Chandra, R. and Beharia, J. 2010b : Role of vitamin E in preventing acute mercury toxicity in rat. *Environmental Toxicology and Pharmacology*, 29: 70-78..
- Agarwal, A.; Goel,S. and Beharia, J. 2010a: . Detoxification and antioxidant effects of curcumin in rats experimentally exposed to mercury. *Journal of Applied Toxicology*, 30: 457-468.
- Alam, M.S.; G. Kaur, Z; Jabbar,; Javed , K. and. Athar, M. 2007: Eruca sativa seeds possess antioxidant activity and exert a protective effect on mercuric chloride induced renal toxicity. *Food and Chemical Toxicology*, 45: 910-920.
- Al-Othman, Z.A.; Inamuddin, Naushad M.U. 2011: Determination of ionexchange kinetic parameters for the poly-o-methoxyaniline Zr(IV) molybdate composite cation-exchanger, *Chem. Eng. J.*, 166: 639- 645.
- Al-Saleh, I.; I. El-Doush; N. Shinwari and R. Al- Baradei, 2005. Does low mercury containing skin lightening cream (Fair and Lovely) affect the kidney, liver and brain of female mice? *Cutaneous and Ocular, Toxicology*, 24: 11-29.
- Augusti, P.R.; Conterato, G.M.M. ; Somacal, S.; Sobieski, R. ; Spohr, P.R.; Torres, J.V. ; Charao, M.F. ; Moro, A.M. ; Rocha, M.P. ; Garcia, S.C. and Emanuelli, T.(2008):. Effect of astaxanthin on kidney function impairment and oxidative stress induced by mercuric chloride in rats. *Food and Chemical Toxicology*, 46: 212-219.
- Bystrianyk ,R.(2010):Ginkgo protect the liver and kidney from uranium .*Journal of Medicinal Food* ,179-188.
- Cha´vez-Morales, R.M.; Jaramillo-Jua´rez, F.; Posadas del Ri´o, F.A.; Reyes-Romero, M.A.; Rodri´guez-Va´zquez, M.L. and Marti´nez- Saldan˜a M.C. (2010): Protective effect of *Ginkgo biloba* extract on liver damage by a single dose of CCl4 in male rats. *Human and Experimental Toxicology*, 30 (3): 209-216.
- Chan, P.; Xia, Q. and. Fu,P.P. (2007) : *Ginkgo Biloba* Leave Extract: Biological, Medicinal, and Toxicological Effects *Journal of Environmental Science and Health Part C*, 25:211–244, 2007 211-244
- Cocchetto, D.M. and Bjornsson, T.D. (1983): Methods for vascular access and collection of body fluids from the laboratory rat. *J. Pharm. Sci.*, 72 (5): 465- 492.
- DeFeudis, F.V.; Papadopoulos, V. and Drieu, K. (2003): *Ginkgo biloba* extracts and cancer: a research area in its infancy. *Fundam Clin Pharmacol* 17:405–17.
- Drotman, R.B. and Lawhorn, G.T. (1978): Serum enzymes are indicators of chemically induced liver damage. *Drug Chem. Toxicol.*,1(2):163-171.
- Emanuelli, T.; Rocha, J.B.and Pereira M.E.,(1996):. Effect of mercuric chloride intoxication and dimercaprol treatment on delta-aminolevulinatase from brain, liver and kidney of adult mice. *Pharmacol Toxicol.*;79(3):136–143.
- Foulkes, E.C. (1990):Biological effects of heavy metal. In: *Metal carcinogen*, vol II. CRC Press, Florida, USA.
- Fukaya, H. & Kanno, H.(1999): Experimental studies of the protectiveeffect of ginkgo biloba extract (Ginko biloba extract) on cisplatin-induced toxicity in rats. *Nippon Jibiinkoka Gakkai Kaiho.*, 102, 907–917.
- Girardi, G. and Elias, M.M. (1995): Mercuric chloride effects on rat renal redox enzymes activities: SOD protection. *Free Radical Biol. Med.*, 18: 61-66.
- Gupta, R.K.; Hussain, T.; Panigrahi , G.; Das, A.; Singh, G.N.; Sweety, K. ; Faiyazuddin, M. and Rao, C.V. (2011): Hepatoprotective effect of *Solanum xanthocarpum* fruit extract against CCl4 induced acute liver toxicity in experimental animals. *Asian Pac. J. Trop. Med.*, 4(12):964-968.

- Huang ,C.H.; Yang,M.L.; Tsai,C.H.; Li,Y.C.; Yi-Jung Lin,Y.J. and Kuan ,Y.C. (2013) : Ginkgo biloba leaves extract (EGb 761) attenuates lipopolysaccharide-induced acute lung injury via inhibition of oxidative stress and NF- κ B-dependent matrix metalloproteinase-9 pathway *Phytomedicine* 20 : 303– 309.
- Huang, Y.L.; Cheng, S.L.and Lin T.H.(1996): Lipid peroxidation in rats administrated with mercuric chloride. *Biol Trace Elem Res.*;52(2):193–206.
- Kromidas, L.; Trombetta, L.D. and Jamall, I.S. (1990): The protective effects of glutathione against methylmercury cytotoxicity. *Toxicology Letters*, 51: 67-80.
- Kumar, S.V.; Sanjeev, T. and Ajay, S.A.(2012): Review on hepatoprotectiveactivity of medicinal plant. *IJARPB*; 1: 31-38.
- Linden, A.; Gulden, M.; Martin, H.J.; Maser, E. and Sibert, H. (2008). Peroxideinduced cell death and lipid peroxidation in glioma cells. *Toxicol. Vitro.*, 22: 1371-1375.
- Lu, F.C.(1996): Basic toxicology, fundamentals target organs and risk assessment. 3rd ed. Taylor and Fracis Pub. London.
- Lundh, H.A.B. (1964): Sequence comparison between kidney and liverlesions in the rat following carbon tetrachloride poisoning. *J Occup Med*; 6: 123-128.
- Mahadevan , S. and Park, Y. (2008) : “Multifaceted Therapeutic Benefits of *Ginkgo biloba* L.: Chemistry Efficacy, Safety and Uses,” *Journal of Food Science*, Vol. 73, No. 1, 2008, pp. 14-19.
- Mohamed ,N. Z. ; Abd-Alla,H. I.; Aly, H. F. 1; Mantawy,M.; Ibrahim,N.and Sohair ,A.(2014): CCl₄-induced hepato-nephrotoxicity: protective effect of nutraceuticals on inflammatory factors and antioxidative status in rat. *Hassan1 Journal of Applied Pharmaceutical Science* Vol. 4 (02), pp. 087-100.
- Moron,M.S.;epirre,J.W.and Mannervik,B.(1979):Levels of Glutathion reductase and glutathione S-transferase activities in rat lung and liver; *Biochemical et Biophysical Acta*; 582:67-78.
- Mroueh, M; Saab, Y. and Rizkallah, R. (2004): Hepatoprotective activity of *Centaurium erythraea* on acetaminophen-induced hepato-toxicity in rats. *Phytother. Res.*, 18(5): 431- 433.
- Muriel, P.; Garciapina, T.; Perez-Alvarez, V. and Mourelle, M. (1992): Silymarin protects against paracetamol-induced lipid peroxidation and liver damage. *J. Appl. Toxicol.*, 12(6):439-442.
- Nabi, S.A.; Bushra, R.; Naushad, M.U.; Khan, A.M. (2010): Synthesis, characterization and analytical applications of a new compositecation exchange material poly-o-toluidine stannic molybdate for theseparation of toxic metal ions, *Chemical Eng. J.*, 165: 529-536.
- Naidu, M. U.; Shifow A. A.; Kumar, K. V. & Ratnakar, K. S.(2000) : Ginkgo biloba extract ameliorates gentamicin-induced nephrotoxicity in rats. *Phytomedicine*, 7, 191–197.
- National Toxicology Program (1993):. Toxicology and carcinogenesis studies of mercuric chloride in F344 rats and B6C3F1 mice. Technical Report No. 408, pp. 36–65. U.S. Dept. of Hlth. Human Services, Natl. Inst. Hlth., Res. Tri. Pk., NC.
- Necib,Y.; Bahi,A ; Zerizer,S.; Abdennour,C. and Salah Boulakoud .M.(2013): Effect of virgin oil (*Olea europea*)on kidney function impairment and oxidative stress induced by mercuric chloride in rats .*American Journal of Biochemistry and Biotechnology* 9 (4): 415-422.
- Radi, S.H. and Farghaly, E.F. (2000). Toxic effect of mercuric chloride on testis of rat and the detotoxifying rate of verapmil. The Egyptian society of histology and cytology. 23rd scientific conference p.64.
- Rao, M.V. and Chhunchha, B. (2009): Protective role of melatonin against mercury induced oxidative stress in the rat thyroid. *Food. Chem. Toxicol.* In Press.

- Richer, J.F. and Amler, S.N. (2005): Mercury exposure: evaluation and intervention, the inappropriate use of chelating agents in diagnosis and treatment of putative mercury poisoning. *Neurotoxicology* 26: 691-699.
- Sankar, S.; Elangomathavan, R.; Ramesh, S. and Jagadeesan, G. (2009): Effect of taurine and glutathione on mercury toxicity in liver tissue of rats. *Recent Research in Science and Technology*, 1: 243-249.
- Sener, G.; Sehirli, O. A.; Tozan, A.; Velioglu-ovuç and N. Gedik, (2007) :. *Ginkgo biloba* extract protects against mercury(II)-induced oxidative tissue damage in rats. *Food Chemical Toxicol.*, 45: 543-550.
- Sharma, M.K.; Sharma, A.; Kumar, A. and Kumar, M. (2007): Evaluation of protective efficacy of *Spirulina fusiformis* against mercury induced nephrotoxicity in Swiss albino mice. *Food and Chemical Toxicology*, 45: 879-887.
- Singh, A.; Mishra, S.P. and Mishra, A. (2014): Effect of *Ginkgo biloba* on Renal Ischemia-Reperfusion Induced Oxidant Stress in Rats. *Research and Reviews: journal of pharmacology and toxicology studies* ;2(1).
- Smith, J.V. and Luo, Y. (2004):. Studies on molecular mechanisms of *Ginkgo biloba* extract. *Appl Microbiol Biotechnol* 64:465-72.
- Song, W. ;Guan, H.J.; Zhu, X.Z.; Chen, Z.L.; Yin, M.L. and Cheng, X.F. (2000). Protective effect of bilobalide against nitric oxide-induced neurotoxicity in PC12 cells. *Acta Pharmacol Sin* 21:415-20.
- Stacey, N.H. and Kappus, H. (1982): Cellular toxicity and lipid peroxidation in response to mercury. *Toxicol. Appl. Pharmacol.*, 63: 29-35.
- Stohs, S.J. and Bagchi, D. (1995): Oxidative mechanisms in the toxicity of metal ions. *Free Radical Biol. Med.*, 18: 321-336.
- Suzuki, H. and Suzuki, K. (1998): Rat hypoplastic kidney (*hpk/hpk*) induces renal anemia, hyperparathyroidism, and osteodystrophy at the end stage of renal failure. *J Vet Med Sci*; 60: 1051-1058.
- Suzuki, R.; H. Kohno, S.; Sugie, K.; Sasaki, T.; Yoshimura, K.; Wada, T. and Tanaka. (2004): Preventive effects of extract of leaves of ginkgo (*Ginkgo biloba*) and its component bilobalide on azoxymethane induced colonic aberrant crypt foci in rats. *Cancer Lett.* 210: 159-169.
- Tanaka-Kagawa, T.; Suzuki, M.; Naganuma, A.; Yamanaka, N. and Imura, N. (1998): Strain difference in sensitivity of mice to renal toxicity of inorganic mercury. *J Pharmacol Exp Ther.*; 285(1):335-341.
- Xu, M.S.; Wang, Z.Y. and Kang YH. (2004): Recent advance on the chemistry and bioactivity of genus *Rumex*. *Chin Arch Tradit Chin Med*; 22: 417-420.
- Yee, S. and Choi B.H. (1996): Oxidative stress in neurotoxic effects of methylmercury poisoning. *Neurotoxicology*; 17:17-26.
- Zalups, R.K., (1993):. Early aspects of the intrarenal distribution of mercury after the intravenous administration of mercuric chloride. *Toxicology*, 18: 61-66. 79: 215-228.
- Zalups, R.K. (2000): Molecular interactions with mercury in the kidney. *Pharmacol. Rev.*, 52: 113-143.
- Zhang, C.; Zu, J.; Shi, H.; Liu, J.; Qin, C. (2004): The effect of *Ginkgo biloba* extract (EG b 761) on hepatic sinusoidal endothelial cells and hepatic microcirculation in CCl₄ rats. *Am J Chin Med*; 32: 21-31.