

Ministry of Higher Education and Scientific Research

Babylon University

College of Pharmacy



## Novel Approach In The Diagnosis And Treatment Of Behcet Disease

Graduation report Submitted by the students;

Sulaf jasim

Zainab hasan

Supervised by

Dr. **ANMAR ALAZAM**

بِسْمِ اللَّهِ الرَّحْمَنِ الرَّحِيمِ

(قَالَ اللَّهُ سَبَّحْتَ بِحَمْدِي لِلَّذِينَ لَا يَعْلَمُونَ عِلْمِي عَزَّ وَعَجَبٌ إِنَّ اللَّهَ فَاعِلُ الْعَمَلِ أَكْبَرُ مَا تُدْرِكُهُ الْأَبْصَارُ وَلَا يُحِيطُ بِشَيْءٍ مِّنْ عِلْمِهِ إِلَّا بِمَا شَاءَ وَسِعَ كُرْسِيُّهُ السَّمَاوَاتِ وَالْأَرْضَ وَلَا يَئُودُهُ حِفْظُهُمَا وَهُوَ الْعَلِيُّ الْعَظِيمُ)

بِسْمِ اللَّهِ الرَّحْمَنِ الرَّحِيمِ

لِلنُّورِ الْبَقَرَةِ الْآيَةُ (٣٢)



# إهداء

❁ إلى شمس الحقيقة والمرتبجي لإزالة الجور والعدوان إلى بقية الله في أرضه الامام

الهادي المهدي (عج) .

❁ إلى شهداء العراق .

❁ إلى والدتي العزيزة التي علمتني الحرص علي الصلاة عرفانا بفضلها وحنانها .

❁ إلى والدي الذي حرص علي تعليمي وتعب من أجلتي .

❁ إلى كل افراد أسرتي .

❁ إلى كل من كان عون في إخراج هذا البحث .

أهدي لهم هذا البحث الذي أسأل الله أن يجعلها في ميزان حسناتهم

# شكر وتقدير

أقدم بجزيل الشكر والامتنان العظيم والتقدير العميق الى الأستاذ المشرف الدكتور

(عمار عبد الكريم) لما منحه لي من جهد ووقت وتوجيه وإرشاد.

## List of Contents

Title	Page
Abstract	1
Introduction	2
Epidemiology	3
Pathogenesis	4
Symptoms	5
Diagnosis	7
Conclusion	10
Treatment	11
References	18

## **Abstract:**

---

Behcet's disease (BD) is a multigenetic inflammatory systemic disorder of unknown etiology. Clinical features include oral and genital ulcers, ocular inflammation, skin lesions, as well as articular, vascular, neurological, pulmonary, gastrointestinal, renal, vascular and genitourinary manifestations.

The main histopathological finding is a widespread vasculitis of the arteries and veins of any size. The cause of this disease is presumed to be multifactorial involving infectious triggers, genetic predisposition and dysregulation of the immune system. Treatment of Behcet disease continues to be based largely on case reports, case series, and a few randomized clinical trials.

## **Introduction:**

---

Behcet disease is a chronic inflammatory systemic disorder, characterized by a Relapsing and remitting course. It manifests with oral and genital ulcerations, skin lesions, uveitis, and vascular, central nervous system and gastrointestinal involvement.

The main histopathological finding is a widespread vasculitis of the arteries and veins of any size. The disease may start with one or more of the above symptoms but other symptoms may gradually appear over the years [Arayssi and Hamdan, 2004].

Outside the eye, its course is characterized by recurrent self-limiting episodes of acute inflammation that can lead to significant disability [Sakane et al. 1999].

The disease burden of BD is confined to the early years (around 15 years) of its course, and in many patients the syndrome burns out over the years [Kural-Seyahi et al. 2003].

Major vessel disease and central nervous system (CNS) involvement account for most of the deaths seen in this condition and can rarely appear for the first time relatively late in the course of the disease [Kural- Seyahi et al. 2003].

As in most complex diseases, both genetic and environmental factors are implicated in the pathogenesis of BD. HLA-B51 is by far the strongest associated genetic factor reported in patients with BD compared with controls [Remmers et al. 2010; Meguro et al. 2010; de Menthon et al. 2009].



In addition to HLA-B51, several susceptibility genes within and outside the major histocompatibility complex have been described and are thought to play a role in this complex disease. These include HLA-A26, PSORS1C1 [Hughes et al. 2013], HLA-Cw1602 [Hughes et al. 2013], GIMAP [Lee et al. 2013], UBAC2 [Sawalha et al. 2011], IL10 and IL23-IL12RB2 [Remmers et al. 2010; Mizuki et al. 2010], CCR1/CCR3 [Hou et al. 2012], MEFV and TLR4 [Kirino et al. 2013].

As the clinical expression of Behcet disease is heterogeneous, pharmacological therapy is variable and depends largely on the severity of the disease and organ involvement. Treatment of Behcet disease continues to be based largely on anecdotal case reports, case series, and a few randomized clinical trials.

The main goal of therapy in patients with BD is to induce and maintain remission and improve patients' quality of life. Selecting treatment is based on the organ involved and the assessment of the severity of the disease. The choice of therapy, however, is limited by the scarceness of high-quality therapy trials and is based largely on case reports, case series and several randomized clinical trials.

Over the last decade, a considerable amount of literature has been published regarding the use of tumor necrosis factor (TNF) inhibitors in BD. Beneficial effects have been noted with infliximab, etanercept, and adalimumab. Although there are no controlled trials, the existing evidence suggests efficacy of infliximab in treating patients with BD with refractory uveoretinitis, entero-Behcet, neuro-Behcet, vascular BD and arthritis.

None of the long-term prospective studies compared treatment with infliximab with any other treatment. However, two retrospective studies compared infliximab with cyclosporine in patients with refractory uveoretinitis [Tabbara and Al-Hemidan, 2008; Yamada et al. 2010]. Both studies found infliximab to be safe and more effective in reducing the number of uveitis flares.

### **Epidemiology:**

Behcet disease (BD) noted to be more severe, along the ancient Silk Road, which extends from eastern Asia to the Mediterranean. The country of Turkey is the most common location (80-370 cases per 100,000), but Japan, Korea, China, Iran, Iraq, and Saudi Arabia have prevalence ranges from 13.5-35/100,000. In North America and Northern European countries, by comparison, the prevalence is found to be between

1/15,000 to 1/500,000. In the areas where BD is more common the prevalence in men and women is similar, but in North America and Northern Europe women more commonly found to be affected. Young adults in their second and fourth decades (20-40yo) are typically affected and the disease is infrequently seen in children .The severity of the disease is greatest in young, male, and Middle Eastern or Far Eastern patients. {Abu El-Asrar, A., Abboud, E., Aldibhi, H. and Al-Arfaj, A.(2005)}.

### **Pathogenesis:**

Behcet's disease has been described as both an autoimmune and an autoinflammatory disorder. Autoinflammatory diseases refer to inherited disorders characterized by episodes of recurrent inflammatory reactions of the innate immune system without remarkable provocation, especially by neutrophils; whereas autoimmune diseases present with significant levels of high-titer autoantibodies or antigen-specific T-cells. Infectious agents are suggested as triggering the inflammatory reaction mediated by the innate immune system and "bacterial persistence "is required to sustain the inflammatory reaction mediated by the adaptive immune system.

Autoimmune or autoinflammatory reactions in Behçet's disease are suggested to target primarily blood vessels, especially endothelial cells, causing the clinical presentation of vasculitis and/or thrombosis symptoms. Lee, et al. identified  $\alpha$ -enolase as a target antigen of anti-endothelial cell antibodies (AECA) in patients with Behçet's disease using proteomic techniques.

Several mechanisms were proposed in order to explain the action of AECAs in the pathophysiology of inflammatory diseases, including the binding of AECA to endothelial cells resulting in cell activation, which may in turn increase secretions of chemoattractants and/or cytokines. AECAs might also trigger inflammatory processes by antibody-dependent cellular toxicity. {Arayssi,etal.(2004)}.

The alpha-enolase protein is the target protein of serum AECA in BD patients. This is the first report of the presence of antibodies to alpha-enolase in endothelial cells from the serum of BD patients. Although further studies relating this protein to the pathogenesis of BD will be necessary, alpha-enolase and its antibody may prove useful in the development of new diagnostic and treatment modalities in BD. {Lee KH, etal.(2003)}.



Patients with Behcet's disease have significantly higher levels of *S. sanguis* in their oral flora than do healthy controls or patients with other disease. *S. sanguis* are important extrinsic factors in the pathogenesis of Behcet's disease. Sera from patients with Behcet's disease, which react with recombinant human  $\alpha$ -enolase, were revealed by proteomic techniques to cross-react with streptococcal  $\alpha$ -enolase. {Lee J, et al. (2005)}. Endothelial cells stimulated with cultured *S. sanguis* and incubated for 6, 12 or 24h then harvested and the membrane and cytoplasmic fractions of proteins were extracted. *S. sanguis* stimulated the expression of enolase protein in the membrane of endothelial cells of the patient.

Since the 1980s, in situ hybridization, blotting, and polymerase chain reaction has also been applied to identify the herpes simplex virus DNA and RNA in patients. HSV type 1 can be detected in saliva, intestinal ulcers, and genital ulcers by polymerase chain reaction in patients with Behcet's disease compared with healthy controls. {Sohn S, et al. (1998)}.

### **Symptoms:**

Symptoms of Behcet's disease can vary from mild to very severe. Symptoms tend to appear, heal, and then recur frequently over months or years. The most common symptoms of the disease are:

#### **❖ Oral sores**

- Affect almost all people with the disease
- Usually are the first to appear
- Usually last for 10 to 14 days
- Can be painful
- Can cause scarring

#### **❖ Genital sores**

- In men: appear on the penis and/or scrotum
- In women: appear on the vulva or within the vagina
- Can be painful
- Can cause scarring

#### **❖ Uveitis**

- inflammation of the middle part of the eye, including the iris
- Tends to cause eye redness, blurred vision, sensitivity to light, and watering eyes

- If not treated, can cause partial vision loss or blindness

#### ❖ Arthritis

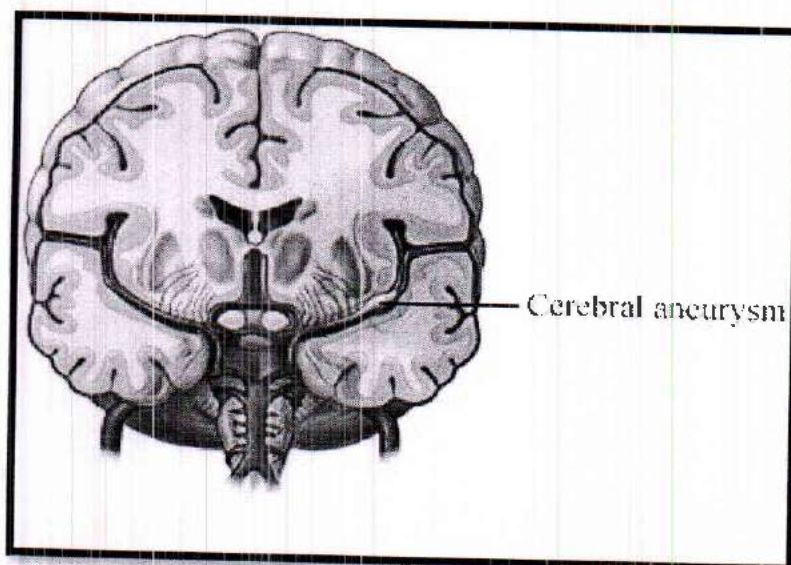
- inflammation of joints
- Tends to be painful
- Usually does not cause permanent joint damage

#### Skin problems, such as sores

- May appear as red, raised sores or bumps, or may be flat (flush with the skin)
- Usually appear on the legs and upper torso.

#### Other symptoms of the disease may include:

- Severe fatigue during a flare
- Blood clots
  - 1- Caused by thrombophlebitis (inflammation of veins), usually in the legs
  - 2- Can cause severe complications if not treated quickly
- Aneurysms , or severely dilated blood vessels
  - 1- May rupture and cause severe consequences
- Heart problems, such as:
  - 1- Abnormal heart rhythms
  - 2- Missed heartbeats
  - 3- Early heartbeats
  - 4- Inflammation of the heart muscle ( myocarditis )
- Central nervous system problems
  - 1- For example, meningoencephalitis, which is inflammation of the brain and membrane that lines the brain
  - 2- May result in seizures , confusion, strokes , memory problems, headaches.



**Digestive problems:**

Causes ulcers and inflammation of the digestive tract (rarely). {AbuEl Asrar,etal.(2006)}.

**Diagnosis:**

There are many characteristic features of Behcet's disease. Since no specific diagnostic laboratory test exists, difficulties arise in making a proper diagnosis. Hence, diagnosis relies mainly on observation and identification of typical clinical manifestations. Moreover, there is a long interval between the appearance of an initial symptom and a second manifestation — as long as one decade. Because of this episodic nature of Behcet's disease, proper diagnosis relies heavily on the physician's own abilities. {Jorizzo JL,etal.(1985)}.

**Required Criteria:**

Recurrent oral ulcerations: minor aphthous, major aphthous or herpetiform ulceration observed by physician or patient, which recurred at least 3 times in one 12 month period.

**Minor Criteria:**

Recurrent genital ulceration: aphthous ulceration or scarring observed by physician or patient.

Eye lesion: anterior uveitis, posterior uveitis, or cells in vitreous on slit lamp examination or retinal vasculitis observed by ophthalmologist.

Skin lesions: erythema nodosum observed by physician or patient, pseudofolliculitis or papulopustular lesions, or acneform nodules observed by physician in post-adolescent patients not on corticosteroid treatment.

Positive pathergy test (Behcet's test) read by physician 24-48 hours. Pathergy phenomenon is defined as a state of altered tissue reactivity that occurs in response to minor trauma. Pathergy test (PT) is an easy to perform skin test to look for the pathergy phenomenon. This test is used as a criterion in most diagnostic criteria for Behcet's disease e.g., Dilsen criteria, Japan revised criteria, International criteria, Iran traditional format criteria, and the Classification Tree. [Davatchi F.Behcets disease.2009]



## Types of Pathergy Tests:

- Oral pathergy test
  1. Site: lower lip.
  2. Procedure of oral pathergy test : prick the mucous membrane of the lower lip to the submucosa using a 20 gauge blunt disposable needle.
  3. Assessment: Readings are taken after 48 h, and the test is considered positive if a pustule or ulcer is seen.
  4. Sensitivity: The sensitivity of the oral PT is lower than that of the ordinary skin pathergy test.
  5. Advantage over the skin pathergy test: The oral PT is easier to assess than the skin PT as there is no need to measure the size of the lesion: a pustule or ulcer of any size is considered positive .( Sharquie KE, Al\_Araji A,et al 2002).
- Skin pathergy test
  1. Site: A hairless area on the flexor aspect of the forearms is usually chosen as the test .the skin pathergy test was analyzed in different hairless body areas which included the flexor surfaces of the forearms, the lateral aspect of the tibial area, the scapular areas of the back, and the lumbar areas of the abdominal region. The conclusion that the forearm is the region with the most frequently positive skin pathergy test and the abdomen the least. There is suggestion that variations in positivity of different body segments may result from variation in the structure, thickness and vascularity of the skin on these areas.
  2. Various routes for skin pathergy testing: Intradermal (ID), intravenous (IV) and subcutaneous methods have been used.
  3. Procedure of skin pathergy test: There is no standardized pathergy test. It can be performed using 1-16 needle pricks. In a study conducted by Ozdemir *et al.* on the use of multiple needle pricks for skin pathergy test (SPT), they concluded that two needle pricks are sufficient for SPT. In most studies investigators have used either a sterile needle (20 gauge) prick or an intradermal injection of streptococcal antigens to perform the test. The procedure is performed on a hairless part of the volar forearm. Generally, the needle is inserted vertically or diagonally at an angle of 45° to a depth of 3-5 mm. The needle should reach the dermis for a proper response. {Sharquie KE, Al\_Araji A,et al 2002}.

It was shown that surgical cleaning of the skin surface before application of the needle reduced the test positivity. Some substances, bacteria, or skin products, eliminated by

surgical cleaning, might play a role in the development of skin pathergy reaction. {Kalkan G,etal.(2009)}.

### **Treatment:**

The primary goals of management are symptom control, early suppression of inflammation and prevention of end-organ damage.

### **Topical Treatment:**

Oral ulceration can often be treated by the topical application of corticosteroids, using Creams or mouthwashes (5 mg prednisolone in 20 ml water, four times daily) . [sara E. Marshall, (2008)].

### **Steroid:**

Steroid are one such class of anti-inflammatory agents used in a variety of forms such as topical, oral, or intravenous, or as eye drops. Some patients get treated with high-dose steroids for several weeks to aid in eye, skin; neurological, gastrointestinal, and cardiovascular diseases. But steroids are usually combined with other agents to enhance the effectiveness of the overall treatment. Studies have shown a decrease in pain and improvements in healing with steroids [Alpsoy E. et al (2009)]. Corticosteroids should be given as infusions of intravenous methylprednisolone: 1g IV daily for 3 to 5 days followed by prednisone 0.5 to 1 mg/kg/d for acute attacks [Siva A. et al (2000)]. Acute and severe disease exacerbations of anterior uveitis, posterior, or panuveitis should be treated with higher dosages of systemic corticosteroid to offer a rapid response. Oral prednisolone 1-2 mg/kg/day given in a single morning dose after meals or intravenous pulse methylprednisolone 1 g/day for 3 consecutive days is preferred in concurrence with calcineurin inhibitors or other immunosuppressive drugs as steroid-sparing agents [Kaklamani & Kaklamanis, (2001)].

### **Nonsteroidal anti-inflammatory drugs:**

Nonsteroidal anti-inflammatory drugs (NSAIDs) are commonly used by rheumatologists to treat joint pains in patients with BD. 30 patients with BD were treated with oral indomethacin 25 mg four times daily for 3 months [Simsek *et al.* 1991]. At the initiation of therapy, 28 patients had oral aphthous lesions, 23 had joint involvement, 13 had genital ulcerations, 8 had cutaneous lesions, and 4 had eye involvement. Eighty-eight percent of patients with skin lesions, 80% with joint involvement, 43% with oral aphthous lesions, and 38% with genital ulcerations responded to indomethacin therapy. No serious adverse reactions were observed. Only



three patients developed nausea, anorexia, and abdominal pain that resolved when indomethacin was changed to a suppository form. Thus, NSAIDS may be effective in treating pain in some patients who have BD-related arthritis.

### **Calcineurin Inhibitors (Cyclosporin and Tacrolimus):**

Cyclosporin is the mainstay of treatment of severe Behçet's disease [Kaklamani (2001)]. In ocular disease, it has been shown to decrease the frequency and severity of acute uveitis [Hamuryudan et al. (1998)]. It is also used in hearing loss, thrombophlebitis. Cyclosporine is considered one of the therapeutic options for refractory or severe eye disease (retinal vasculitis or macular involvement) [Hatemi et al. 2009].

For physicians taking care of patients with BD, the decision to use cyclosporine has to be counterbalanced with the risk of developing neurotoxicity. It should not be used in patients with BD with central nervous system involvement unless necessary for intraocular inflammation. Due to its potential neurotoxicity, cyclosporine A should not be the treatment of choice in patients with BD with neurological involvement, as three case-control studies have indicated. It has been suggested that cyclosporine A, itself neurotoxic, may potentiate central nervous system involvement.

### **Tacrolimus:**

Calcineurin inhibitor similar to cyclosporine, may have similar efficacy, but the drug was not tested in an RCT in BD. improve of the visual acuity [Ishioka *et al.* 1994]

### **Colchicines:**

Colchicine was shown to reduce recurrence of genital ulcers in patients with BD, in treating arthritis, and preventing erythema nodosum lesions [Yurdakulet *al.* 2001]. Colchicine (1-2mg/day) has beneficial effects on the mucocutaneous symptoms decreasing the number, size and recurrence of aphthae, [Davatchi et al (2009)].

### **Azathioprine:**

Azathioprine proved to be superior to placebo in decreasing the number of uveitis attacks. azathioprine and CS are recommended as the initial therapy for all patients with BD with inflammation of the posterior segment of the eye [Hatemi et al. 2008].



Azathioprine, alone or in combination with other immunosuppressive drugs, is an important disease-modifying agent. In a large randomized, placebo-controlled trial, azathioprine 2.5 mg/kg/day reduced the incidence, frequency and severity of eye disease, and had a favourable effect on arthritis and oral and genital ulceration when compared with placebo in patients also taking corticosteroids [ Barnes CG, et al. 1990]

### **Dapsone:**

Dapsone is an anti-infective agent with significant anti-inflammatory properties. It is effective in the treatment of mucocutaneous lesions [Sharquie *et al.* 2002] decrease frequency of genital and oral ulcers. Dapsone appears to modify neutrophil function, reversibly inhibits myeloperoxidase activity, inhibits neutrophil lysosomal activity and acts as an anti-oxidant [ Tuzun , 2000].

Dapsone is a useful drug, particularly for the management of the mucocutaneous symptoms of Behçet's disease. Side effects include haemolysis, methaemoglobinemia and agranulocytosis; regular monitoring for possible adverse events is required [Sharquie 2002].

### **Infliximab:**

Anti-TNF- $\alpha$  monoclonal antibody, at a dosage of 5 mg/kg in combination with an immunosuppressive agent, has induced a rapid remission of eye refractory inflammatory signs [F. Cantini, et.al (2012)]. Additionally, infliximab, combined with corticosteroids and/or immunosuppressive agents such as cyclosporine A or azathioprine, an option in nonemergency cases of gastrointestinal involvement [S. Iwata, et al (2011)– A. Borhani Haghghi, et al( 2011)]. The efficacy of infliximab in treating patients with BD with refractory uveoretinitis, entero-Behçet, neuro-Behçet, vascular BD, and arthritis, Side effects of its use have been reported as mild. Some serious adverse events described include a case of pyomyositis, infliximab safe and more effective in reducing the number of uveitis flares compared with cyclosporine in patients with refractory uveoretinitis [Tabbara and Al-Hemidan, (2008)].

### **Adalimumab**

Adalimumab, a humanized IgG<sub>1</sub> monoclonal anti-TNF- $\alpha$  antibody, has been effective in relieving ocular involvement of BD, in particular when patients lost efficacy to infliximab [D. Perra, et al (2012)], Binds to human TNF- $\alpha$  and neutralized its activity a combination therapy of corticosteroids with azathioprine,

cyclophosphamide, methotrexate, anti-TNF- $\alpha$  agents, and interferon may all be considered in cases of meningoencephalitis [G H A T E J V, et al (1999)].

### **Etanercept**

Etanercept is a soluble receptor intercepting circulating TNF- $\alpha$  before it reaches its receptors on the cell surface. [Melikoglu M. et al (2002)]. suppressing most of the mucocutaneous manifestations of BD [Melikoglu et al. (2005)]. Etanercept decreased the frequency of oral ulcers, papulopustular lesions and arthritis with a moderate effect size, and the frequency of genital ulcers and nodular lesions, administered by subcutaneous injection, it was reported that etanercept (25 mg twice/week, for 4 weeks) was effective in suppressing most mucocutaneous lesions [Curigliano et al. (2008)].

### **Anticoagulant**

Thrombosis is a serious complication of Behcet's disease [(Mogulkoc N, et al (2000), Vanhaleweyk G, et al (1990)] ,An episode of deep vein thrombosis (DVT) should be managed as usual, with heparin initially followed by conversion to warfarin. Further episodes may require chronic warfarin therapy (Behcet Syndrome Society), If thrombi are not extensive, low-dose antiplatelet treatment may be sufficient [Erkan F, et al (1992), Erkan F. (1999)].

### **Methotrexate**

Methotrexate (7.5-20 mg/1x week p.o. over 4 weeks) has been reported to induce an improvement of a severe mucocutaneous involvement [(G H A T E J V, et al (1999)].

Methotrexate is not recommended in pregnancy and lactation, and severe bone marrow depression, liver dysfunction, acute infections, renal insufficiency, and mucositis are important side-effects of the drug [(JORIZZO JL, et al (1991)].

### **Pentoxifylline:**

Pentoxifylline is another agent with anti-TNF activity that has been used for the management of orogenital ulceration in Behcet's disease. Licensed for use in peripheral vascular disease, the major pharmacological effect of pentoxifylline is inhibition of the production of various pro-inflammatory cytokines, in particular TNF [Windmeier C & Gressner (1997), . Gan XH, et al (1994)] ,It also has a direct suppressive effect on CD8<sup>+</sup> T lymphocytes [Lazarczyk M , et al (2002)], Furthermore, it

suppresses the production of free radicals and reduces neutrophil-induced tissue damage. [Hill H,et al(1987)].

### **Interferon $\alpha$ :**

IFN $\alpha$  has shown benefit in treating mucocutaneous, articular, and ocular manifestations of BD. RCT showed that IFN $\alpha$ -2a significantly decreased the duration and pain of oral ulcers, and the frequency of genital ulcers and papulopustular lesions compared with placebo. [[Alpsoy et al. 2002; Boyvat et al. 2000; O'Duffy et al. 1998], It also reduced the severity and rate of recurrence of attacks of eye. The primary side effects of IFN- $\alpha$  therapy are flulike symptoms (fever, chills, headache, fatigue, myalgia, etc.) that start a few hours after the initiation of the therapy and continue less than a day. We use oral acetaminophen (paracetamol) 1000 mg orally before injections and 500 mg after 6 hours during the first weeks of the therapy to decrease these side effects. Nausea, vomiting, anorexia, diarrhea, loss of weight, hematologic changes, transient raising of hepatic transaminases are seen less frequently. Psychiatric side effects and depression are limiting factors for use of IFN- $\alpha$ . [S. Onal, et al (2011)]

### **Conclusion:**

According to the EULAR recommendation According to trials, open studies, anecdotal reports, and cases, the best treatment of BD symptoms is:

#### **1-EYE INVOLVEMENT:**

For suppression of inflammation, and prevention of ocular attack, azathioprine (2.5mg per kg per day), can be used. For refractory eye disease, infliximab in combination with cyclosporine A, azathioprine, and corticosteroids (CSs) can be used. For severe cases, cyclosporine A (2-5mg per kg per day) can be used, in the absence of CNS involvement, because of neurotoxicity.

#### **2-VESSEL INVOLVEMENT:**

The main manifestation of blood vessel is thrombosis, and the best treatment for this condition is immunosuppressive agents, such as cyclosporine A, corticosteroids and cyclophosphamide, as these agents can treat the blood vessel inflammations, the leading cause of thrombosis. Heparin and warfarin, can be used also, in the absence of aneurism, as they cause excessive bleeding.



### **3-ANEURYSM:**

The best treatment, is corticosteroids, and cyclophosphamide.

### **4-GASTR- INTESTINAL TRACT:**

For emergency cases, surgery is required, followed by azathioprine, as maintenance therapy, as this drug was found to reduce the number of operations. Immunosuppressive agents can be tried before surgery.

### **5-JOINT INVOLVEMENT:**

Colchicine (1-2 mg per day) usually effective for treatment of arthritis.

### **6-NEUROLOGICAL INVOLVEMENT:**

There are no controlled data to guide the management of CNS involvement in BD, but the agents that can be tried include corticosteroids, azathioprine, cyclophosphamide, methotrexate and biological agents.

### **7-MUCOCUTANEOUS INVOLVEMENT:**

Depending on the severity of lesion, topical corticosteroids are the first line in the management of oral and genital ulcers. While when the dominant lesion is erythema nodosum, colchicine is preferred.

## References:

1. Abu El Asrar, ABoooud EB, ALbibhi H, Al-Arfaj A. Long-term safety and efficacy of infliximab therapy in refractory uveitis due to Behcet's disease. *IntOphthalmol* . Sep 23, 2006.
2. Aksu K, Kabasakal Y, Sayiner A, et al. Prevalences of hepatitis A, B, C and E viruses in Behcet's disease.
3. Alpsyoy E., Durusoy C., Yilmaz E., Ozgurel Y., Ermis O., Yazar S., et al. (2002) Interferon alfa-2a in the treatment of Behcet disease: a randomized placebo-controlled and double-blind study. *Arch Dermatol* 138: 467–471 [PubMed]
4. Arayssi, T. and Hamdan, A. (2004) New insights into the pathogenesis and therapy of Behcet's disease. *Curr Opin Pharmacol* 4: 183–188.
5. BorhaniHaghighi, A. Safari, M. A. Nazarinia, Z. Habibagahi, and S. Shenavandeh,( 2011) "Infliximab for patients with neuro-Behcet's disease: case series and literature review," *Clinical Rheumatology*, vol. 30, no. 7, pp. 1007–1012.
6. Boyvat A., Sisman-Solak C., Gurler A. (2000) Long-term effects of interferon alpha 2A treatment in Behcet's disease. *Dermatology* 201: 40–43.
7. Barnes, C., Tuzun, Ozyazgan, Y., Silman, A. et al. (1990) A controlled trial of azathioprine in Behcet's syndrome. *N Engl J Med* 322: 281–285.
8. Curigliano, V., Giovinale, M., Fonnesu, C., Cerquaglia, C., Verrecchia, E., Turco, S. et al. (2008) Efficacy of etanercept in the treatment of a patient with Behcet's disease. *Clin Rheumatol* 27: 933–936.
9. D. Perra, M. A. Alba, J. L. Callejas, M. Mesquida, R. Ríos-Fernández, A. Adán, et al.,( 2012) "Adalimumab for the treatment of Behçet's disease: experience in 19 patients," *Rheumatology (Oxford)*, vol. 51, pp. 1825–1831.

10. Dapsone in Behcet's disease: a double-blind .53. Sharquie KE and Najim RA (2002) -Raghib placebo control cross over disease. *Journal of Dermatology* 2002; 29: 267-27
11. Davatchi F. Behcet's disease. In: Syngle A, Deodhar SD, editors. *Rheumatology principles and practice*. New Delhi: Jaypee Brothers; 2009. p. 249-68.
12. Davatchi F. Behcet's disease. In: Syngle A, editor , (2008) *Rheumatology: principles and practice*. London, UK: Jp Medical Pub; p. *Annals of the Rheumatic Diseases*, vol. 67, no. 12, pp. 1656-1662.
13. De Menthon, M., Lavalley, M., Maldini, C., Guillevin, L. and Mahr, A. (2009) HLA-B51/B5 and the risk of Behcet's disease: a systematic review and meta-analysis of case-control genetic association studies. *Arthritis Rheum* 61: 1287-1296.
14. Erkan F, C\_ avdar T. (1992) Pulmonary vasculitis in Behcet's disease. *Am Rev Respir Dis*; 146:232- 9.
15. Erkan F.(1999) Pulmonary involvement in Behcet disease. *Curr Opin Pulm Med* ;5:314- 8.
16. F. Cantini, L. Niccoli, C. Nannini et al., (2012) "Efficacy of infliximab in refractory Behcet's disease-associated and idiopathic posterior segment uveitis: a prospective, follow-up study of 50 patients," *Biologics: Targets and Therapy*, vol. 6, pp. 5-12.
17. G H A T E J V, JORIZZO J L: (1999) Behcet's disease and complex aphthosis. *J Am Acad Dermatol* 1999; 40: 1-18
18. Gan XH, Robin JP, Huerta JM, Braquet P & Bonavida B. (1994) Inhibition of tumor necrosis factor-alpha (TNFalpha) and interleukin-1 beta (IL-1 beta) secretion but not IL-6 from activated human peripheral blood monocytes by a new synthetic demethylpodophyllotoxin derivative. *Journal of Clinical Immunology*; 14: 280-288.



19. Hamuryudan Vedat, Seyahi Emir, Melikoglu Melike, Ugurlu Serdal, Hatemi Gulen, Yurdakul Sebahattin and Yazici Hasan, (2014) Anti-tnf treatment for refractory vascular involvement of Behçet's disease Istanbul University Cerrahpasa School of Medicine,
20. Hatemi G, Silman A, Bang D, et al. (2009) Management of Behçet disease: a systematic literature review for the European League Against Rheumatism evidence-based recommendations for the management of Behçet disease. *Ann Rheum Dis.* 2009;68:1528-34. doi: 10.1136/ard.2008.087957.
21. Hatemi, A, Silman, D, Bang, B, Bodaghi, A, M Chamberlain, A, Gul, M, H Houman, I, Ko'tter, I, Olivieri, C, Salvarani, P, PSfikakis, A, Siva, M, R Stanford, N, Stu"biger, S, Yurdakul, I, H Yazici. (2016). EULAR recommendations for the management of Behçet disease.
22. Hill H, Augustine N, Newton J, Shigeoka A, Morris E & Sacchi F. (1987) Correction of a developmental defect in neutrophil activation and movement. *American Journal of Pathology* 1987; 128: 307-314.
23. Hughes, T., Coit, P., Adler, A., Yilmaz, V., Aksu, K, Duzgun, N. et al. (2013) Identification of multiple independent susceptibility loci in the HLA region in Behçet's disease. *Nat Genet* 45: 319-324.
24. Ishioka, M., Ohno, S., Nakamura, S., Isobe, K., Watanabe, N., Ishigatsubo, Y. et al. (1994) FK506 Treatment of noninfectious uveitis. *Am J Ophthalmol* 118:723-729.
25. Jorizzo JL, Solomon AR, Cavallo T (1985) Behçet's syndrome: immunopathologic and histopathologic assessment of pathergy lesions is useful in diagnosis and follow-up. *Arch Pathol Lab Med* 109:747-751.
26. Jorizzo jl, white wl, wise cm, zanolli md, sherertz ef: (1991) Low-dose weekly methotrexate for unusual neutrophilic vascular reactions: cutaneous polyarteriitis nodosa and Behçet's disease. *J Am Acad Dermatol* 24: 973-8.
27. Kirino, Y., Zhou, Q., Ishigatsubo, Y., Mizuki, N., Tugal-Tutkun, I., Seyahi, E. et al. (2013) Targeted resequencing implicates the familial Mediterranean fever gene

MEFV and the toll-like receptor 4 gene TLR4 in Behcet disease. *Proc Natl Acad Sci U S A* 110: 8134-8139.

28. Kalkan G, Karadag AS, Astarci HM, Akbay G, Ustun H, Eksioglu M (2009) A histopathological approach: when papulopustular lesions should be in the diagnostic criteria of Behçet's disease. *J Eur Acad Dermatol Venereol* 23(9):1056-1060102.
29. Kontogiannis V & Powell RJ.( 2000) Behcet's disease. *Postgraduate Medical Journal*; 76: 629-637.
30. Kaklamani VG & Kaklamanis PG. (2001). Treatment of Behçet's disease--an update. *Semin Arthritis Rheum*. Vol.30, No.5, pp.299-312.
31. Kural-Seyahi, E., Fresko, I., Seyahi, NOzyazgan, Y., Mat, C., Hamuryudan, V. et al.(2003)
32. Lazarczyk M, Grzela T, Korczak-Kowalska G, et al. (2002) Pentoxifylline inhibits perforin-dependent natural cytotoxicity in vitro. *Oncology Reports*; 9: 423-426.
33. Lee KH, Chung HS, Kim HS, Oh SH, Ha MK, Baik JH, et al. Human alpha-enolase from endothelial cells as a target antigen of anti-endothelial cell antibody in Behçet's disease. *Arthritis Rheum*. 2003;48:2025-2035.
34. Lee J, Wu W, Lee H, Chang J, Bang D, Lee K. The cross-reactivity of anti human  $\alpha$ -enolase antibody in the sera of Behçet's disease patients to *Streptococcus sanguis* antigen. *Korean J Invest Dermatol*. 2005; 12:83-92(.
35. Lee, Y., Horie, Y., Wallace, G., Choi, Y., Park, JChoi, J. et al. (2013) Genome-wide association study identifies GIMAP as a novel susceptibility locus for Behcet's disease. *Ann Rheum Dis* 72: 1510-1516.
36. Left ventricular thrombi in (incomplete) Behçet's disease. *Eur Heart J*; 11:957-9.

37. Meguro, A., Inoko, H., Ota, M., Katsuyama, Y., Oka A., Okada, E. et al. (2010). Genetics of Behcet disease inside and outside the MHC. *Ann Rheum Dis* 69: 747-754.
38. Melikoglu, M., Fresko, I., Mat, C., Ozyazgan, Y., Gogus, F., Yurdakul, S. et al. (2005) Short-term trial of etanercept in Behcet's disease: a double blind, placebo controlled study. *J Rheumatol* 32: 98-105.
39. Melikoglu M, Ozyazgan Y, Fresko I. The response of treatment resistant uveitis in Behcet's syndrome (BS) to a TNF-alpha blocker, etanercept: an open study. *Arthritis Rheum* 2002; 46(Suppl): S181.
40. Mizuki, N., Meguro, A., Ota, M., Ohno, S, Shiota, T., Kawagoe, T. et al. (2010) Genome-wide association studies identify IL23R-IL12RB2 and IL10 as Behcet's disease susceptibility loci. *Nat Genet* 42: 703-706.
41. Mogulkoc N, Burgess MI, Bishop PW. (2000). Intracardiac thrombus in Behcet's disease: a systematic review. *Chest*; 118:479- 87.
42. Muftuoglu AU, Yazici H, Yurdakul S, et al. Behcet's disease. Relation of serum C-reactive protein and erythrocyte sedimentation rates to disease activity. *International Journal of Dermatology* 1986; 25:
43. N. Pipitone, I. Olivieri, A. Padula et al., (2008) "Infliximab for the treatment of neuro-Behcet's disease: a case series and review of the literature," *Arthritis Care and Research*, vol. 59, no. 2, pp. 285-290
44. O'Duffy J., Calamia K., Cohen S., Goronzy J., Herman D., Jorizzo J., et al. (1998) Interferon-alpha treatment of Behcet's disease. *J Rheumatol* 25: 1938-1944 [PubMed]
45. Remmers, E., Cosan, F., Kirino, Y., Ombrello, M, Abaci, N., Satorius, C. et al. (2010) *Genome-wide Rheumatology (Oxford)* 1999; 38: 1279-1281.
46. Siva A, Fresco I. (2000). Behcet's disease. *Curr Treat Options Neurol*; 2:435- 448.
47. Sharquie, K., Najim, R. and Abu-Raghif, A. (2002) Dapsone in Behcet's disease: a double-blind, placebo controlled, cross-over study. *J Dermatol* 29: 267-279.



48. S. Iwata, K. Saito, K. Yamaoka et al., (2011) "Efficacy of combination therapy of anti-TNF- $\alpha$  antibody infliximab and methotrexate in refractory entero-Behçet's disease," *Modern Rheumatology*, vol. 21, no. 2, pp. 184–191.
49. S. Onal, H. Kazokoglu, A. Koc, et al., (2011). "Long-term efficacy and safety of low-dose and dose-escalating interferon alfa-2a therapy in refractory Behçet uveitis," *Archives of Ophthalmology*, vol. 129, no. 3, pp. 288–294.
50. Sakane, T., Takeno, M., Suzuki, N. and Inaba , (1999) Behcet's disease *G Med* 341: 1284–1291
51. Sara E. Marshall, (2008),Behçet's disease *Clinical Rheumatology*
52. Sawalha, A., Hughes, T., Nadig, A., Yilmaz, VAKsu, K., Keser, G. et al. (2011) A putative functional variant within the UBAC2 gene is associated with increased risk of Behcet's disease.*Arthritis Rheum* 63: 3607-3612.
53. .Sohn S, Lee ES, Bang D, Lee S. Behçet's disease-like symptoms induced by the Herpes simplex virus in ICR mice. *Eur J Dermatol.* 1998; 8:21–23
54. Tabbara, K. and Al-Hemidan, A. (2008) Infliximabeffects compared to conventional therapy in themanagement of retinal vasculitis in Behcet disease*Am J Ophthalmol*146: 845–850.
55. Tanaka, H., Sugita, S., Yamada, Y., Kawaguchi, T., Iwanaga, Y., Kamoï, K. et al. (2010) [Effectsand safety of infliximab administration in refractoryuveoretinitis with Behcet's disease]. *Nippon GankaGakkaiZasshi* 114: 87–95
56. Vanhaleweyk G, El Rahami KM, Hazmi M, Sieck JO, Zaman L, Fawzy M. (1990)Right atrial, right ventricular and Vol. 18, No. 3, pp. 291–311
57. Windmeier C &Gressner AM. (1997)Pharmacological aspects of pentoxifylline with emphasis on its inhibitory actions on hepatic fibrogenesis. *General Pharmacology*; 29: 181–196

58. Yurdakul, S., Mat, C., Tuzun, Y., Ozyazgan, Y., Hamuryudan, V., Uysal, O. et al. (2001) A doubleblind trial of colchicine in Behcet's syndrome. *Arthritis Rheum* 44: 2686-2692.