

Protective effect of *Panax ginseng* on Flutamide-induced spermatogenesis impairment in adult rats

Shaima Ahmed Rahim

Department of Biology. College Of Science For Woman Babylon University ,Iraq
shaima.hilla@yahoo.com

Abstract

Flutamide is non-steroidal ,antiandrogenic drug,commonly used in the treatment of advanced prostate cancer, acne and hirsutism, this drug may induce suppression spermatogenesis. This study aims to evaluate the protective effect of *Panax ginseng* roots against Flutamide-induced testicular toxicity in adult male rats . the animals were divided into six groups: First group as a control; second group were given orally flutamide at dose (25 mg/kg b.wt) for seven days; third and fourth groups were injected intrapretonially with *P.ginseng* extract at dose of (200,400) mg/kg/day for thirty five days ,fifth group were given orally flutamide (25 mg/kgb.wt) for seven days then were injected intrapretonially *P.ginseng* extract at dose (200 mg/kg/day) for thirty five days ,and sixth group were given orally flutamide (25 mg/kgb.wt) for seven days then were injected intrapretonially *P.ginseng* extract at dose (400 mg/kg/day) for thirty five days. all groups were treated daily, Twenty four hrs after last treatment all rats were euthanized , Tissue sampling of the testis was done after the mentioned time for each group, tissue slices were stained by H&E technique.Gonadosomatic index, histomorphometrical and Histopathological analysis of the testis was carried out , Male rats exposed to flutamide had significant reduction in spermatogenesis related- parameters included : Diameter of seminiferous tubules, Epithelial height of seminiferous tubules , Germ cells count ,Sertoli cells count , Johnsen's score, Tubular differentiation index (TDI), and Spermiogenesis index (SPI) compared with the control and *P.ginseng* treated groups , Flutamide induced histopathological changes in the testis , water extract of *P.ginseng* manifested marked improvement in spermatogenesis as well as histopathological alteration. The results of this current study suggest that the testicular changes induced by Flutamide were significantly recovered by *Panax ginseng* roots

.**Key words:** *Panax ginseng*; flutamide,spermatogenesis, testis.

الخلاصة :

الفلوتاميد مضاد اندروجيني ،الاستيرويدي يستخدم عادة في علاج سرطان البروستات المتقدم، حب الشباب والشعرانية، وهذا الدواء قد يسبب اعاقا لعملية نشأة النطفة. تهدف هذه الدراسة إلى تقييم الاثر الوقائي لجذور نبات الجينسينغ ضد تسمم الخصية التي يسببها الفلوتاميد لدى ذكور الجرذان البالغة. تم تقسيم الحيوانات إلى ست مجاميع: المجموعة الأولى كمجموعة سيطرة ؛ أعطيت المجموعة الثانية الفلوتاميد عن طريق الفم بجرعة (25 ملغم / كغم b.wt) لمدة سبعة أيام؛ تم حقن المجموعة الثالثة والرابعة بمستخلص الجينسينغ بجرعة (200,400) ملغم / كغم / يوم في التجويف البريتوني لمدة خمسة وثلاثين يوما، وأعطيت المجموعة الخامسة الفلوتاميد عن طريق الفم بجرعة (25 ملغم /كغم b.wt) لمدة سبعة أيام ثم حقنت بمستخلص نبات الجينسينغ بجرعة (200 ملغم / كغم / يوم) في التجويف البريتوني لخمسة وثلاثين يوما، وأعطيت المجموعة السادسة الفلوتاميد عن طريق الفم بجرعة (25 ملغم / كغم b.wt) لمدة سبعة أيام ثم حقنت بمستخلص نبات الجينسينغ بجرعة (400 ملغم / كغم / يوم) في التجويف البريتوني لخمسة وثلاثين يوما . عوملت كل المجاميع يوميا ، تم تخدير الحيوانات بعد أربع وعشرون ساعة من اخر جرعة ، وقد تم أخذ عينات من انسجة الخصى لكل مجموعة، و صبغت شرائح الأنسجة بتقنية الهيماتوكسيلين - ايويسين , و قد تم تقدير Gonadosomatic index و histomorphometrical and Histopathological analysis ، اظهرت ذكور الجرذان المتعرضة للفلوتاميد انخفاض معنوي في المعايير المرتبطة بعملية نشأة النطفة و التي تشمل : اقطار النبيبات المنوية ، ارتفاع بطانة النبيبات المنوية ، اعداد الخلايا الجرثومية ، اعداد خلايا سرتولي ، مؤشرونسن ، ومؤشر تمايز النبيبات (TDI)، ومؤشر حؤول النطفة (SPI)) بالمقارنة مع مجموعة السيطرة ومجموعة الحيوانات المعاملة بالجينسينغ ، اظهر المستخلص المائي لنبات الجينسينغ تحسن ملحوظ في عملية نشأة النطفة بالاضافة الى التبدلات المرضية النسيجية التي سببها المعاملة بالفلوتاميد . تشير نتائج هذه الدراسة الحالية الى أن التغييرات الخصوية الناجمة عن الفلوتاميد صححت معنويا بواسطة جذور نبات الجينسينغ .

الكلمات المفتاحية : باناكس جينسينغ , فلوتاميد, عملية نشأة النطفة , الخصية.

Introduction

Environmental, anti-androgenic compounds have been recognized as endocrine disruptors because of their hormone-like activities. Antiandrogenic chemicals have the potential to interfere with male reproductive development and function in human and animals. The endocrine disruptors are thought to act via many mechanisms, such as by decreasing androgen synthesis, exerting effects on the pituitary-gonadal axis and/or blocking the androgen receptor. The consequences of these actions may cause abnormal hormonal regulation and gene expression (Sharpe, 2006, Metzdorff *et al.*, 2007).

Flutamide (4'-nitro-3'-trifluoro-methylisobutyranilide) is a potent non-steroidal androgen receptor antagonist (Kassim *et al.*,1997)..Flutamide acts by inhibiting the uptake and/or binding of dihydrotestosterone to the target cell receptor, thus interfering with androgen action. Flutamide is well absorbed orally and extensively and rapidly metabolized to its active metabolite, 2-hydroxyflutamide, and excreted almost entirely by the kidneys (Xu and Li, 1998). In male patients who display androgen excess, flutamide is used therapeutically to treat androgen dependent prostate cancer, where it prevents androgens from binding to androgen receptors in the prostatic gland and in prostatic cancer cells (Javier *et al.*, 2001, Zhang *et al.*, 2005). It is also used in young women who suffer increased androgen production, such as hirsutism, acne and seborrhea (Thiboutot & Chen, 2003, Sahin & Kelestimur, 2004).

Flutamide is regarded as a model antiandrogen and in experimental studies it is often used as a positive control in screening assays used for the identification of endocrine disruptors (O'Connor *et al.*, 1998). Several studies demonstrated the effects of short-term androgen blockage induced by the administration of flutamide to immature or mature males(Maschio *etal.*,2010, Vo *etal.*,2009). Pre- and postnatal exposure of rats to Flutamide alter androgen-dependent reproductive development and function (Kassim *e tal.*,1997). It has been indicated that exposure of rats to Flutamide caused a dysregulation in expression of hypothalamus/ pituitary hormone genes and consequently this may affect gonadotropin release and induce an over-expression of testicular steroidogenic enzyme genes(Ohsako *etal.*,2003).

A number of studies are conducted on the use of herbal plants within the treatment of infertility. Seeing as these plants typically have low side effects, their administration can be an appropriate approach.

Panax ginseng, a traditional multipurpose herb in Asia, has become the world's most popular herbal supplements in recent years. *P.ginseng* has a variety of beneficial biological processes that include anti-carcinogenic, anti-diabetic and anti-inflammatory effects,anti-stress, anti-aging, antioxidant and gonadal function improvement as well as cardiovascular-and neuro-protection, (Jung *et al.*,2005).

The herb is used in its entirety and prepared as tea, powder, or capsules. The herb contains saponins or soap like materials that have been named with various numbers and letters, such as Rg1 with a root said to have a composition similar to that of steroids (Liu *e tal.*, 1995). The herb is a deciduous perennial belonging to the Family Araliaceae. The herbal root is named ginseng, because it is shaped like a man or human body (Yun, 2001). Named by botanist Carl Meyer in (1842), the genus panax (pan=all+axos=medicine) means cure all or a panacea in Greek (Gillis, 1997). The most important part of ginseng is the root, ginseng roots contain various pharmaceutical components ginsenosides (saponins), polyacetylenes, polyphenolic compounds and acidic polysaccharides, and among the components, ginsenosides are the most pharmaceutically active (kim *et al.*,2005). Until now, 38 ginsenosides are

isolated from ginseng roots, with five major ginsenosides (ginsenosides Rb1, Rb2, Rc, Re and Rg1) constituting more than 80% of the total ginsenosides (kim *et al*,1999).

Several clinical studies indicated the beneficial effects of ginseng on the male fertility in different animal models such as mice (Yoshimura *etal*,1998), rabbit (kim *etal*,1998), Guinea pig (Kim *et al*, 1999) and rats (Tsai *etal.*, 2003).. In addition, human studies indicated a beneficial effect of ginseng on healthy human subjects (Salvati *etal*,1996) and patients (Hong *etal*, 2002). These effects of ginseng might not be due to changes in hormone secretion, but to direct effects of ginseng or its ginsenoside components on the central nervous system and gonadal tissue (Hong *etal*,2002, Murphy&Lee,2002). the administration of ginseng water extract protects testicular function(kim *etal*,1999), and improves sperm survival rate and quality in guinea pigs exposed to 2,3,7,8-tetrachlorodibenzo-p-dioxin (Hwang *etal*,2004). There is evidence to support the use of *Panax ginseng* in the treatment of male sexual dysfunction (Hong *etal*,2002).

The objective of this work is to elevate the potential protective action of *Panax ginseng* roots against Flutamide toxicity particularly on testis of adult male rats.

Materials and method

Chemicals:

Flutamide(tablet 250mg) was obtained from medochemic limited –MLT Ciprus. Flutamide dissolved in 10ml of pure corn oil, and each 1ml contains 25 mg of flutamide (Sanchez-Craido *et al*,1999).

Preparation of aqueous extract of *Panax.ginseng*

Root powder of Korean ginseng (*Panax ginseng*) was purchased from al-kawther herb in hilla city -babylon, for preparation 200mg or 400mg/kg of an aqueous extract, 40 mg or 80 mg of herbaceous plant roots were added to 100mL cold water and mixed in an electric mixture for 20 minutes. The mixture was centrifuged, and the clear supernatant was carefully removed and kept in a refrigerator at 2–8°C as a final extract for subsequent experimental treatments the dose was calculated according to the animal's body weight.

Animals : The study was carried out on 24 adult male albino rats weighing 200 to 300 g and obtained from the Animal House Laboratory, Faculty of Science, Kufa University and acclimatized to the facility for at least 1 week before the experiment and kept under standard conditions, temperature 20°C, humidity 60% and 12/12-h light/dark cycle and maintained on standard diet and free water supply *ad libitum* till the end of study.

Experimental design

After the period of acclimation, animals were divided into six groups with 4 animals in each as :

- 1) Control group:** Animals received 1ml of distilled water orally daily for 35 days.
- 2) Flutamide treated group:** Animals daily received orally dose of Flutamide (25 mg/kg b.wt.) for 7 days using metallic stomach tube.
- 3) *Panax Ginseng* treated group:** Animals were injected intrapretonially (200 mg/kg b.wt.) daily for 35 days.
- 4) *Panax Ginseng* treated group:** Animals injected intrapretonially (400mg/kg b.wt.) daily for 35days .
- 5) Flutamide +*P.Ginseng* treated group:** Animals were given orally Flutamide (25mg/kg b.wt.) for 7days and then injected intrapretonially with *P. ginseng* extract (200mg/kgb.wt) for 35 days .

6) Flutamide+P. Ginseng treated group: Animals were given orally Flutamide (25mg/kg b.wt.) for 7 days and then injected intrapretonially with *Ginseng* extract (400mg/kg b.wt.) for 35 days.

Gonadosomatic index (GSI)

Having determined the weight of the left and right testicles of each animal, it was also possible to calculate the gonadosomatic index (percentage of the body occupied by the gonad) using the following formula:

$$\text{Gonadosomatic index (\%)} = [(RTw + LTw(g) / Bw(g))] \times 100$$

Being: RTw = weight of right testis;

LTw = weight of left testis;

Bw = body weight . (Predees *et al*,2007).

Histological technique:

At the end of the experiment, The rats were euthanized under general anesthesia with diethyl ether. testes were isolated and weighed after removing any adhering adipose and fixed in 10% formal saline for 24 hours. Paraffin blocks were sectioned at 5 microns thickness by rotary microtome. The paraffin sections were then stained by hematoxylin and eosin stains (Bancroft and Stevans, 1996)) and examined with the light microscope.

Analysis of spermatogenesis-related parameters

Five slides were selected from each group and 10 seminiferous tubules within each slide were evaluated for spermatogonia ,spermatocytes and the Sertoli cell counts, and The average of the different cell counts of each slide was used for the analysis. The evaluation of all of the samples was performed at a constant magnification of 40× with light microscopy (McLachlan *etal*,1996).

More than 100 horizontally sectioned seminiferous tubules per group were analyzed to determine the spermatogenesis-related histology. All seminiferous tubules in one histological section of the testicular specimen were evaluated and scored on a scale of 1 to 10 using Johnsen’s scoring system(Johnsen, 1970). Briefly, the scoring is as follows:

S\No	Parameter
10	complete spermatogenesis with many spermatozoa
9	many spermatozoa present, but with a disorganized spermatogenesis
8	only a few (<5) spermatozoa
7	no spermatozoa, but many spermatids
6	no spermatozoa and only a few(<5) spermatids
5	no spermatozoa and spermatids but several or many spermatocytes
4	no spermatozoa and spermatids and only a few spermatocytes (<5)
3	spermatogonia were the only germ cells present
2	no germ cells, but Sertoli cells were present
1	no cells in a tubular section

The tubular diameter of the seminiferous tubule and the height of the seminiferous epithelium which was regarded as the distance from the basement membrane to the tubular lumen, were measured by using an ocular micrometer calibrated with a stage micrometer. fifty tubular profiles that were spherical or nearly spherical were chosen

randomly and measured for each group. The epithelium height was obtained within the same tubule sections utilized to determine tubular diameter(Brendtson, 2008).

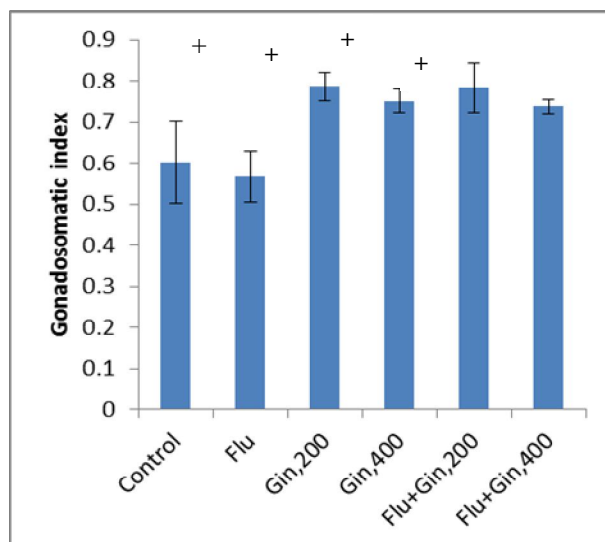
For the estimation of spermatogenesis in testicular tissue, two different indices were used. Tubular differentiation index (TDI), and spermiogenesis index (SPI). To determine the tubular differentiation index, the number of seminiferous tubules that have more than three layers of germinal cells derived from type A of spermatogonia was calculated. To find out the spermiogenesis index, the ratio of the number of seminiferous tubules with spermatozooids to the empty tubules was calculated (Meistrich *etal*,2003, Shetty *etal*,2000).

Statistical analysis The data were expressed as Mean±SEM Statistical analysis was performed with ANOVA followed by Post-Hoc Tukey multiple range tests using the Statistical Package for the Social Sciences (SPSS/version 17.0) for Windows. P <0.05 were considered statistically significant .

Results and discussion

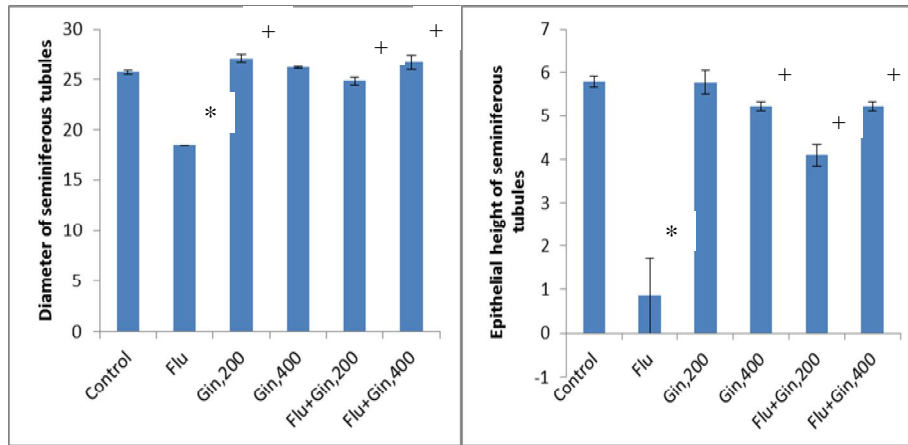
Spermatogenesis is the formation of mature sperms from primitive germ cells occurring in the testis. This process is under hormonal control by hypothalamus-hypophysis -gonadal axis. Androgens are essential for male development and play an indispensable role in the process of spermatogenesis. Androgens act on their target cells via an interaction with androgen receptors (AR) resulting in direct regulation of gene expression(Brinkmann *et al*,1999). Antiandrogens block the androgen receptors competitively by producing a different conformational change avoiding participation of testosterone in the cellular processes. In an animal study on rats, the administration of antiandrogen such as flutamide, results in impaired spermatogenesis and dysfunction of accessory sex organs(Bustos-Obregon *et al*,2006).

Administration of Flutamide for 7 days did not result in any changes in testicular weight represented in Gonadosomatic index(GSI) figure(1), These findings are similar to that obtained by (Back *etal*,1977,Dhar and Setty,1976,Yamada *etal*,2000) the reason may be due to the shorter duration of study .



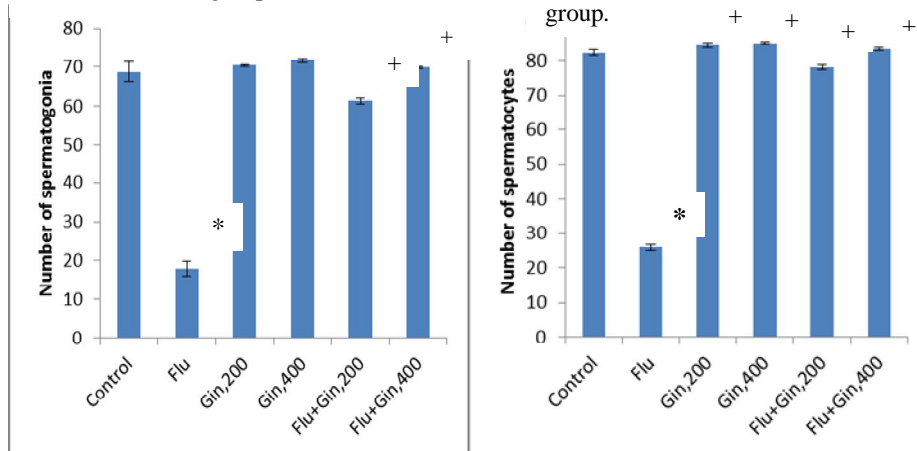
Figure(1):Gonadosomatic index (GSI) in control and treated groups , Results are presented as Mean ± SEM,+ p<0.05 compared to the Flutamide treated group.

This study showed that Flutamide had destructive effects on testis tissue and parameters related to spermatogenesis which includes :(Tubular diameter,epithelial height of seminiferous tubules , germ cell count ,sertoli cells count , Johnsen's score, Tubular differentiation index (TDI), and spermiogenesis index (SPI)) compared with the control and treated groups Figure(2),(3),(4),(5),(6),(7),(8),(9),(10), The possible mechanism that explains these destructive effects of exposure to flutamide on testicular structure: flutamide blocks the physiological action of testosterone at androgenic receptor sites and/or alters androgen receptor levels (Kelce *et al*,1997) and consequently, causes atrophic changes to the seminiferous tubules by depressing the function of Sertoli cells. (Vo *et al*,2009) reported the anti-androgenic effects of flutamide to alter reproductive function, This is in concert with, our results as flutamide disrupted germ cells of the seminiferous tubules.



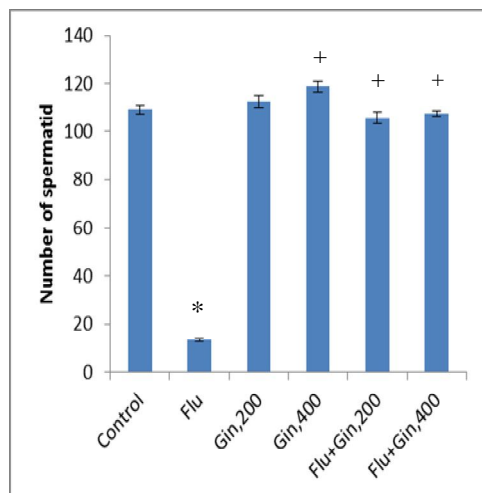
Figure(2):Diameter of seminiferous tubules in control and treated groups , Results are presented asMean \pm SEM ,*P<0.05 compared to the control ,+ p<0.05 compared to the Flutamide treated group.

Figure(3):Epithelial height of seminiferous tubules in control and treated groups , Results are presented asMean \pm SEM ,*P<0.05 compared to the control ,+ p<0.05 compared to the Flutamide treated group.

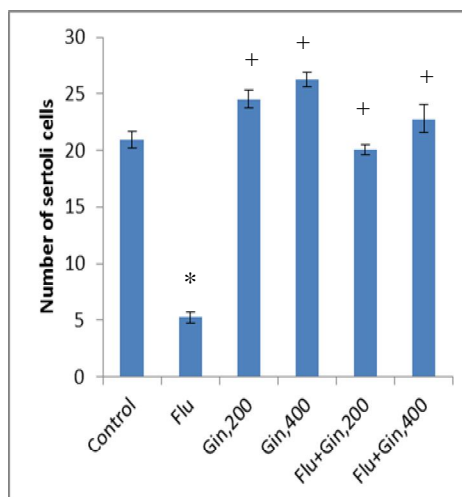


Figure(4):Number of spermatogonia in control and treated groups , Results are presented asMean \pm SEM ,*P<0.05 compared to the control ,+ p<0.05 compared to the Flutamide treated group.

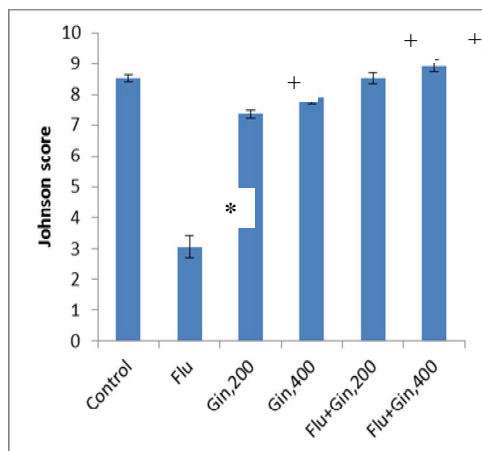
Figure(5):Number of spermatocytes in control and treated groups , Results are presented asMean \pm SEM ,*P<0.05 compared to the control ,+ p<0.05 compared to the Flutamide treated group.



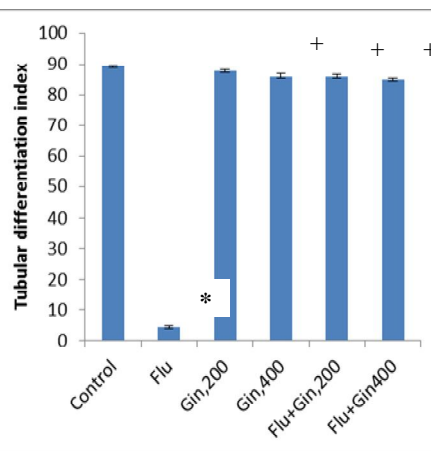
Figure(6):Number of spermatid in control and treated groups , Results are presented as Mean \pm SEM , *P<0.05 compared to the control , + p<0.05 compared to the Flutamide treated group.



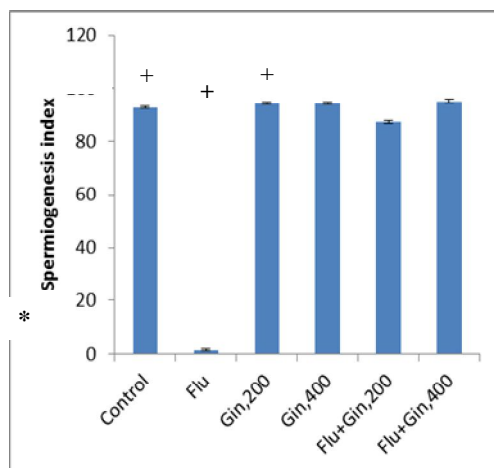
Figure(7):Number of sertoli cells in control and treated groups , Results are presented as Mean \pm SEM , *P<0.05 compared to the control , + p<0.05 compared to the Flutamide treated group.



Figure(8):Johnson's score in control and treated groups , Results are presented as Mean \pm SEM , *P<0.05 compared to the control , + p<0.05 compared to the Flutamide treated group.



Figure(9):Tubular differentiation index(TDI) in control and treated groups , Results are presented as Mean \pm SEM , *P<0.05 compared to the control , + p<0.05 compared to the Flutamide treated group

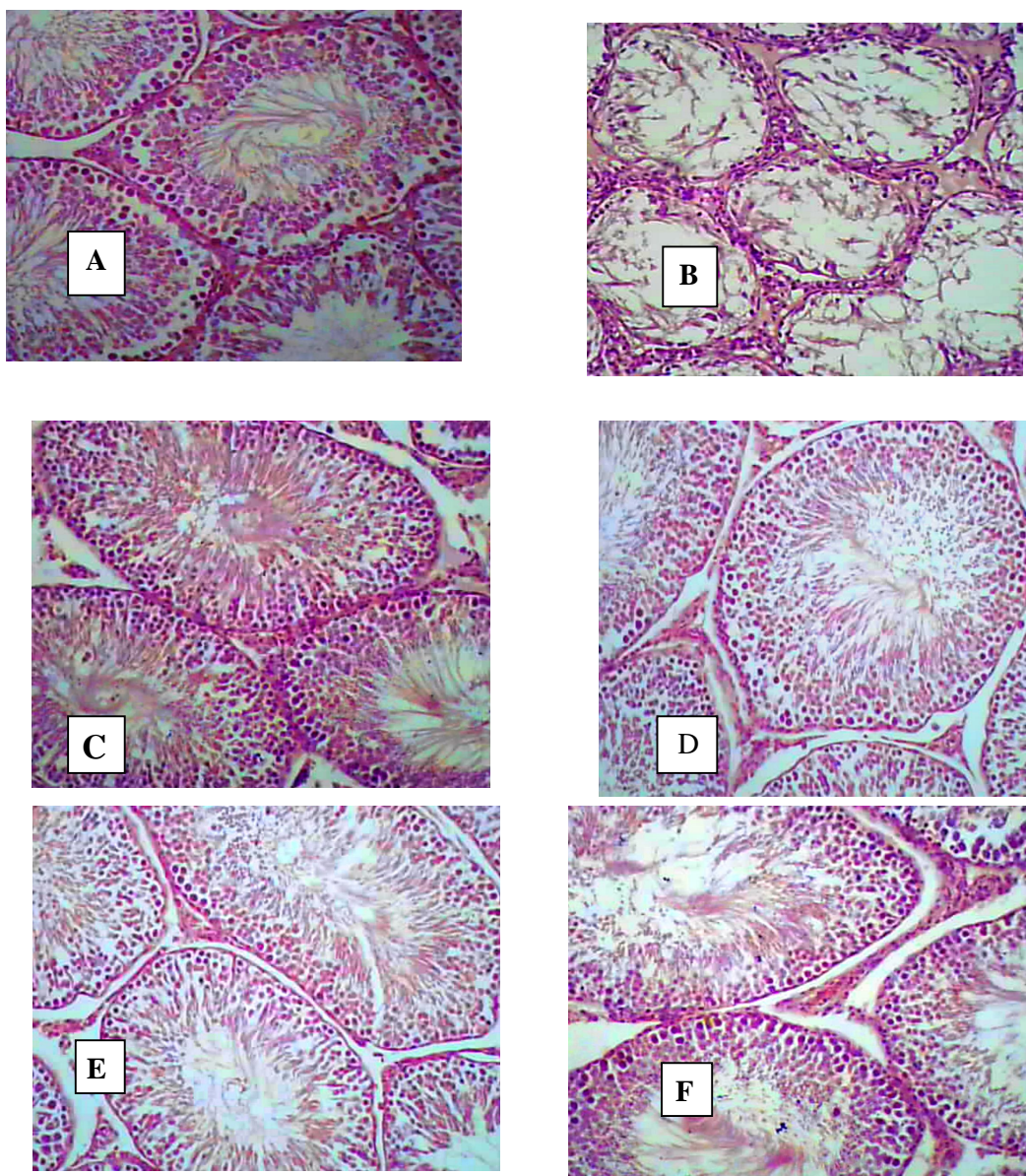


Figure(10):Spermogenesis index (SI) in control and treated groups , Results are presented as Mean \pm SEM , *P<0.05 compared to the control , + p<0.05 compared to the Flutamide treated group.

It is believed that flutamide disrupts the function of the hypothalamo-pituitary-gonadal (HPG) axis (Kassim *et al*,1997). This could be the reason for the increase in LH of flutamide treatment, Decreased testosterone level is usually accompanied with increased LH production by the anterior pituitary gland. Hence, this increase in luteinizing hormone resulted from the decreased testosterone feedback. It has been reported by (Cheng *et al*,2008) that testosterone plays an important role in maintaining quantitatively normal spermatogenesis. And decreased testosterone was accompanied with disrupted spermatogenesis. Furthermore, (Ohsako *et al* ,2003) reported that subacute flutamide administration for 6 days first affected hypothalamus/pituitary hormone gene expression resulting in altered testicular steroidogenesis and decreased sperm production. Flutamide administration has also been found to affect the initial step of spermatogenesis and cause a reduced sperm count due to inhibition of differentiation of spermatogonia to spermatocytes (Viguiet-Martinez *et al*, 1985, Chandolia,*et al*,1991a,b).

On the idea of the results of present experiment it is concluded that the testicular atrophy as evidenced by decrease in diameter of seminiferous tubules, thickness of germinal epithelial tissue as a result of the toxic effect of the antiandrogen such as Flutamide on the testes in generally and seminiferous tubule in particular.

Histological and histomorphometrical examination of the testis by H&E technique disclosed that Flutamide treated group compared with those of control group: severe epithelial degeneration and atrophy of most seminiferous tubules with the loss of sperm and additionally showed significant decrease in means of Johnsen's score, Tubular differentiation index (TDI), and Spermogenesis index (SPI) a number of these changes are shown in figures (8),(9),(10) , whereas there have been no histopathological changes in the control and Ginseng 200,400mg/kg treated groups and (Flutamide +Ginseng 200 ,400mg/kg) treated groups .



Photomicrographs showing sections of testes administered: control(A), Flutamide(B), *Ginseng*200mg/kg(C), *Ginseng*400mg/kg(D), Flutamide+*Ginseng*200mg/kg(E), Flutamide+*Ginseng* 400mg/kg(F), stained with H&E at magnification X200, The cellular structure of the seminiferous tubules was almost normal in appearance for all groups . However, Flutamide treatment induced severe epithelial degeneration ,atrophy of most seminiferous tubules ,loss of sperm and reduction in the number of spermatogenic cells and epithelial height of seminiferous tubules.

Panax ginseng was known to have protective and therapeutic effects against the testicular atrophy and other damages induced by the most potent environmental pollutants toxic to reproductive organs (Kim *et al*,1999). Ginsenosides are triterpenoid saponins that structurally resemble the steroid hormones. Thus, it's tempting to investigate the effects of ginsenosides on sexual function and spermatogenesis as a result of activation of steroid receptors. Androgens are sex steroids that are essential for the development and maintenance of male sexual characteristics, and regulate traditional

spermatogenesis (Leung and Wong,2013). Androgen receptor (AR) is abundantly expressed in male genital tissues and in spermatozoa (Solakidi *etal*,2005).

Our data showed that there was statistically significant increase in testis weight represented in Gonadosomatic index in (*Ginseng* 200,400 mg/kg) treated groups compared with control group and (Flutamide + *Ginseng* 200,400 mg/kg)treated groups compared with Flutamide group figure(1), These findings are like that obtained by(Moon and Park,1970) showed that *Ginseng* increased gonadal weight in young male and female rats receiving *ginseng* alcohol extract, In addition, (Yamamoto *etal*,1977) showed that *ginseng* could stimulate protein synthesis through activation of DNA-dependent RNA -polymerase with increasing the testicular nucleic acid content, indicating the stimulatory effect of *ginseng* on spermatogenesis. where the herb was reported to promote the growth of the testis and spermatogenesis in rabbits (Brekhman,1964).

The obtained results from figure(2),(3),(4),(5),(6),(7) revealed significant changes in parameters related to spermatogenesis, which includes : Tubular diameter,epithelial height of seminiferous tubules , germ cell count ,sertoli cells count in (*Ginseng* 200, 400mg/kg) groups compared with control group, also (Flutamide + *Ginseng* 200,400 mg/kg) treated groups showed significant increase in these parameters compared with flutamide group , these spermatogenic effects of. *ginseng* might be due to the combined effect of its many components , ginsenosides, (saponins) polyphenol and minerals (Park *etal*,2006). among the components, ginsenosides are the most pharmaceutically active (Kim *etal*,2005). (Salvati *etal*, 1996) suggested that ginsenosides might have an effect at the different levels of the hypothalamus pituitary-testis axis, where it can stimulate hypothalamic gonadotropins-releasing hormone (GnRH) release, stimulate pituitary gonadotropins release and stimulate synthesis and secretion of testicular androgens. (Renyong and Hong,1986) reported that the LH secretion of adenohypophysis incubated with *ginseng* (G) or pantocrine (P) significantly increased. Furthermore (Tsai *etal*,2003) found that ginsenosides Rb1 in a dose-dependent manner increased the release of LH from both hemi-anterior pituitary tissue and dihydrotestosterone (DHT), suggesting that ginsenosides Rb1 increases LH secretion by acting directly on the anterior pituitary cells. In addition, (Renyong and Hong,1986)) and (Tsai *etal*,2003) showed that ginsenosides increase LH secretion by acting directly on anterior pituitary cells, coinciding with (Hafez,1976), LH binds to a cell surface receptor in interstitial cells leading to activation of adenylyl cyclase resulting in generation of cAMP and subsequent activation of protein Kinase. This ultimately results in stimulation of steroidogenesis and production of testosterone.

In our study, histopathological changes appeared in the testes of rats treated with *Ginseng* revealed statistically significant increase in Johnsen's score figure(8), that offers a convenient and rapid method for registration of spermatogenesis (Johnsen's,1970), Thus an increase in the mean of Johnsen score is an indirect evidence of improvement in the sperm count (Iftikar *etal*,2014),also , increase in Tubular differentiation index (TDI), and spermiogenesis index (SPI) was observed after *Ginseng* treatment figure(9),(10), may be due to activated spermatogenesis, hyperplasia of the epithelial lining which could be attributed to the effect of the testosterone hormone (Pineda and Dooly,2003). (Fahim *etal*,1982) found a significant increase in blood testosterone level in rats treated with purified *panax ginseng* 1% and 5% in diet for 60 days. Moreover, (Salvati *etal* ,1996) observed an increase in plasma total and free testosterone, dihydrotestosterone, FSH, and LH levels with a decrease in prolactin (PRL) in patients treated with 4 gm/oss *Panax ginseng* extract for 3 months.

the stimulatory effect of ginseng on pituitary gonadotropins release may play a role in the process of spermatogenesis, where gonadotropic control of spermatogenesis involves LH stimulation of testosterone secretion by interstitial cells into the tissue surrounding the seminiferous tubules. FSH stimulate androgen binding protein (ABP) production by Sertoli cells, and transport of testosterone into the tubular lumen and then to the germ cells, where it interacts with a specific cytoplasmic receptor protein (CR) and stimulates the metabolic activities and maturation of germ cells (Hafez,1976).(Jang *et al* ,2012) reported that administration of ethanol plus red ginseng extract appeared to minimize the negative effects of ethanol toxicity on male fertility. This is in concert with the findings from this study as *Panax ginseng* ameliorated the toxic effects of flutamide on the testis .

From our present data it can be concluded that alteration of testis structure and histopathology induced by Flutamide toxicity could be improved in animals after receiving *Panax ginseng* roots . This study shows that treatment of *panax ginseng* after treated with flutamide has therapeutic and protective role.

References

- Back,D.J.;Glover,T.D.;Shenton,J.C.and Boyd,G.P.(1977).Some effect of cyproterone and cyproterone acetate on the reproductive physiology of the male rat .J.Repro.and Fertil.,49:237-243.
- Bancroft, J.D. and A. Stevens, (1996). Theory and Practice of Histology Techniques.4th ed. Churchill Livingstone: London.
- Brekhman, I.I., (1964). *Panax Ginseng: Its pharmacological problems* (translated from Russian into Japanese by M. Fakazawa), Matumato, Japan: Shinshu Ginseng Grower's co-operative Union, PP 80 - 85.
- Brendtson, W.E.(2008). Comparative reliability and sensitivity of different methods for assessing treatment effects on sperm production. *Anim Reprod Sci*; 105 (1-2): 5 - 22.
- Brinkmann, A.O.; Blok, L.J.; de Ruiter, P.E.; Doesburg, P.; Steketee, K.; Berrevoets, C.A.; and Trapman, J.(1999). Mechanisms of androgen receptor activation and function. *J Steroid Biochem Mol Biol*. 69(1-6): 307 - 13.
- Bustos-Obregon, E.; Esponda, P. and Sarabia, L.(2006). Effect of flutamide in mouse spermatogenesis and on the function of seminal vesicle and prostate. *Int J. Morphol*. 24(2): 171 -74.
- Chandolia, R.K.; Weinbauer, G.F.; Simoni, M.; Behre, H.M. and Nieschlag, E.(1991a). Comparative effects of chronic administration of the non-steroidal antiandrogens flutamide and casodex on the reproductive system of the adult male rat. *Acta Endocrinol. (Copenhagen)* 125, 547- 555.
- Chandolia, R.K.; Weinbauer, G.F.; Behre, H.M.and Nieschlag, E. (1991b). Evaluation of a peripherally selective antiandrogen (casodex) as a tool for studying the relationship between testosterone and spermatogenesis in the rat. *J. Steroid Biochem. Mol. Biol*. 38, 367- 375.
- Cheng, C.Y.(2008). Molecular Mechanisms In Spermatogenesis. *Advances in experimental medicine and biology*.;636:1-289.
- Dhar, J.D. and Setty, B.S.(1976).Studies on the physiology and biochemistry of mammalian epididymis :effects of flutamide non steroidal antiandrogen on the epididymis of the rat.*Fertil & Steril*.,27: 566-576.
- Fahim, M. S., Fahim, Z., Harman, J. M.; Clevenger, T. E, Mullins, W., and Hafez, W.S.E (1982). Effect of panax ginseng on testosterone level and Prostate in male rats. *Arch. Androl* 8: 261 - 263.

- Gillis, C.N.(1997). Panax ginseng pharmacology :a nitric oxide link ? Biochem Pharmacol,54:1-8.
- Hafez, E. S. E. (1976). Human semen and fertility regulation in men, editor, Safint louis, C.V, Mosby Company, Kenry kimpton, London.
- Hong, B., J; Hong, J. H.; Nam, K.Y.; and Ahn, T.Y. (2002). A double-blind crossover study evaluating the efficacy of Korean red ginseng in patients with erectile dysfunction: A preliminary Report. J. Urol 168: 2070 – 2073.
- Hwang, S.Y; Kim ,W.J.; Wee, J.J.; Choi, J.S. and Kim, S.K.(2004). Panax ginseng improves survival and sperm quality in guinea pigs exposed to 2,3,7,8-tetrachlorodibenzo- p-dioxin. BJU Int ;94:663-668.
- Iftikar,S.;A.;Hhmed,M.;Aslam,H.M.;Saeed,T.;Arfat,Y.andNozish,G.E.(2014).Evaluation of spermatogenesis in prepubertal albino rats with date palm pollen Supplement .African.J.Pharm.Pharmacol.8(2):59-65.
- Jang, M.; Min, J.; In, J. and Yang, D.(2012).. Effects of Red ginseng extract on the epididymal sperm motility of mice exposed to ethanol. International Journal of Toxicology. ;30(4):435-442.
- Javier, R.; Francisco, M.; Pilar ,G.; Alvaro, S.; Mannel, N. and Carlos, S.U. (2001). Androgen receptor expression in Sertoli cell as a function of seminiferous tubule maturation in the human cryptorchid testis. J. Clin. Endol. Met. 86 (1): 1421-31.
- Johnsen, S.G.(1970). Testicular biopsy score count--a method for registration of spermatogenesis in human testes: normal values and results in 335 hypogonadal males. Hormones;1:2-25.
- Jung, C.H.; Seog, H.M.; Choi, I.W.; Choi, H.D. and Cho, H.Y. (2005). Effects of wild ginseng (Panax ginseng C.A. Meyer) leaves on lipid peroxidation levels and antioxidant enzyme activities in streptozotocin diabetic rats. J. Ethnopharmacol. 98:245-250.
- Kassim ,N.M.; McDonald ,S.W.; Reid, O.; Bennett, K.; Gilmore, D.P. and Payne, A.P. (1997). The effects of pre- and postnatal exposure to the nonsteroidal antiandrogen flutamide on testis descent and morphology in the Albino Swiss rat. J. Anat.,; 190: 577–88.
- Kelce, W.R.; Lambright, C.R.; Gray, L.E.; and Roberts, K.P. (1997). Vinclozolin and p,p'-DDE alter androgen-dependent gene expression: in vivo confirmation of an androgen receptormediated mechanisms. Toxicol Appl Pharmacol.,; 142: 192-200.
- Kim, M.K.; Lee ,J.W.; Lee, K.Y. and Yang, D. (2005). Microbial conversion of major ginsenoside Rb1 to pharmaceutically active minor ginsenoside Rd. J. Microbiol., 43(5): 456-462.
- Kim ,W.; Hwang, S.; Lee, H.; Song, H. and Kim, S.(1999). Panax ginseng protects the testis against 2,3,7, 8-tetrachlorodibenzo-p-dioxin induced testicular damage in guinea pigs. BJU Int ;83:842-849.
- Kim, H. J.; Woo, D.S.; Lee, G. and Kim, J. J., (1998): The relaxation effect of ginseng saponins in rabbit corporal smooth muscle: is it a nitric oxide donor? Br.J. Urol 82: 744 -748.
- Leung.,K.W. and Wong ,A.S.(2013).Ginseng & Male reproductive function. Spermat .3(3):e26391.
- Liu,J.Wangs,s.Liu,H. and Nan,G (1995): stimulatory effect of saponins from panax ginseng on immune function of lymphocytes in the elderly . Mechanisms of Aging &Development. 83(1)43-53.

- Maschio, L. R.; Cordeiro, R. S.; Taboga, S. R. and Goes, R. M. (2010). Short-term antiandrogen flutamide treatment causes structural alterations in somatic cells associated with premature detachment of spermatids in the testis of pubertal and adult guinea pigs. *Reproduction in Domestic Animals*, Vol.45, No.3, pp. 516-524, ISSN 0936-6768.
- McLachlan, R.I.; Wreford, N.G.; O'Donnell, L.; de Kretser, D.M. and Robertson, D.M.(1996). The endocrine regulation of spermatogenesis:independent roles for testosterone and FSH. *J Endocrinol* 1996;148:1-9.
- Meistrich, M.; Wilson, G.and Porter, K.(2003). Restoration of spermatogenesis in DBCP-treated rats by hormone suppression. *Toxicol Sci*; 76(2): 418-426.
- Metzdorff, S.B.; Balgaard, M.; Christensen, S.; Axelstad, M.; Hass, U.; Kiersgaard, M.K.; Scholze, M.; Kortenkamp, A. and Vinggaard ,A.M. (2007): Dysgenesis and histological changes of genitals and perturbations of gene expression in male rats after in utero exposure to anti-androgenmixtures. *Toxicol Sci.*; 98: 87-98.
- Moon, Y. B., and Park, W. H. (1970): Influence of ginseng on the weight of viscera in rats (Korean text). *Korean. J Physiol* 4: 103 - 105.
- Murphy, L.L. and Lee, T.J. (2002). Ginseng, sex behavior, and nitric oxide. *AnnNY Acad Sci.*2002;962:372-377.
- O'Connor, J. C.; Cook, J. C.; Slone, T. W.; Makovec, G. T.; Frame, S. R. and Davis, L. G. (1998). An ongoing validation of a Tier I screening battery for detecting endocrine-active compounds (EACs). *Toxicological Sciences*, Vol.46, No.1, , pp. 45-60, ISSN 1096-6080.
- Ohsako, S.; Kubota, K.; Kurosawa, S.; Takeda, K.; Qing, W.; Ishimura ,R. and Tohyama, C. (2003). Alterations of gene expression in adult male rat testis and pituitary shortly after subacute administration of the antiandrogen flutamide. *J Reprod Dev.*; 49(4): 275-90.
- Park, J.S.; Hwang ,S.Y.; Lee ,.WS.; Yu, K.W.; Paek, K.Y.; Hwang, B.Y. and Han, K. (2006). The Therapeutic Effect of Tissue Cultured Root of Wild Panax ginseng C.A. Mayer on Spermatogenetic Disorder. *Arch. Pharm. Res.* 29(9):800-807.
- Pineda, M. H., and Dooley, M. P. (2003). *Mc Donald's Veterinary Endocrinology and Reproduction*. 5th Ed. Iowa State Press pp 258-261
- Predes, F.S.; Monteiro, C.J.; Tarcízio, A. R.; Paula, A.R.T. and Matta, L.P.S. (2007). Evaluation of Rat Testes Treated With Arctium Lappal: Morphometric Study. *Braz. J. Morphol. Sci.*, 24(2), pp. 112-117.
- Renyong, G. E.; and Hong, P. U. (1986). Effects of ginsenosides and pantocrine on the reproductive endocrine system in male rats. *Journal of Traditional Chinese medicine* 6 (4) 301 -304.
- Sahin ,Y. and Kelestimur, F. (2004). Medical treatment regimens of hirsutism. *Reprod BiomedOnline*; 8(5):538-46.
- Salvati, G.; Genovesi, G.; Marcellini, L.; Paolini, P.; Denuccio, I.; Pepe, M. and M. R.E.(1996). Effects of Panax ginseng C.A. Meyer saponins on male fertility . *Panminerva Med* 38 (4) :249-54.
- Sanchez,Criado,J.E.; Bellido,C., Tebar,M.; Ruiz,A.; and Gonzalez. (1999). The antiprogestin Ru 486 dissociates LH and FSH secretion in male rats: evidence for direct action at the pituitary level. *J. Endocrinology*,160:197-203.
- Sharpe, R.M. (2006). Pathways of endocrine disruption during male sexual differentiation and masculinization. *Best Pract Res Clin Endocrinal Metab.*; 20: 91-110.

- Shetty, G.; Wilson, G. and Huhtaniemi, I.(2000).Gonadotropin releasing hormone analogs and testosterone inhibits the recovery of spermatogenesis in irradiated rats. *Endocrinology*; 141: 1735-1745.
- Solakidi, S.; Psarra, A.M.G.; Nikolaropoulos, S. and Sekeris, C.E.(2005). Estrogen receptors α and β (ER α and ER β) and androgen receptor (AR) in human sperm: localization of ER β and AR in mitochondria of the midpiece. *Hum Reprod.* 20:3481–7. doi: 10.1093/humrep/dei267.
- Thiboutot, D. and Chen, W. (2003). Update and future of hormonal therapy in acne. *Dermatology*; 206(1): 57-67.
- Tsai, S. C.; Chiao, Y.C.; Lu, C.C. and Wang, P. S., (2003): Stimulation of the secretion of luteinizing hormone by ginsenosides Rb1 in male rats. *Chin. J. Physiol* 31; 46 (1): 1-7.
- Viguiier-Martinez, M.C.; Hochereau-de Reviere, M.T. and Perreau, C.,1985). Effects of flutamide or of supplementation with testosterone in prepubertal male rats prenatally treated with busulfan. *Acta Endocrinol. (Copenhagen)* 109, 550-557.
- Vo, T.B.; Eui-Man ,J.; Vu ,H.D.; Yeong-Min, Y.; Kyung-Chul ,C.and Frank, H.Y.(2009). Di-(2 ethylhexyl) phthalate and flutamide alter gene expression in the testis of immature male rats. *Reproductive Biology and Endocrinology*.;7:104.
- Xu, C.J. and Li ,D ,(1998). Pharmacokinetics of flutamide and its metabolite 2-hydroxyflutamide in normal and hepatic injury rats. *Chung Kuo Yao Li Hsueh Pao*; 19: 39–43.
- Yamada,T.;Kunimastys,T.;Sako,I.;Yabushita,S.;Sukata,T.;Okuno,Y;andMastsuo,M.(2000).Comparative evaluation of a 5-day Hershberger assay utilizing mature male rats and a pubertal male assay for detection of flutamide's antiandrogenic activity.*Toxicol.Sci.*53:289-296.
- Yamamoto, M.; Kumagai, A.; and Yamamura, Y. (1977). Stimulatory effect of Panax ginseng Principles on DNA and protein Synthesis in rat testes. *Arzneimittel - forschung* 27 (7): 1404 - 1405.
- Yun, T.K., (2001). Brief introduction of Panax ginseng. *C.A Meyer.J Korean Med Sci*:16(supp1):S3-5.
- Yoshimura, H.; Kimura, N. and Sugiura, K. (1998). Preventive effects of various ginseng saponins on the development of copulatory disorder induced by prolonged individual housing in male mice. *Methods Find EXP Clin Pharmacol* 20 (1): 59 – 64.
- Zhang, M.; Latham, D.E.; Delaney ,M.A. and Chakravarti, A ,(2005). Survivin mediates resistance to antiandrogen therapy in prostate cancer. *Oncogene*.; 24(15):2474-82.