

The effect of Nandrolone Decanoate on the Epididymis Weight and it's Histological Structure in Adult Male Mice

Shiama Ahmed Rahim

College of science for women - Univ. of Babylon

Abstract

This study aimed to identify the effect of different doses of nandrolone decanoate on epididymis weight and histological changes in epididymis in adult male mice. These males were injected subcutaneously (in distal region of femur) with (50, 100 mg/kg body weight) every 2 days for 30 days.

Histological section examination shows reduction of the diameter of epididymal tubules, the diameter of lumen of epididymal and the height of epithelial cells in (caput & cauda) of epididymis and increase the percentage of damage in epididymal caput tubules for treatment group in comparing with control group which injected with normal saline and revealed histopathological changes includes accumulation of the edematous fluid inside the tubules, interstitial spaces between tubules, degeneration of epithelial epididymis and absence of tubules from sperm.

nandrolone decanoate

()

/

()

Introduction

Anabolic- androgen steroid (AASs) are synthetic derivatives of testosterone and are important pharmacologically for treatment of growth deficiency, anemia, sexual dysfunction of chronic renal failure and osteoporosis (Doust *et al.*, 2007; Soliman & Oreopoulos, 1994) and combination of these compounds used by athletes and muscle builders with the sole purpose of improving performance, ability, appearance or muscle mass (Shittu *et al.*, 2006).

Some researchers reported that AASs have negative health consequences including endocrine, hepatic, cardiovascular and behavioral disturbance (Wood, 2004; Clerico *et al.*, 1981). AASs compound greatly affect the male pituitary-gonadal axis, hypogonadism can be induced characterized by decreased serum testosterone concentrations, testicular atrophy and impaired spermatogenesis (Clark *et al.*, 1997; Wroblewska, 1997).

Torres-Colleja (2001) reported that sperm count and normal sperm morphology were significantly reduced in AASs abuser bodybuilder.

Mesbah *et al.* (2007) showed that administration of AASs caused degenerated change on some testicular structures, this adverse effect of AASs is due to its including to circulating testosterone elevation to the range likely to be used in hormonal male contraception (Daryl *et al.*, 2004).

Within the epididymis, contraceptive effects could be mediated on the spermatozoa directly via the epididymal epithelium and epididymal fluids composition or on epididymal peritubular muscle, all three of these aspects of epididymal function have been investigated as potential contraceptive targets (Anderson and Baird, 2002). The objective of this study to assess the effect of

AASs(Nandrolone Decanoate) on histological changes of epididymis and it's weight in adult male albino mice.

Material and Methods

were grouped randomized into three Fifteen adult male albino mice (balb/C) group weighting 18.4g-22.8g

Tow groups injected subcutaneously (in distled region of femur) with 50 and 100mg \kg body weight nandrolone decanoate (NA)every 2 days for 30 days while control group was injected with 0.9 %normal sline .the animales were housed at 22-25C with 12-h light \dark cycle .after30 days fom injection NA the animales were sacrificed and their epididymis removed and weighted by sensitive digital balance .the organs weight to body weight ratio were then calculated as mg\100g of body weight.

The epididymis were fixed by formaline 10% for histological sectioning (Presnell&Schreibman,1997), then the sections were examined by using compouned microscope and the measurments were acording by using ocular micrometer after calibrated with stage micrometer .

Twenty readings for the diameter of epididymal tubules (caput & cauda),twenty readings for the diameter of epididymis lumen (caput & cauda) and twenty readings for the hight of epithelial cells (caput & cauda) was measured for each animal.

Percentage of damage of caput epididymal tubules was calculated as previously described in (Balash etal , 1987) according to the follwing relesionship :

$$\text{Percentage of damage} = \frac{\text{number of damage tubules}}{\text{Total number of tubules}} \times 100$$

photographing was achieved by using Olympus model DB2-N180 microscope which provided by computer type LG. complete randomized design (CRD)F-test was applied and followed by LSD test for analysising the results (Al-Rawi,2000)

Results

The weight of epididymis was a significantly reduced in experimental groups compared with those of the control as showing in figure (1).

The treated groups showed significantly decrease($p<0.01$),($p<0.05$) in the means of diameter of epididymal tubules in caput and means of epithelial cell height in caput that compared to control that showing in figure(2),(4).

In this study , showed an insignificantly decrease in the mean of diameter epididymal tubules (cauda),mean of epithelial cell height (cauda) and mean of diameter of epididymal lumen (cauda) in treated animals as compared to control as shown in figure(3),(5),(7) Through the study of histological sections showed an insignificantly decreased in the means of diameter epididymal tubules ,means of epithelial cell height (in cauda) and means of diameter of epididymal lumen in(caput for 100mg\kg group and cauda) as compared to control as shown in figure(3,5,6,7)

In the present study , significant increase ($p<0.01$)in the mean diameter of epididymal lumen caput for experimental mice (which injected with 50mg\kg)as shown in figure (6). In addition to this findings our study showed that reduced content of spermatozoa in the lumen of epididymal tubules in experimental mice was showed in picture (4,5,6,7,8,9,10,11), Our study also showed accumulation of the odeamtous fluid inside epididymal tubules was showed picture (5,9,11), The results of this study

reported the treatment of nandrolone decanoate caused increase percentage of damage in epididymal caput tubules.

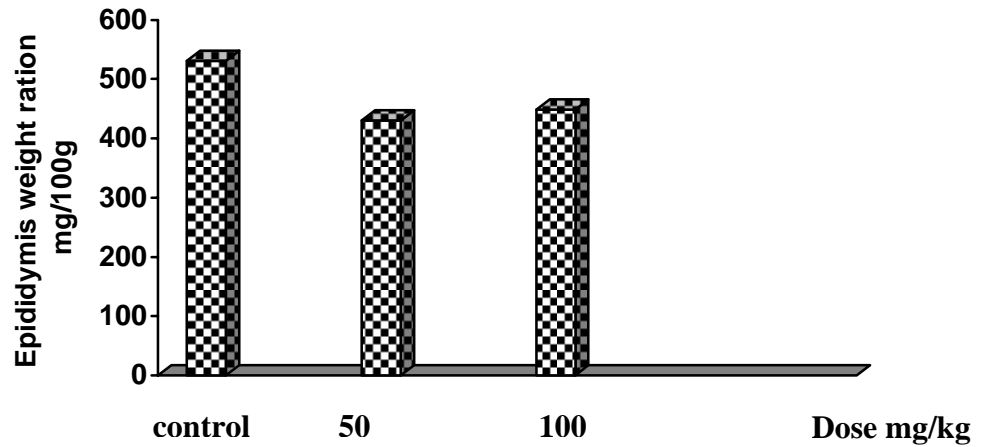


Figure (1) epididymis weight ration (mg/ 100 gm) of body weight) in male mice which treated in different doses of nandrolone decanoate.

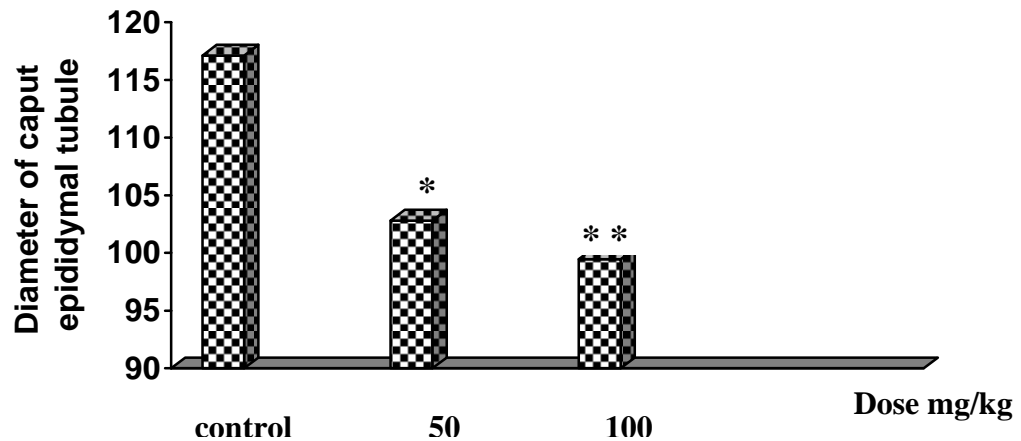


Figure (2) Diameter of caput epididymal tubules (mictometer) in male mice which treated in different doses of nandrolone decanoate.

* significant decrease at (0.05) level .

** significant decrease at (P<0.01) level .

6.52 * L.S.D=

9.82* * L.S.D.=

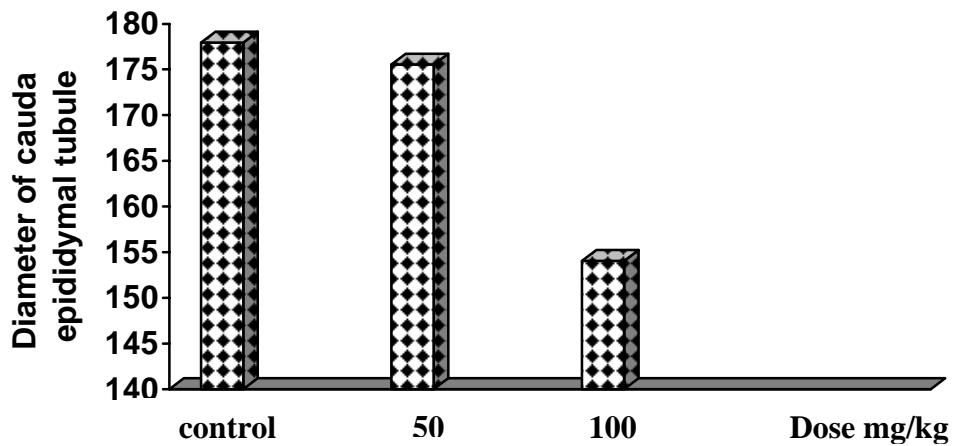


Figure (3) Diameter of cauda epididymal tubules (mictrometer) in male mice which treated in different doses of nandrolone decanoate .

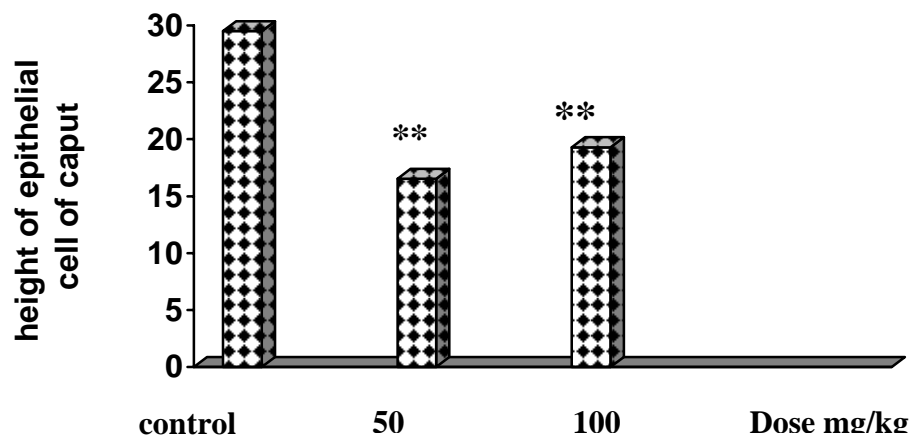


Figure (4) height of epithelial cell of caput epididymal tubules (mictrometer) in male mice which treated in different doses of nandrolone decanoate .

** significant decrease at ($p < 0.01$) level .

L.S.D.=7.81

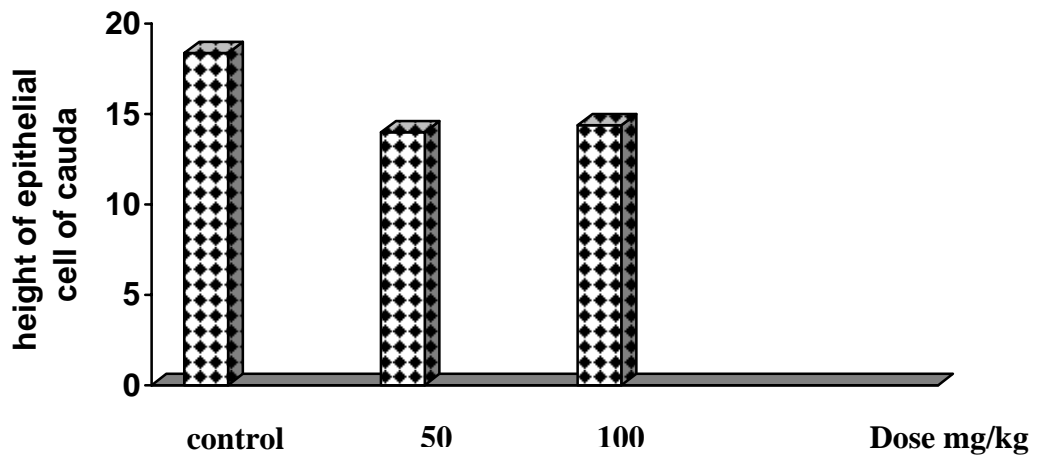


Figure (5) height of epithelial cell of cauda epididymal tubules (micrometer) in male mouse which treated in different doses of nandrolone decanoate.

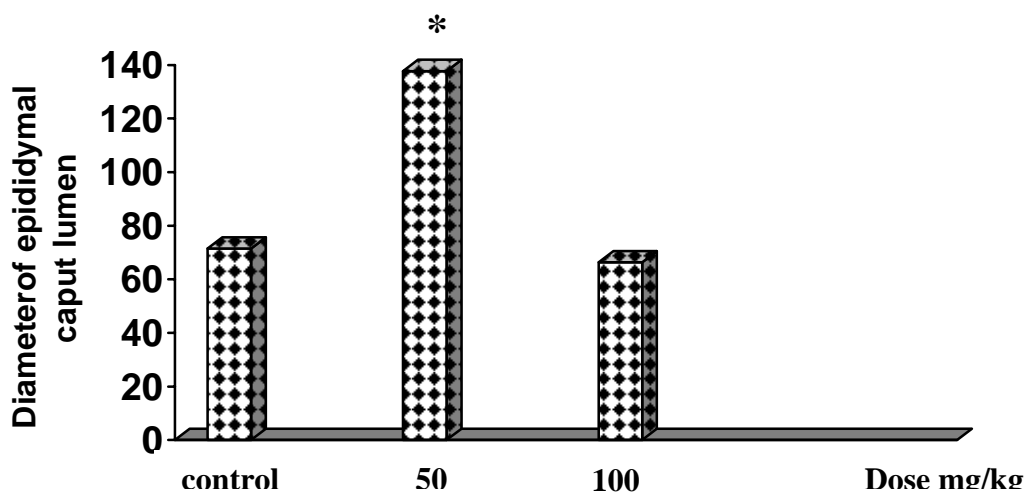


Figure (6) Diameter of epididymal caput lumen (micrometer) in male mice which treated in different doses of nandrolone decanoate .

** significant decrease at ($p < 0.01$) level .

L.S.D.=7.032

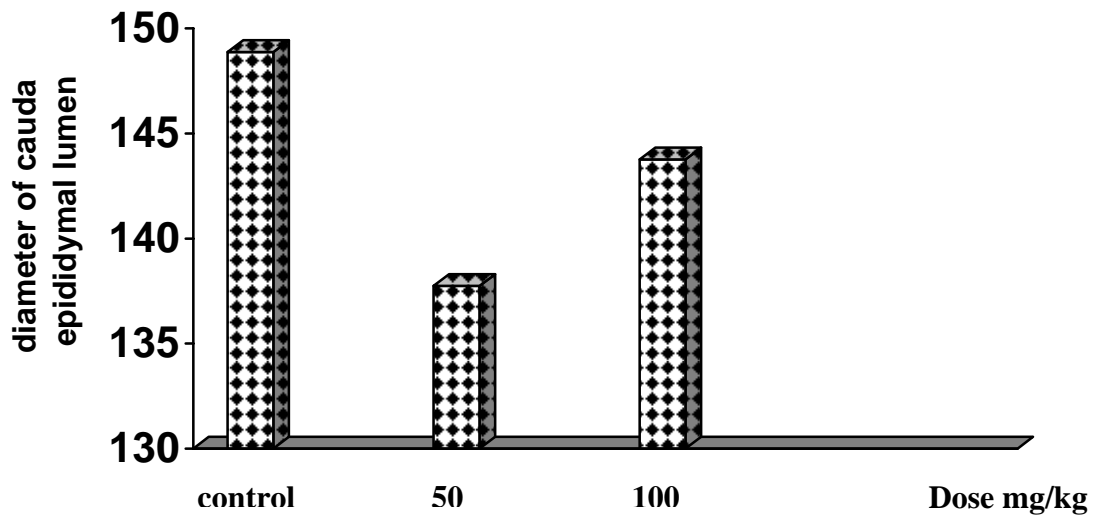


Figure (7) Diameter of cauda epididymal lumen(mictometer) in male mice which treated in different doses of nandrolone decanoate .

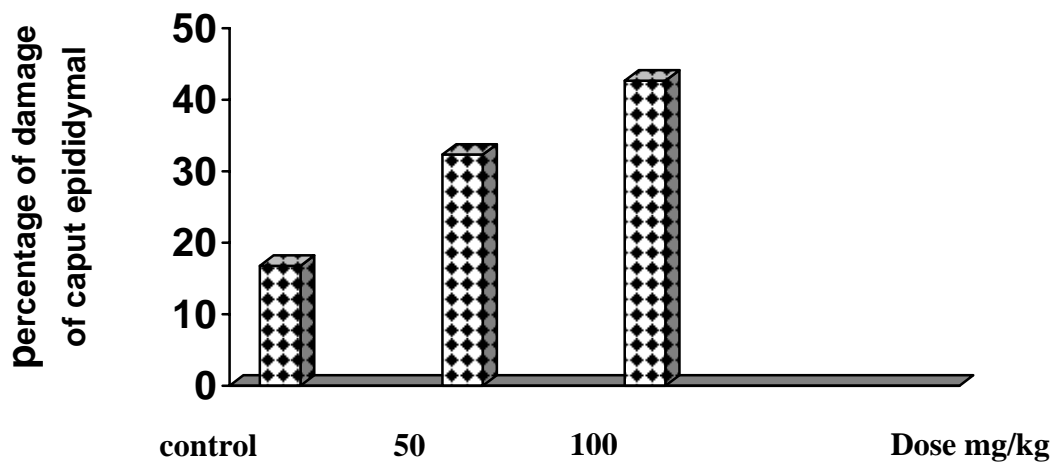
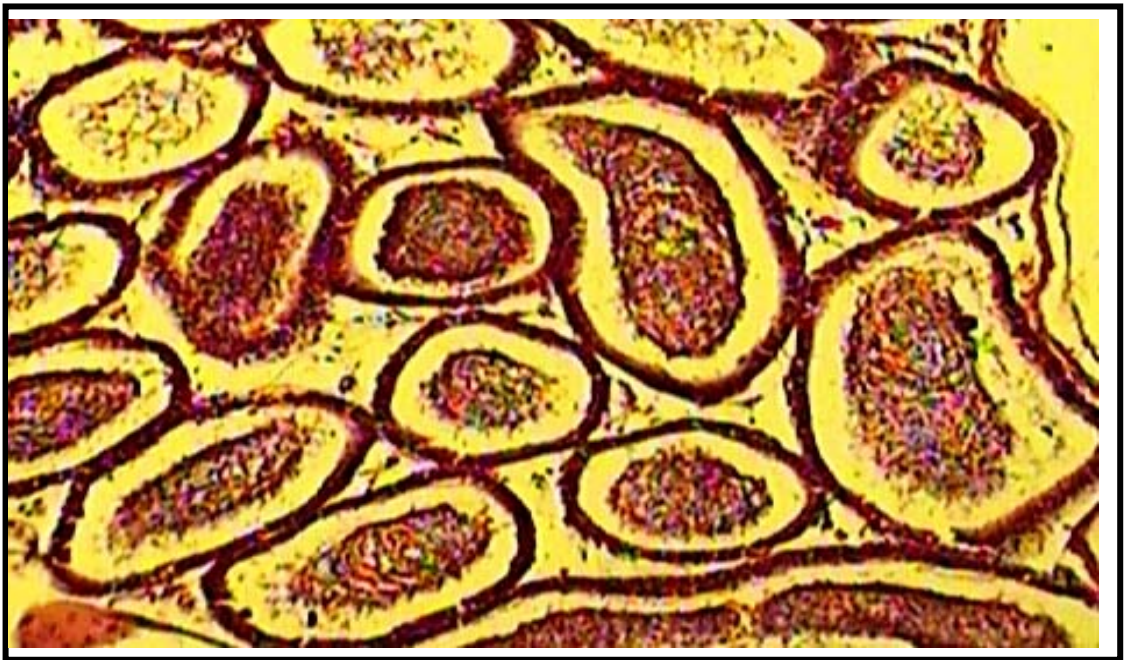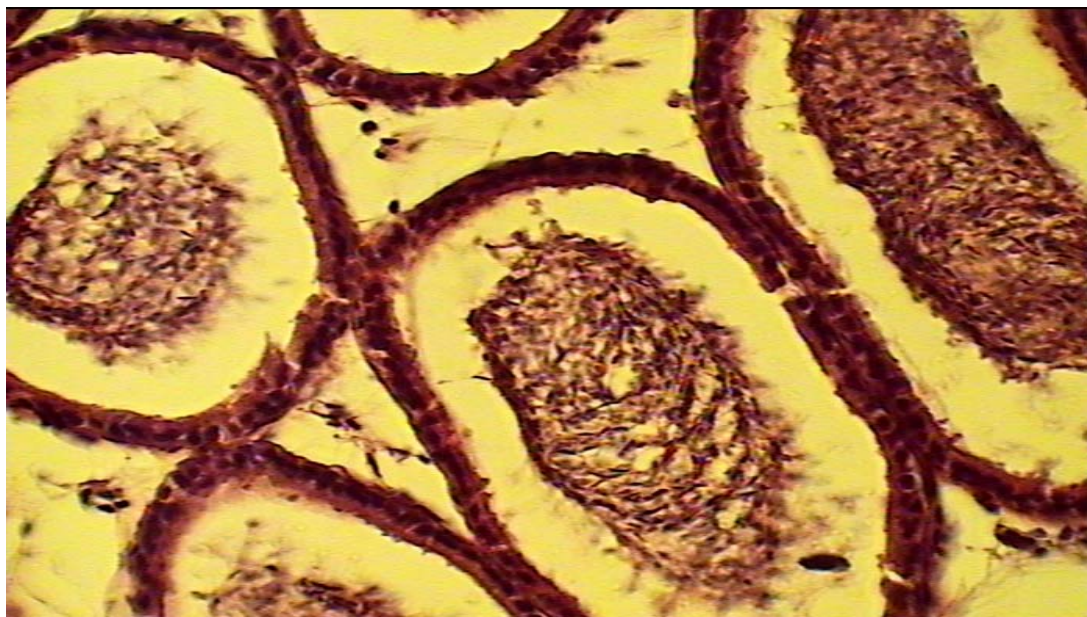


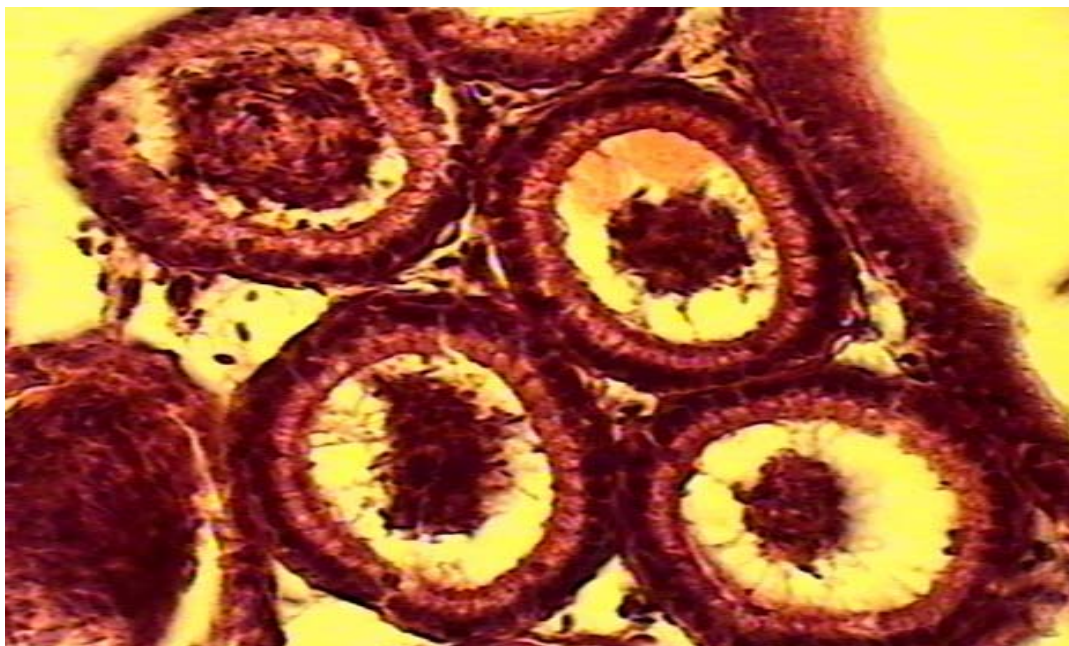
Figure (8) percentage of damage of caput epididymal in male mice which treated in different doses of nandrolone decanoate .



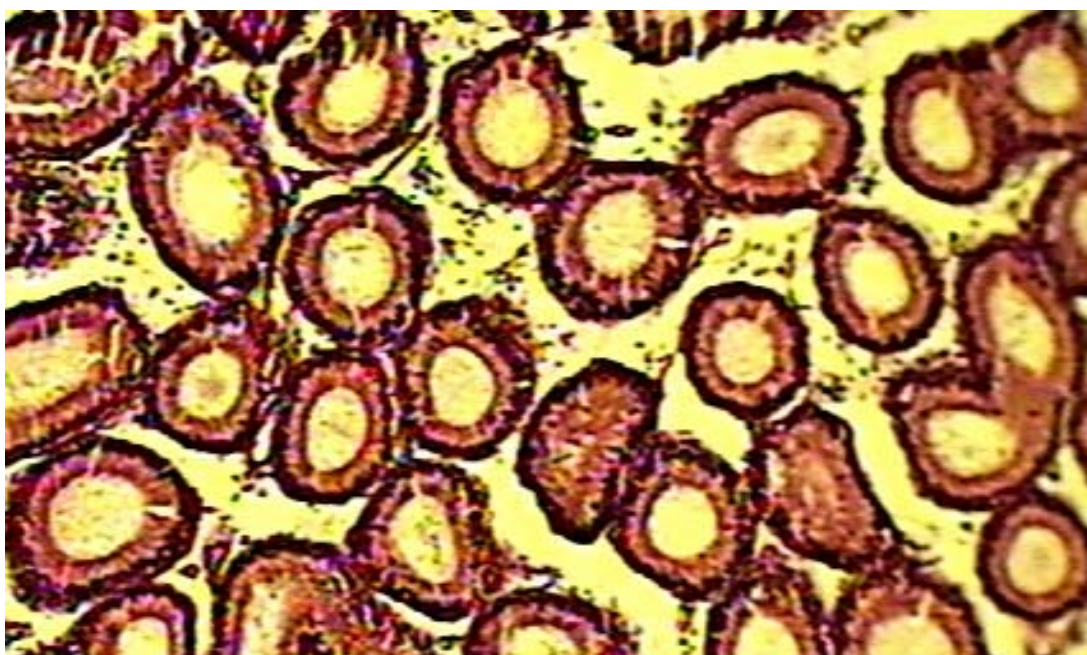
picture (1):Cross-section (10x)for cauda epididymis mice(control group)show:normal view for epididymal tubules.



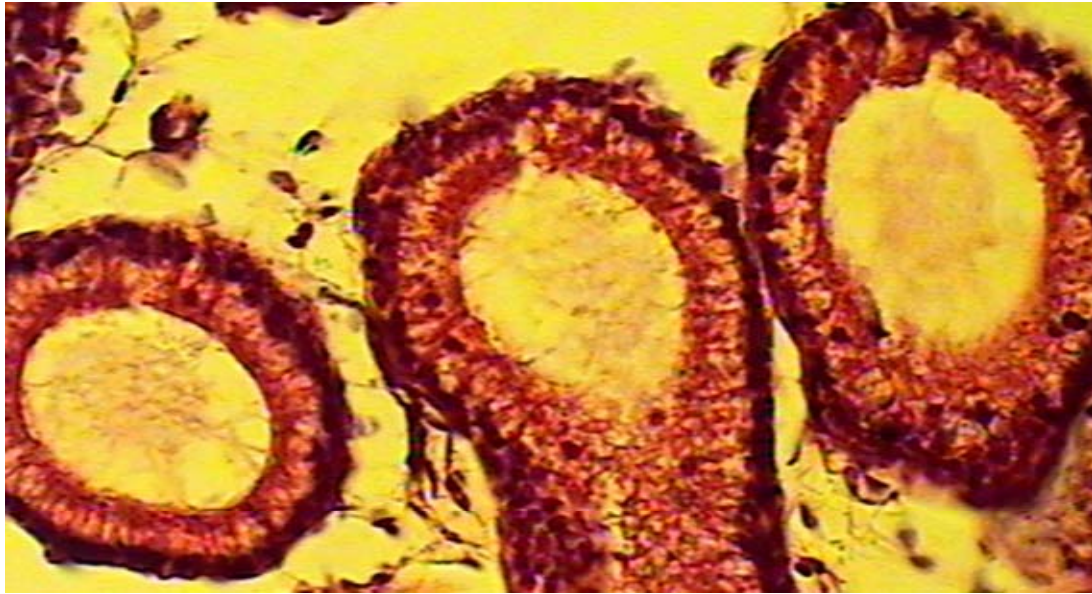picture (2):Cross-section (40x)for cauda epididymis mice(control group)show: normal view for epididymal tubules



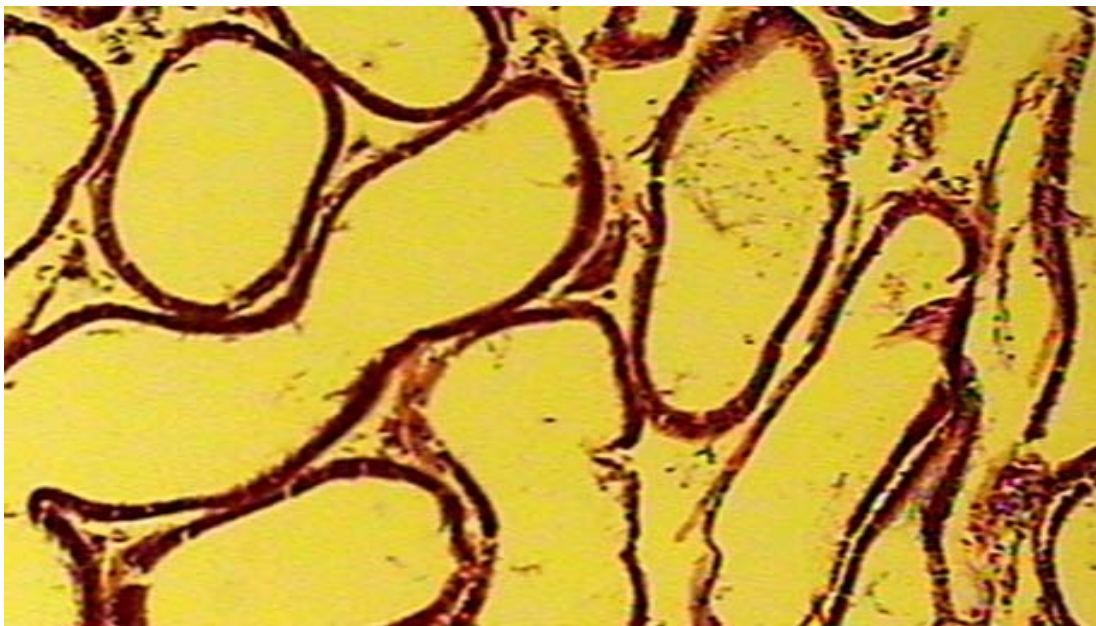
picture (3):Cross-section (40x)for caput epididymis mice(control group)show: normal view for epididymal tubules.



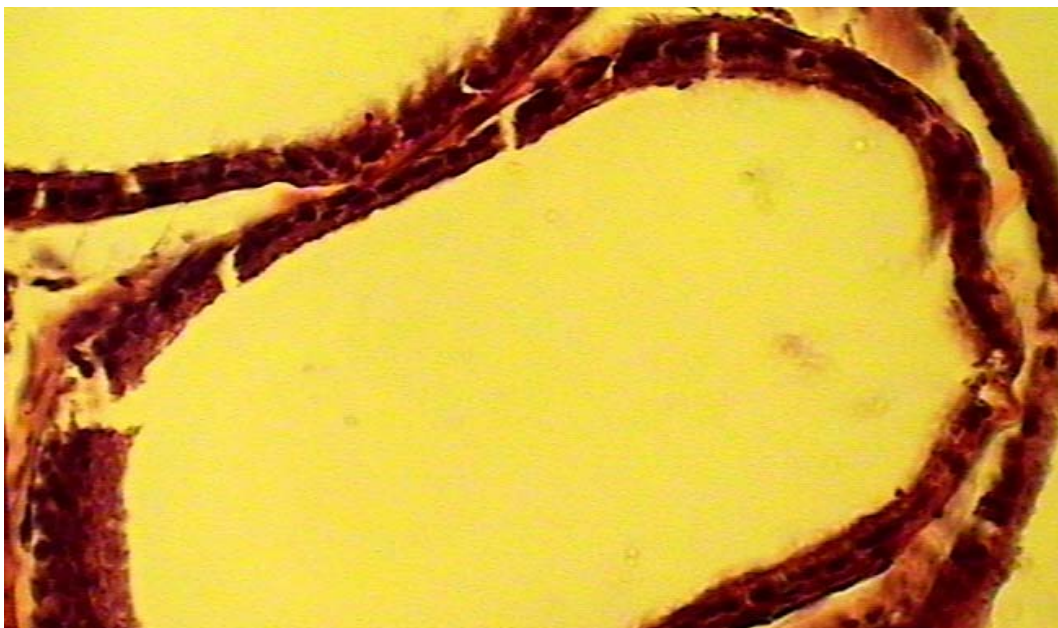
Picture (4):Cross-section (10x)for caput epididymis mice(100mg/kg)show: absence of sperm from tubules, damage in tubules walls, interstitial space between tubules.



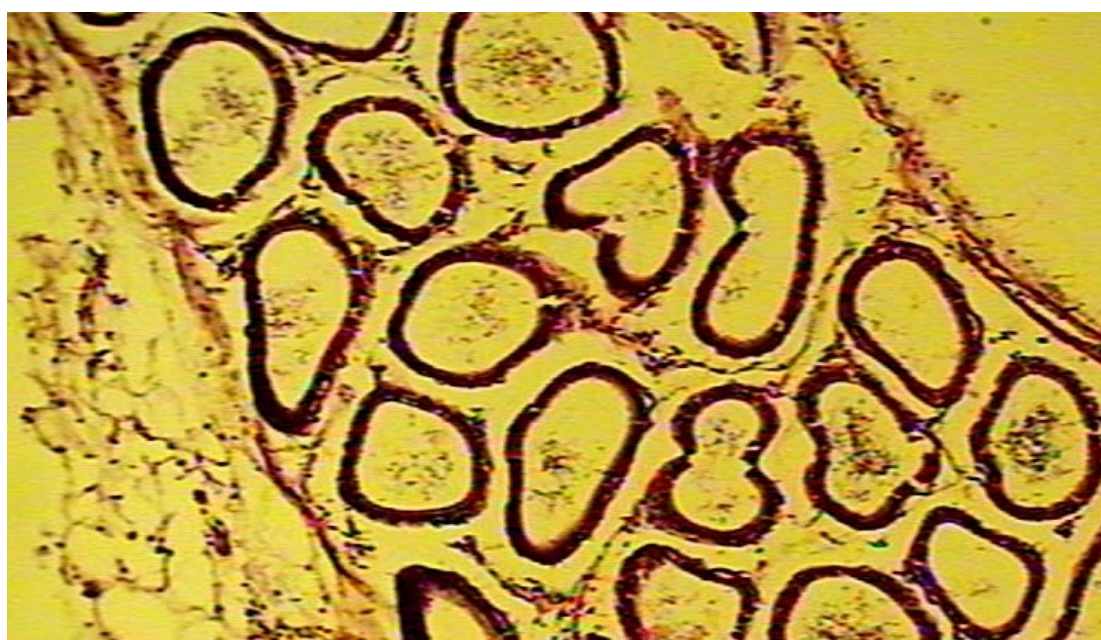
Picture (5):Cross-section (40x)for caput epididymis mice (100mg/kg)show:absence of sperm from tubules, ,interstitial space between tubulesand accumulation odematous fluids inside tubules.



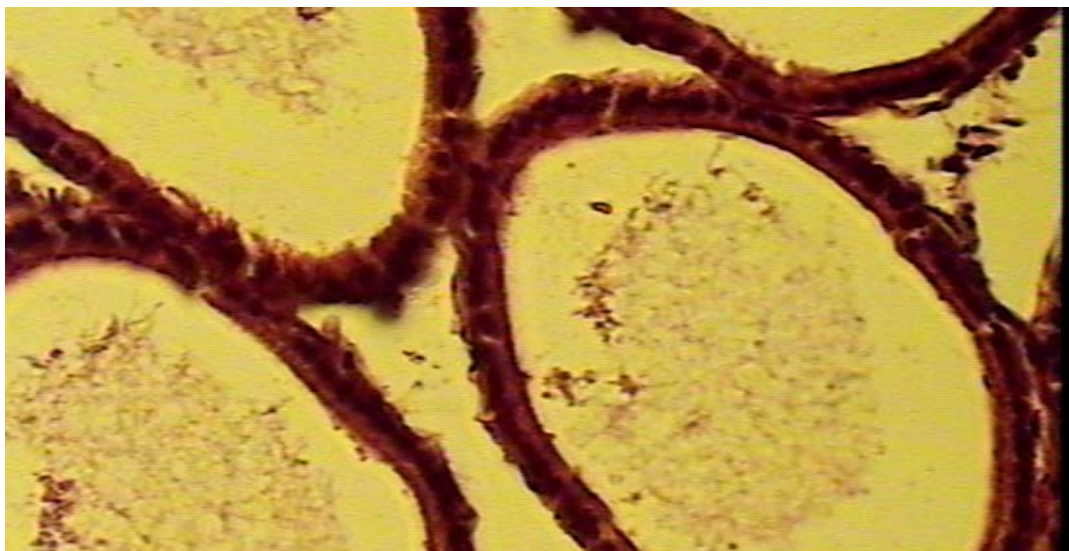
Picture (6):Cross-section (10x)for cauda epididymis mice (100mg/kg)show: absence of sperm from tubules, damage in tubules wall.



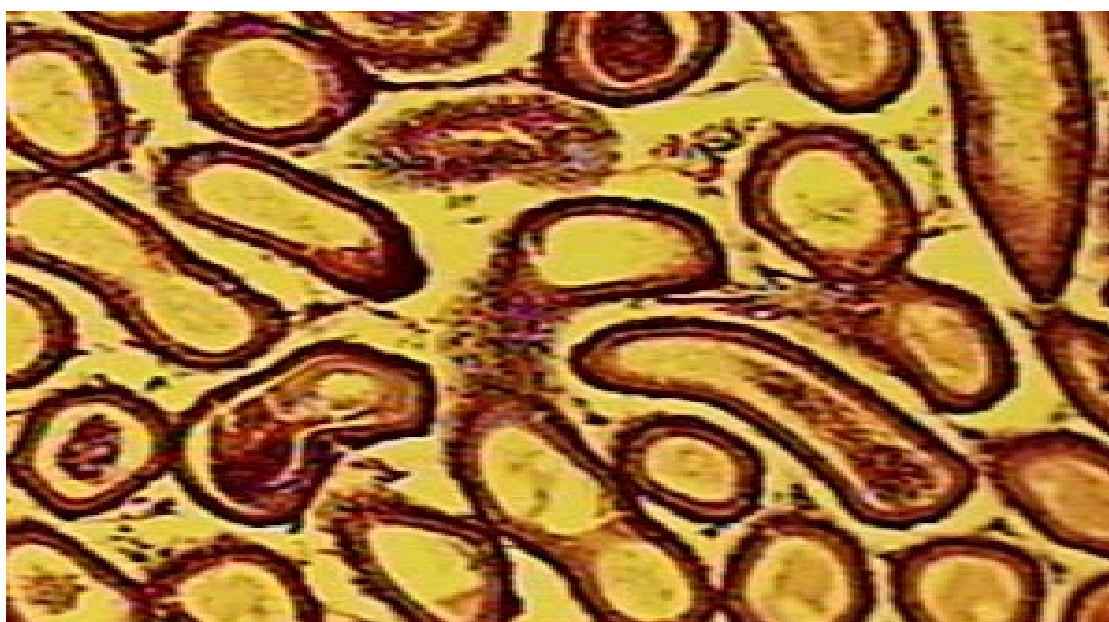
Picture (7):Cross-section (40x)for cauda epididymis mice (100mg/kg)show: absence of sperm from tubules, damage in tubules walls.



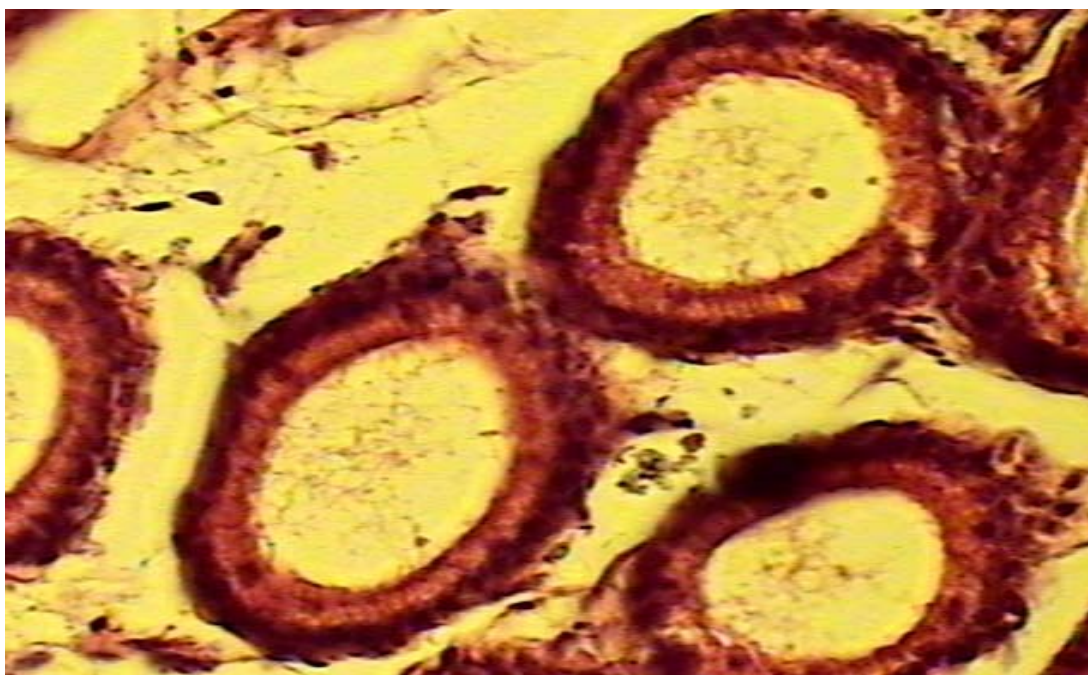Picture (8):Cross-section (10x)for cauda epididymis mice (50mg/kg)show: absence of sperm from tubules, damage in tubules walls, interstitial space between tubules and damage interstitial tissue.



Picture (9):Cross-section (40x)for cauda epididymis mice (50mg/kg)show: absence of sperm from tubules, damage in tubules walls and accumulation edematous fluids inside tubules.



Picture (10):Cross-section (10x)for caput epididymis mice (50mg/kg)show: absence of sperm from tubules, accumulation edematous fluids inside tubules and interstitial space between tubules



Picture (11):Cross-section (40x)for caput epididymis mice (50mg/kg)show: absence of sperm from tubules, accumulation oedematous fluids inside tubules and interstitial space between tubules.

References

- . ()
F2 α . ()
- Anderson ,R.A. and Baird ,D.T.(2002).Male contraception .Endocrine Review. 23(6):735-762.
- Balash, K.J; Al-Omar, M.A.and Abdul Latif ,B.M.(1987).Effect of chordane on testicular tissue of swiss mice ,Bull Environ contam .Toxicol,39:434-424.
- Clark ,A.S.; Harrold, E.V.; Fast, A.S.1997. Anabolic-androgenic steroid on the sexual behavior of intact male rats. Horm Behav; 31: 35_46.
- Clerico, A, Ferdehini, M.; Palombo, C.; Leoncini,R.(1981). Effects of anabolic treatment on the serum levels of gonadotropins ,testosterone, prolactin ,thyroid hormones and myoglobin of male athletes under physical training .J Nucl Med Allied Sci.25:79-88.
- Combaire, F.H.(1994).Male contraception :hormonal, mechanical and other. Human. Reproduction.9(4):586-590.
- Darly, B.; Archer,J.; Frederick,C.W.(2004). Effect of testosterone on Mood, Aggression and sexual behavior in yang men :adouble –blind ,placebo – controlled, crossover study .Clinical Endocrinology &Metabolism .89(6):2837-2845.
- Dohle,.G.R.;Smit,M.;Weber,R.F.(2003).Androgen and male fertility .World J Urol . 21:341-5.
- Doust, SK.; Noorafshan ,A.; Ardekani ,FM.and Mirkhani, H. (2007). The reversibility of sperm quality after discontinuing nandrolone decanoate in adult male .Asian J Androl 9(2):235-239.

- Grokkett,B.H.; Ahmed,N.; Warren,D.W.(1992).The effect of an anabolic steroid oxandrolone on reproductive development in the male rat .Acta Endocrinol .126:173-8.
- Itoh,M.; Miyamoto,K.; Satriotomo,I.and Takeuchi,Y.(1999).Spermatic granulomata are experimentally induced in epididymides of mice recelving high-dose testosterone implants .I.Alight-microscopical study .J.Androl.,20:551-558.
- Lukeman,SH.A.J.;Remilekum,SH.K.;Abraham,O.A.A.andAdetokunbo,T.A.(2009).M esterolone (proviron)induces low sperm quality with reduction in adult male Sprague dawley rats testis .Sci Research and Essay. 4 (4):320-327.
- Mauro ,G.DIP.(1998)Anabolic steroid side effects :facts,fiction and Treatment ,p. 47.in:Stenverti ,s.Drop Wouter J,DeWaal,Sabine MPF,De Muinck K-S.Sex Steroid Treatment of constitutionally tall stature .Endocrine Reviews,,19(5):540-558.
- Mesbah ,S.F. ; Shokri ,S.;Karbaly-Doust,H.(2007).The effect of nandrolone decanoate on the body , testis and epididymis weight and semen parameters in adult male rats .Iran J Med Sci June. 32:2:93.
- O'sullivan,A.J.;Kennedy.M.C.;Casey.J.H.(2000).Anabolic androgenic steriodes:medical assessment of present ,past and potential users .Med J Aust.173:323-7.
- Presnell,J.K.and Schreibman , M.P.(1997).Humason's animal tissue techniques,5th edu.,John Hopkine Univ.Press,Balfimore.
- Pujol,A.& Bayard,F.((1979).Androgen receptors in the rat epididymis and their hormonal control.J.Reprod.Fert.,56:217-222.
- Ratna Kumar,B.V.;Setty,B.S.and Shipstone,A.C.(1988).Ultrastructural changes in the principle cells of epididymis of adult rhesus monkey(*Macaca mulatto*) after castration and androgen replacement therapy .Acta Eur.Fertil.,19:287-294.
- Setty,B.S.;Riar,S.S.and Kar,A.B.(1977).Androgenic control of the epididymal function in the rhesus monkey and rabbit .Fertil.Steril.
- Shittu,LAJ,Sittu,RK,Osinubi,AAA,AshiruOA.(2006).Stereological evidences of epithelial hypoplasia of seminiferous tubules induced by mesterolone in adult Sprague-Dawley rats .Afr.Endocrinol.Metab.7:21-25.
- Soliman ,G and Oreopoules,DG.(1994).Anabolic steroidsand malnutritionin chronic renal failure .International Society for Peritoneal Dialysis.14(4):362-365.
- Sriraman, V.;Sairam,M.R.;Jagannadha,r.a.(2004).Evaluation of relative role of LHand FSH in restoration of spermatogenesis using ethanedimethylsulphonate-treated adult rats .Reprod Biomed Online. 8:167-74.
- Torres –Calleja , J.;Gonzalez-Unzaga,M.,Decelis,R.(2001).Effect of androgenic anabolic steriodes on sperm quality and serum hormone levels in adult male body bluilder.Life Sciences .68:1769-74.
- Turner,P.C.& Johnson ,A.D.(1971).Epididymal lipid of the rat with and without testicular contribution .J.Reprod.Fert.,27:249-255
- Turner,T.T;Jones,C.E.;Howards,S.S.;Ewing,L.L.;Zegeye,B.and Gunsalus,G.L.(1984). On the androgen microenviroment of maturing spermatozoa .Endocrinology,115:1925-1932.
- Van-dekerckhove,P.;Liford,R.;Vail,A.;Huges,E.(2000).Androgen versus placebo or no treatment for idiopathic Oligo/asthenospermia , Cochrane database
- Wood, RI.(2004).Rein forcing aspect of androgens.Physiol Behav .83:279-89.
- Wroblewska, A.M. 1997.Androgenic-anabolic steroids and body dysmorphia in young men. J Psychosom Res; 42: 225_34.