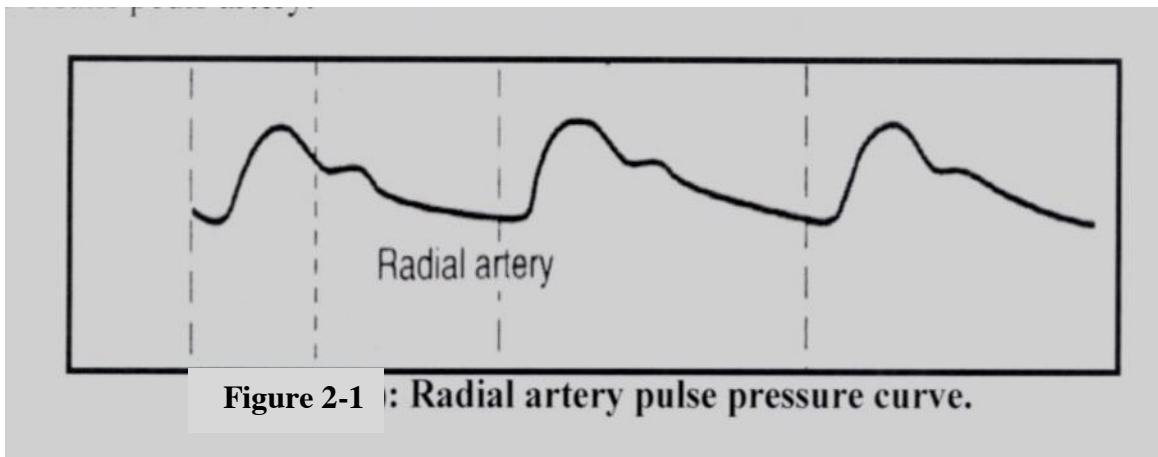


2- The arterial pulses

Introduction:

The arterial pulse is the rhythmic expansion of pressure waves along the walls of the arteries which is produced during each systole of cardiac cycle. It is one of the vital signs that must be checked with general examination. It gives information regarding function of cardiovascular system.

The strength of the pulse is determined by pulse pressure. **The pulse pressure is the difference between systolic & diastolic pressure. See figure (2-1).**



The presence or absence of main peripheral arterial pulses (radial, brachial, carotid, popliteal, posterior tibial and dorsalis pedis) should be noted. The arterial pulses are detected by gently compressing the vessel against some firm structure usually bones by tip of middle three fingers of hand. The distal finger is used for empty vessel, the proximal finger is used for palpate pulse, third middle finger is used for palpate the condition of vessel wall.

The following observation should be checked in pulsation:-

1-

Rate of pulse:-

It is stated as number of pulses per minute. Count the pulses for not less than half minute. Normal range for pulse in adult is 60-100 beat per minute(bpm). When the pulse rate is >100 bpm the condition is called tachycardia. **Causes of sinus tachycardia include exercise, pain, anxiety, fever and hyperthyroidism. When the pulse is < 60 bpm the condition is called bradycardia. Causes of sinus bradycardia include sleep, athletic training and hypothyroidism.**

2- Rhythm:-

Normal rhythm is called sinus rhythm and it is usually regular because it originates from SA node but in young, children and athletes, subjects may show variation in rate beats during respiration (increase with inspiration and decrease at the

beginning of expiration). Abnormal rhythm of pulse is called arrhythmia. Examples of arrhythmia include sinus arrhythmia, atrial fibrillation, ectopic beats, and heart block.

3- **Volume of pulse:** -

It is degree of expansion. It gives idea about the stroke volume. It increases in conditions that causes vasodilatation. Physiological causes of increased pulse volume include exercise, emotion, pregnancy, fever, thyrotoxicosis and anemia. Examples of pathological causes of increased pulse volume is aortic regurgitation while pulse volume decreases in heart failure and peripheral vascular disease

4- **Character:-** Slow rising pulse occurs in aortic stenosis while collapsing pulse occurs in aortic regurgitation.

5- **The condition of vessel wall:-**

In young adult, the wall is not felt while in old people it is like cord due to atherosclerosis. With advancing age, the arteries become more rigid.

Typical pulse in healthy young adult is (60 – 100 beats / minute), regular in rhythm, normal volume, no collapsing and the arterial wall is just palpable.

Objective:

To examine peripheral arterial pulses.

Materials:

Subject.

Procedures:

Figure 2-2 shows the commonly used sites for arterial pulse detection.

1- **The radial artery pulse:-**

It is best felt just lateral to the tendon of flexor carpi radialis by pressing against radius bone head. The three fingers of examiner's hand are used for feeling the pulse. Slight pressure is exerted on the radial artery against the radius by the finger. This will make the pulsation more evident and easy felt by index finger. Radial pulse is particularly useful in assessing rate and rhythm of pulse (figure 2-3a).

2-**The brachial artery pulse:-**

It is best felt when artery is compressed by thumb (right thumb for right hand) against humerus just above the antecubital fossa, medial to biceps tendon. It is a better indicator of pulse volume and character than radial pulse because it is larger artery (figure 2-3b).

3- The carotid artery pulse:-

With the patient is lying on bed, pulse is best detected by pressing thumb gently carotid artery between the larynx and the anterior border of sternomastoid muscle. The two carotid pulses should never be examined together because of danger of reducing the cerebral arterial supply. Move stethoscope over carotid artery to auscultate for bruit (figure 2-3c).

4- The femoral artery pulse:-

It is best detected at halfway between the pubic tubercle and the anterior superior iliac spine at the level of the inguinal ligament (figure 2-3d).

5- The popliteal artery pulse:-

It is best detected by pressing the popliteal artery in middle of popliteal fossa while the subject lies on his face, the knee is slightly flexed (figure 2-3e).

6- Posterior tibial artery pulse:-

The posterior tibial artery is found 1 cm behind the medial malleolus of the tibia (figure 2-3f).

7-The dorsalis pedis artery pulse: -

It is best felt by compressed artery against the tarsal bones at the posterior of foot between the medial and lateral malleolus (figure 2-g).

Automatic measurement of pulse

Pulse oximeter is non-invasive devices used to measure a patient's blood-oxygen saturation level and pulse rate. It is usually attached to the tip of index finger or wrist and can be wired or wireless. It is used to monitor pulse in hospitals and various medical settings (figure 2-4).

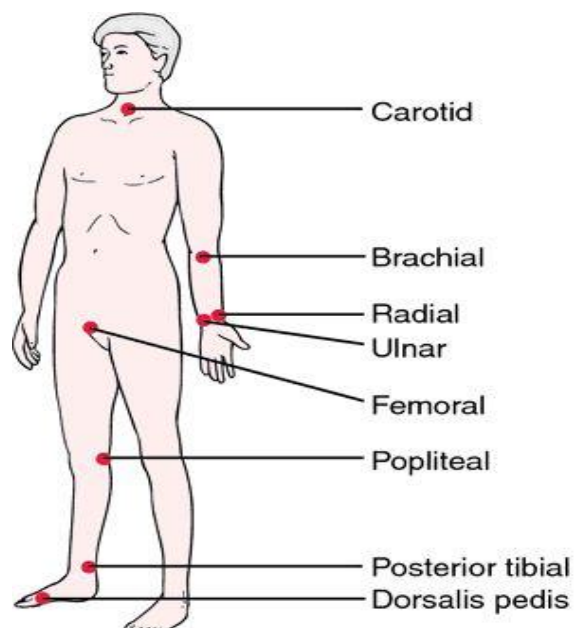
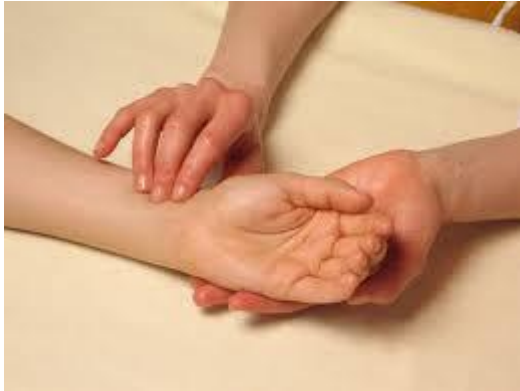
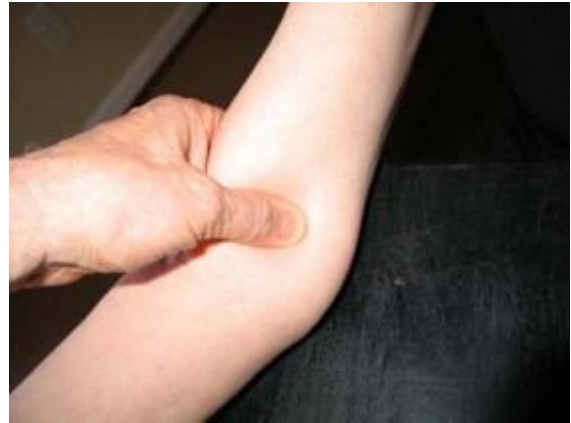
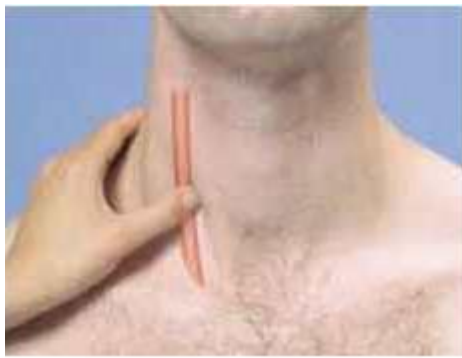Figure 2-2: common sites of arterial pulse detection



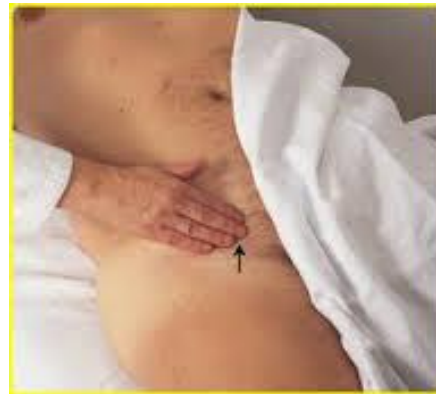a: radial artery pulse



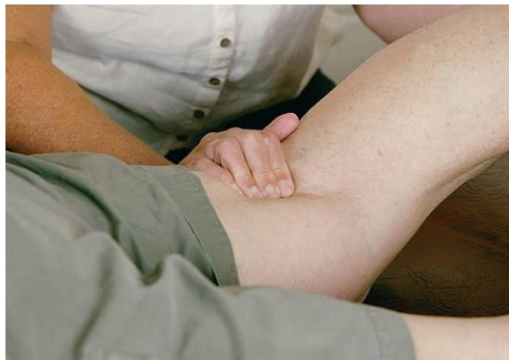b- brachial artery pulse



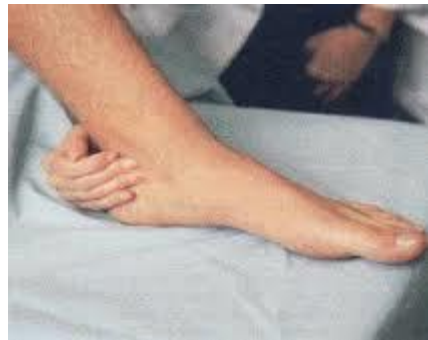c: carotid artery pulse



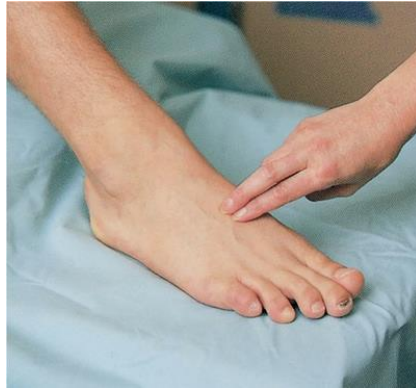d: femoral artery pulse



e: popliteal artery pulse



f: posterior tibial artery pulse



g: dorsalis pedis artery pulse

figure 2-3: demonstrate the sites of arterial pulse detection

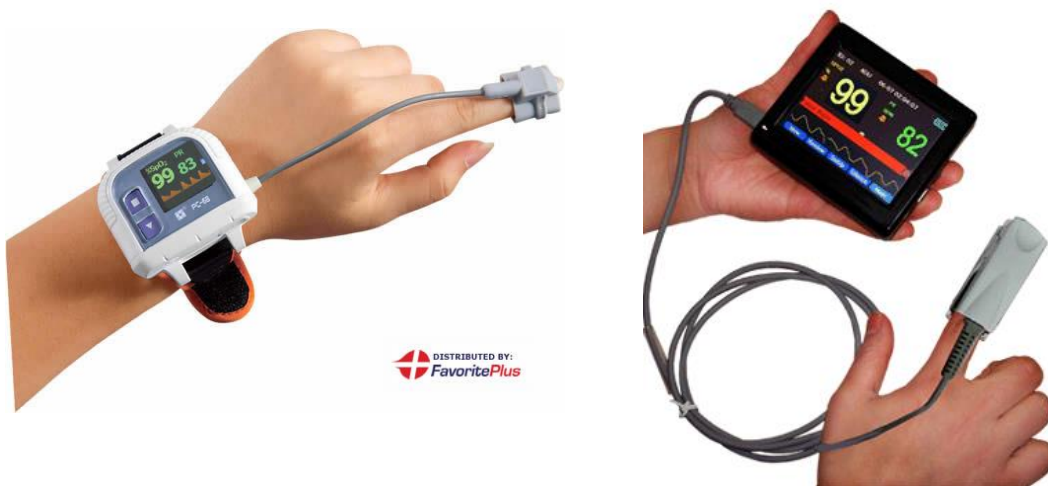


Figure 2-4: different types of pulse oximeter