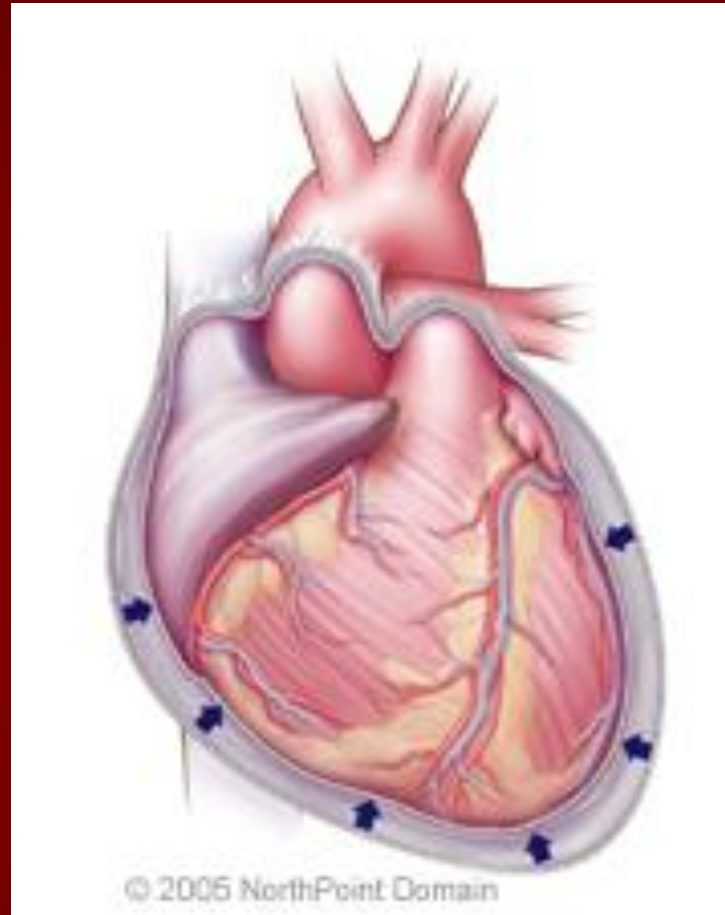


VALVULAR HEART DISEASE



Goals and Objectives

- Discuss the common etiologies of valvular stenosis and regurgitation.
- Recognize the signs and symptoms of severe valvular stenosis and regurgitation
- Be able to quickly identify and treat acute mitral and aortic regurgitation
- Identify patients who should be referred for surgical replacement of their valves

Overview

- Aortic Stenosis
- Mitral Stenosis
- Aortic Regurgitation
 - Acute and Chronic
- Mitral Regurgitation
 - Acute and Chronic

Aortic Stenosis

Aortic Stenosis Overview:

- **Normal Aortic Valve Area:** 3-4 cm²
- **Symptoms:** Occur when valve area is 1/4th of normal area.
- **Types:**
 - Supravalvular
 - Subvalvular
 - **Valvular**

Etiology of Aortic Stenosis

- **Congenital**
- **Rheumatic**
- **Degenerative/Calcific**

Patients under 70: >50% have a congenital cause

Patients over 70: 50% due to degenerative

TABLE 12-2**Etiology of AS****Etiology****Notes****Congenital**

- 1. Congenital aortic stenosis**
- 2. Congenital bicuspid valve**

Can occur with unicuspid, bicuspid, tricuspid valve
Commonly associated with aortic coarctation, dissection, or aneurysm. Onset of symptoms in third to fifth decade

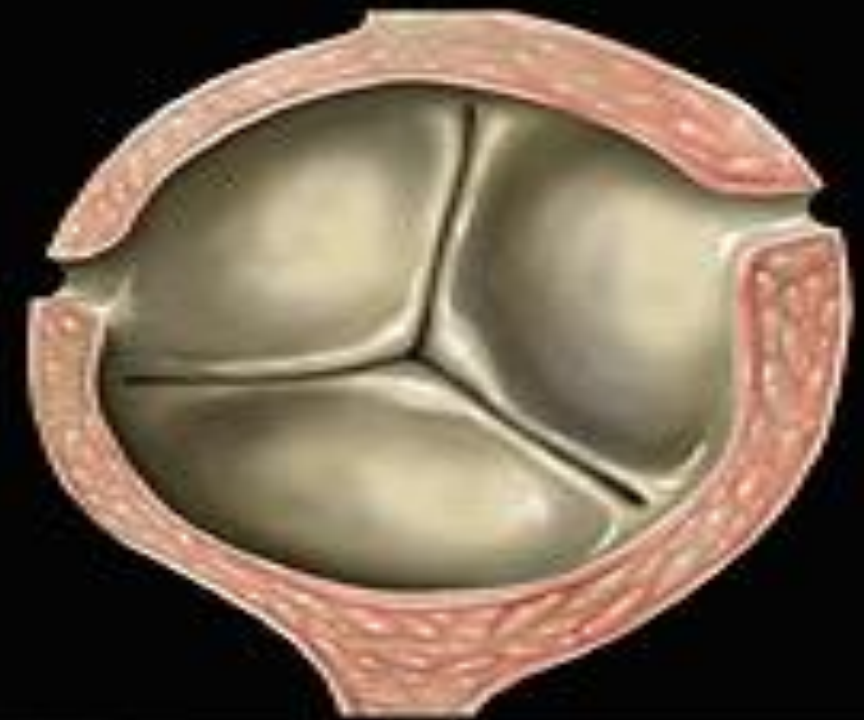Acquired

- 1. Degenerative calcification**
- 2. Rheumatic heart disease**
- 3. Rare causes**

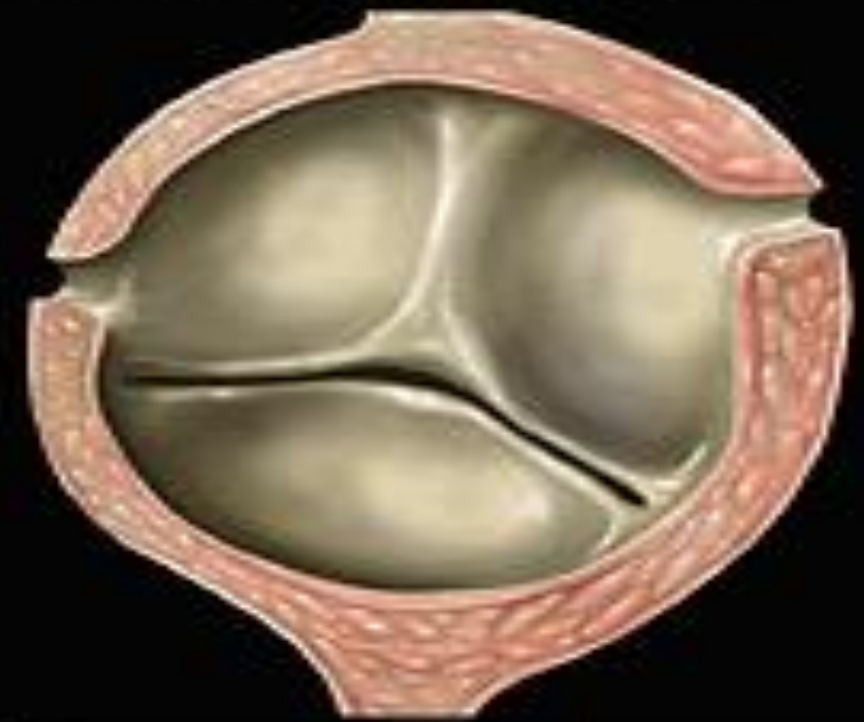Onset of symptoms in seventh to eighth decade. Higher incidence of risk factors for coronary artery disease (CAD)
Adhesions and fusion of commissures and cusps
Infectious vegetations, Paget disease, SLE, RA,
Postradiation (typically occurs 11.5–16.5 years after radiation⁵)

Short axis views from above aortic valves

Normal aortic valve



Bicuspid aortic valve



Left parasternal long axis view

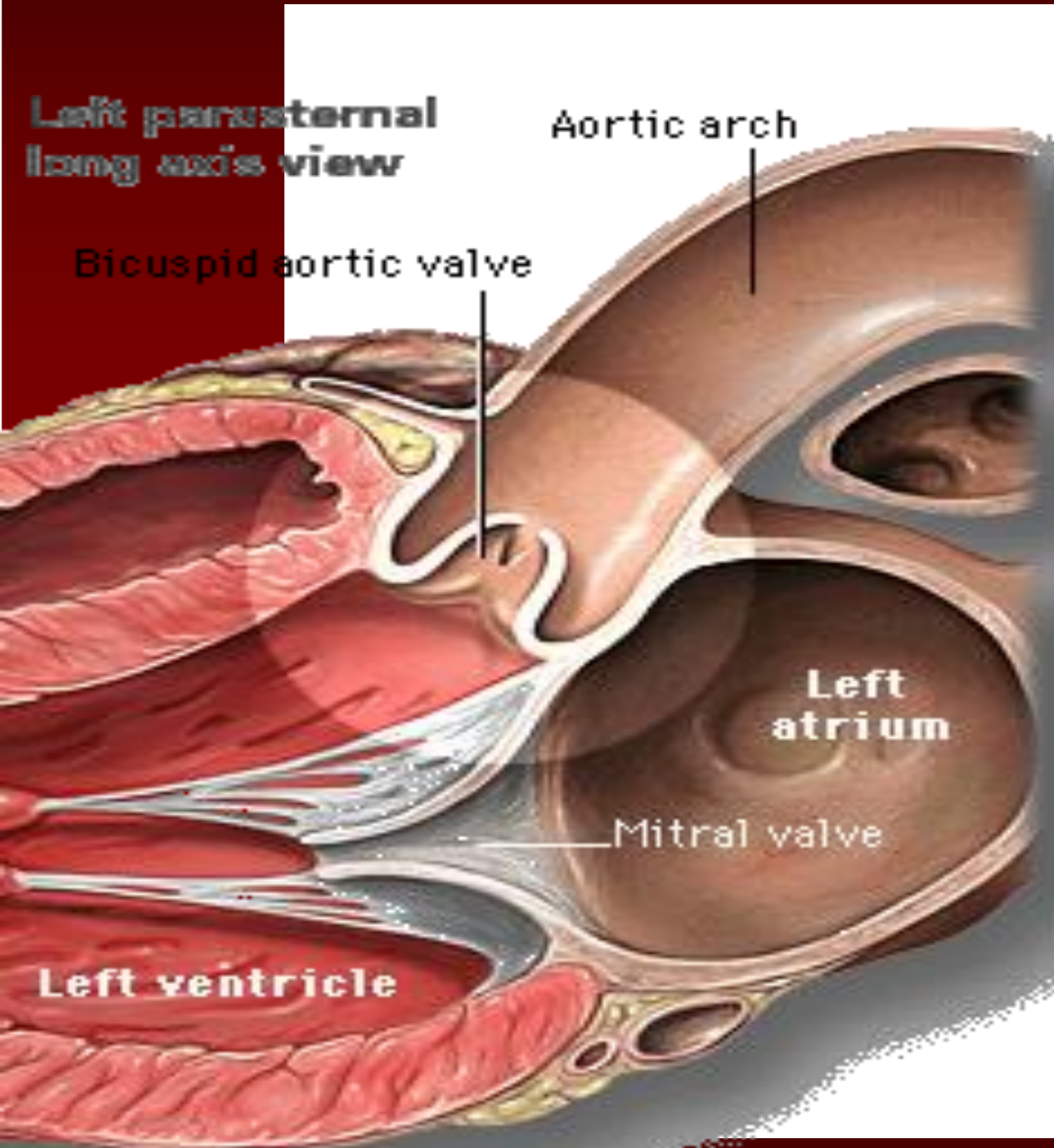
Aortic arch

Bicuspid aortic valve

Left atrium

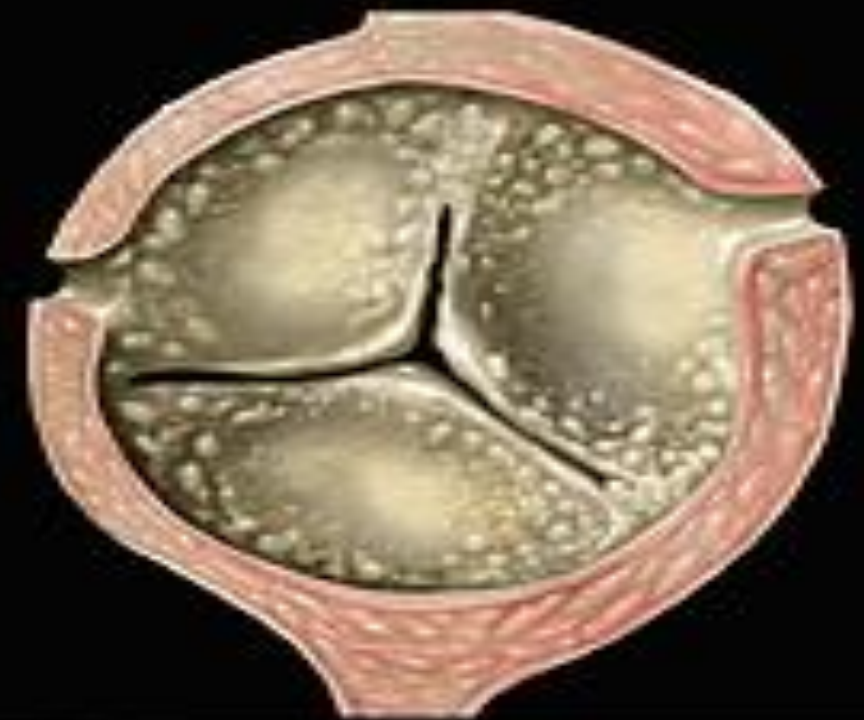Mitral valve

Left ventricle

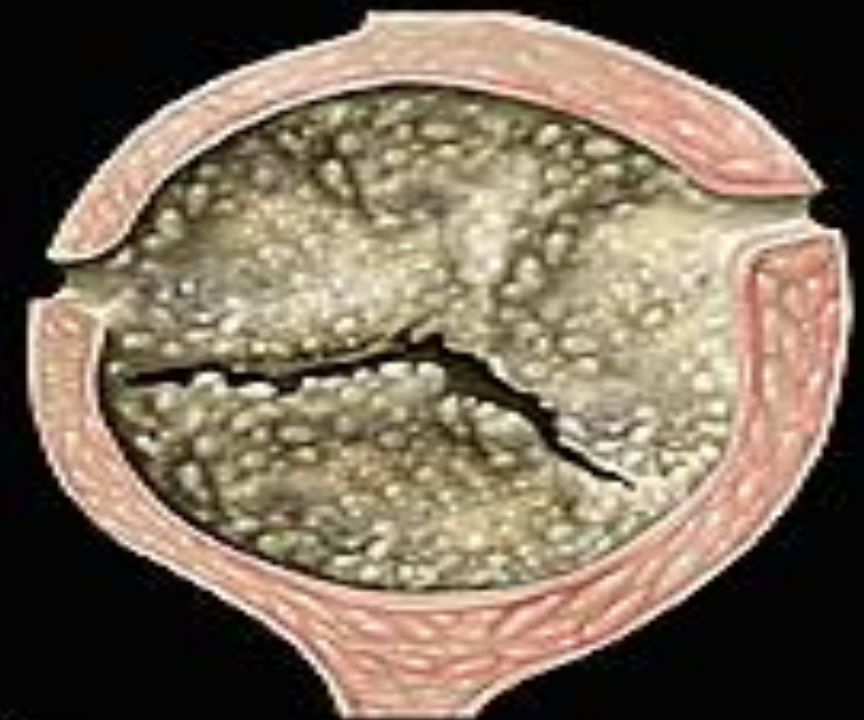

Short axis views from above aortic valves

Senile aortic stenosis



Bicuspid aortic stenosis



Left parasternal long axis view

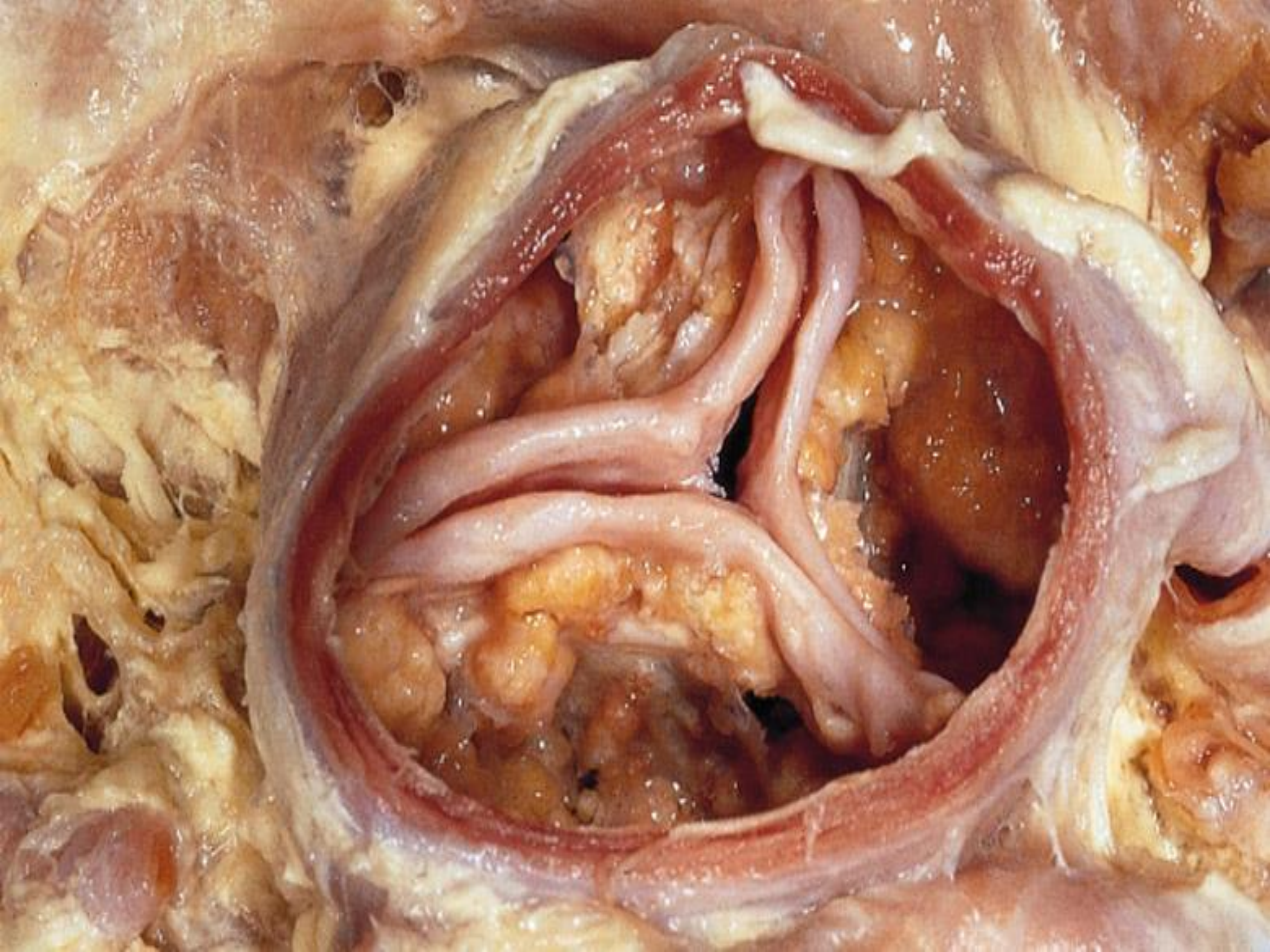
Aortic arch

Stenotic aortic valve

Left atrium

Mitral valve

Left ventricle



Pathophysiology of Aortic Stenosis

- A pressure gradient develops between the left ventricle and the aorta. (increased afterload)
- LV function initially maintained by compensatory pressure hypertrophy
- When compensatory mechanisms exhausted, LV function declines.

Presentation of Aortic Stenosis

- **Syncope:** (exertional)
- **Angina:** (increased myocardial oxygen demand; demand/supply mismatch)
- **Dyspnea:** on exertion due to heart failure (systolic and diastolic)
- Sudden death

Physical Findings in Aortic Stenosis

- Slow rising carotid pulse (*pulsus tardus*) & decreased pulse amplitude (*pulsus parvus*)
- Heart sounds- soft and split second heart sound, S4 gallop due to LVH.
- Systolic ejection murmur- crescendo-decrescendo character. This peaks later as the severity of the stenosis increases.
 - Loudness does **NOT** tell you anything about **severity**

Natural History

- Mild AS to Severe AS:
 - 8% in 10 years
 - 22% in 22 years
 - 38% in 25 years
- **The onset of symptoms is a poor prognostic indicator.**

Evaluation of AS

- Echocardiography is the most valuable test for diagnosis, quantification and follow-up of patients with AS.
- Two measurements obtained are:
 - a) Left ventricular size and function: LVH, Dilation, and EF
 - b) Doppler derived gradient and valve area (AVA)

Evaluation of AS

TABLE 12-1		Grading of severity of AS	
Severity of AS	AVA	Velocity	
Mild	$>1.5 \text{ cm}^2$	2.6–3.0 m/s	
Moderate	$1.0\text{--}1.5 \text{ cm}^2$	3.0–4.0 m/s	
Severe	$<1.0 \text{ cm}^2$	$>4.0 \text{ m/s}$	

Cardiac catheterization: Should only be done for a direct measurement if symptom severity and echo severity don't match OR prior to replacement when replacement is planned.

Management of AS

- **General-** IE prophylaxis in dental procedures with a prosthetic AV or history of endocarditis.
- **Medical** - limited role since AS is a mechanical problem. Vasodilators are *relatively contraindicated* in severe AS
- **Aortic Balloon Valvotomy-** shows little benefit.
- **Surgical Replacement:** Definitive treatment

Echo Surveillance

- **Mild:** Every 5 years
- **Moderate:** Every 2 years
- **Severe:** Every 6 months to 1 year

Simplified Indications for Surgery in Aortic Stenosis

- Any SYMPTOMATIC patient with severe AS (includes symptoms with exercise)
- Any patient with decreasing EF
- Any patient undergoing CABG with moderate or severe AS

Summary

- Disease of aging
- Look for the signs on physical exam
- Echocardiogram to assess severity
- Asymptomatic: Medical management and surveillance
- Symptomatic: AoV replacement (even in elderly and CHF)

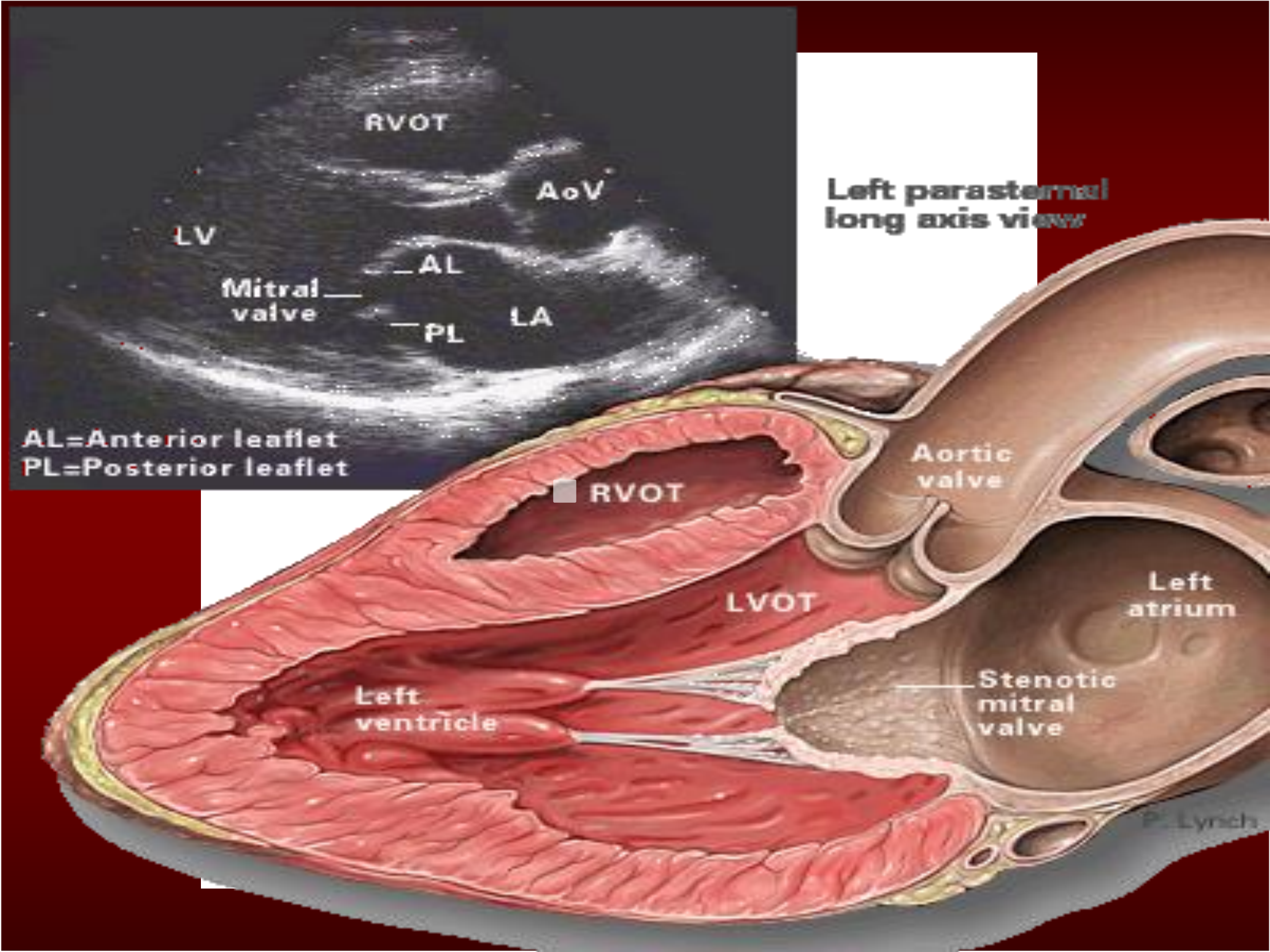
Mitral Stenosis

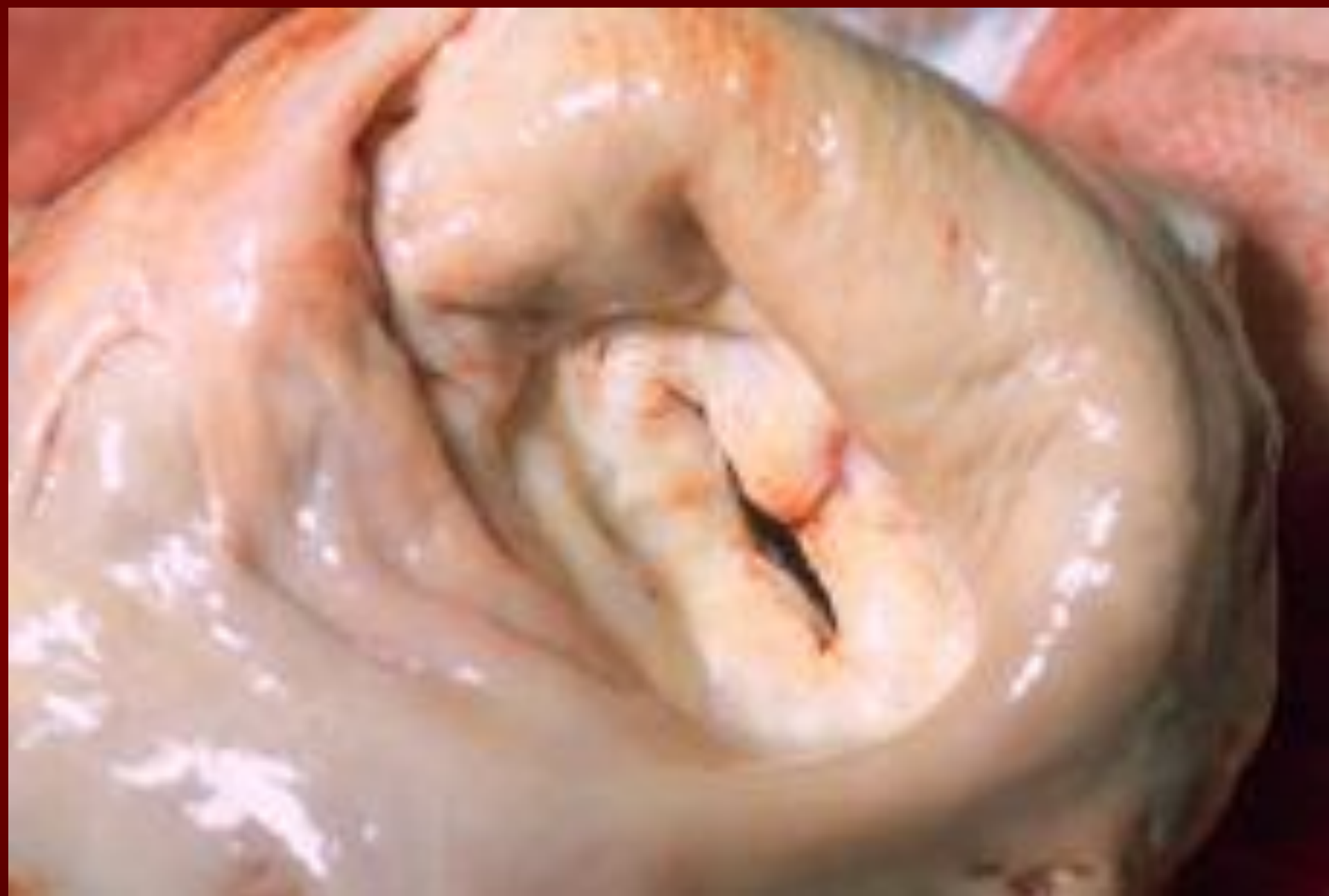Mitral Stenosis Overview

- **Definition:** Obstruction of LV inflow that prevents proper filling during diastole
- **Normal MV Area:** 4-6 cm²
- Transmitral gradients and symptoms begin at areas less than 2 cm²
- Rheumatic carditis is the predominant cause
- **Prevalence and incidence:** decreasing due to a reduction of rheumatic heart disease.


Etiology of Mitral Stenosis

- Rheumatic heart disease: 77-99% of all cases
- Infective endocarditis: 3.3%
- Mitral annular calcification: 2.7%





MS Pathophysiology

- **Progressive Dyspnea (70%):** LA dilation 
pulmonary congestion (reduced emptying)
 - worse with exercise, fever, tachycardia, and pregnancy
- **Increased Transmitral Pressures:** Leads to left atrial enlargement and atrial fibrillation.
- **Right heart failure symptoms:** due to Pulmonary venous HTN
- **Hemoptysis:** due to rupture of bronchial vessels due to elevated pulmonary pressure

Natural History of MS

- **Disease of plateaus:**
 - Mild MS: 10 years after initial RHD insult
 - **Moderate:** 10 years later
 - **Severe:** 10 years later
- **Mortality:** Due to progressive pulmonary congestion, infection, and thromboembolism.

Physical Exam Findings of MS

- **prominent "a" wave in jugular venous pulsations:**
Due to pulmonary hypertension and right ventricular hypertrophy
- **Signs of right-sided heart failure:** in advanced disease
- **Mitral facies:** When MS is severe and the cardiac output is diminished, there is vasoconstriction, resulting in pinkish-purple patches on the cheeks

Heart Sounds in MS

- **Diastolic murmur:**
 - Low-pitched diastolic rumble most prominent at the apex.
 - Heard best with the patient lying on the left side in held expiration
 - Intensity of the diastolic murmur does not correlate with the severity of the stenosis

Heart Sounds in MS

- **Loud Opening S₁ snap:** heard at the apex when leaflets are still mobile
 - Due to the abrupt halt in leaflet motion in early diastole, after rapid initial rapid opening, due to fusion at the leaflet tips.
 - **A shorter S2 to opening snap interval indicates more severe disease.**

Evaluation of MS

- **ECG:** may show atrial fibrillation and LA enlargement
- **CXR:** LA enlargement and pulmonary congestion. Occasionally calcified MV
- **ECHO:** The *GOLD STANDARD* for diagnosis. Asses mitral valve mobility, gradient and mitral valve area

TABLE 12-11**Severity of MS**

Severity of MR	Mild	Moderate	Severe
Parameter			
Mean gradient (mm Hg)	<5	5–10	>10
PA systolic pressure (mm Hg)	<30	30–50	>50
Valve area (cm ²)	>1.5	1.0–1.5	<1.0

Management of MS

Serial echocardiography:

- Mild: 3-5 years
- Moderate: 1-2 years
- Severe: yearly

- **Medications:** MS like AS is a mechanical problem and medical therapy does not prevent progression
β-blockers, CCBs, Digoxin which control heart rate and hence prolong diastole for improved diastolic filling
 - Diuretics for fluid overload

Management of MS

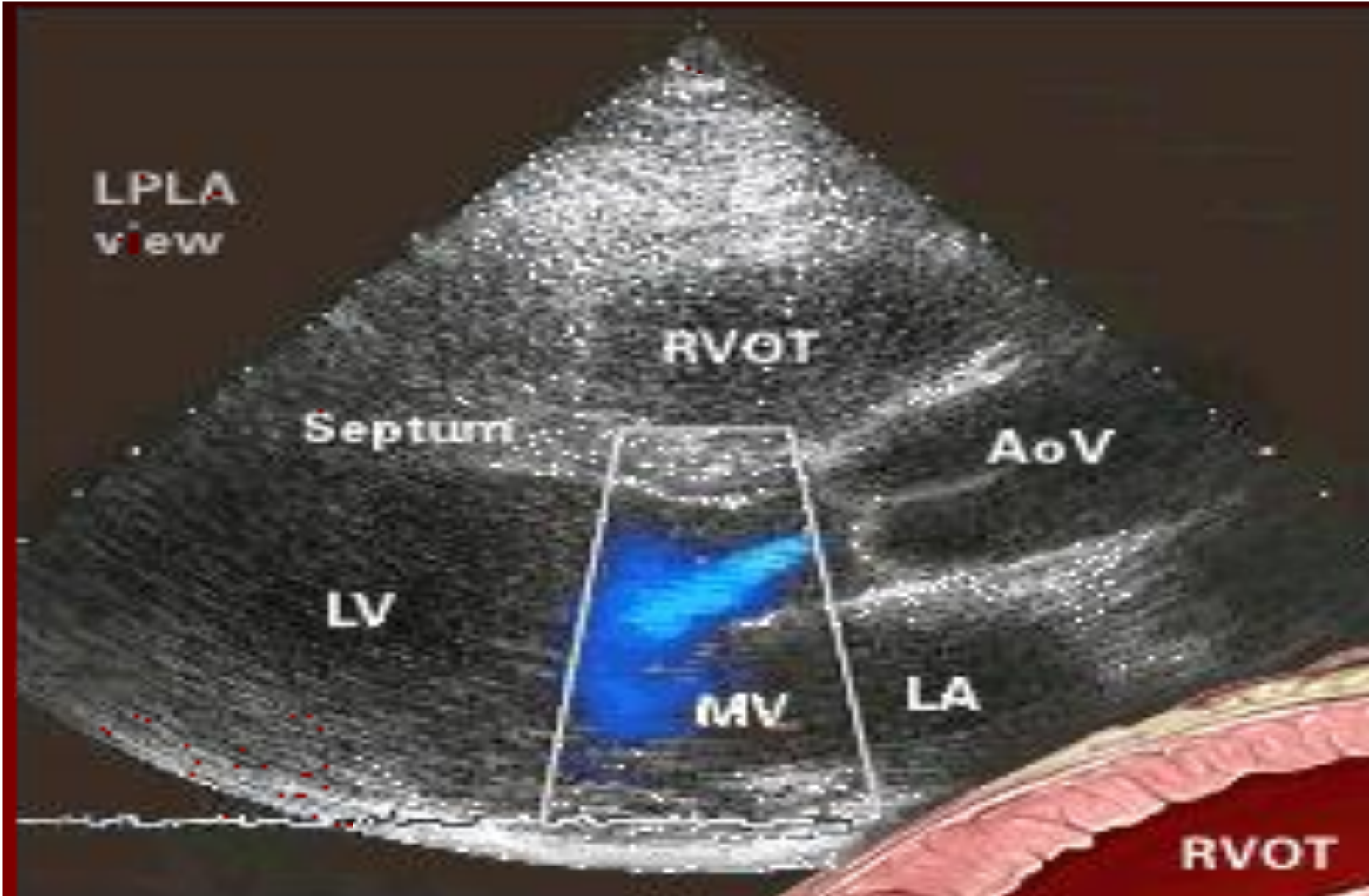
- Identify patient early who might benefit from percutaneous mitral balloon valvotomy.
- **IE prophylaxis:** Patients with prosthetic valves or a Hx of IE for dental procedures.

Simplified Indications for Mitral valve replacement

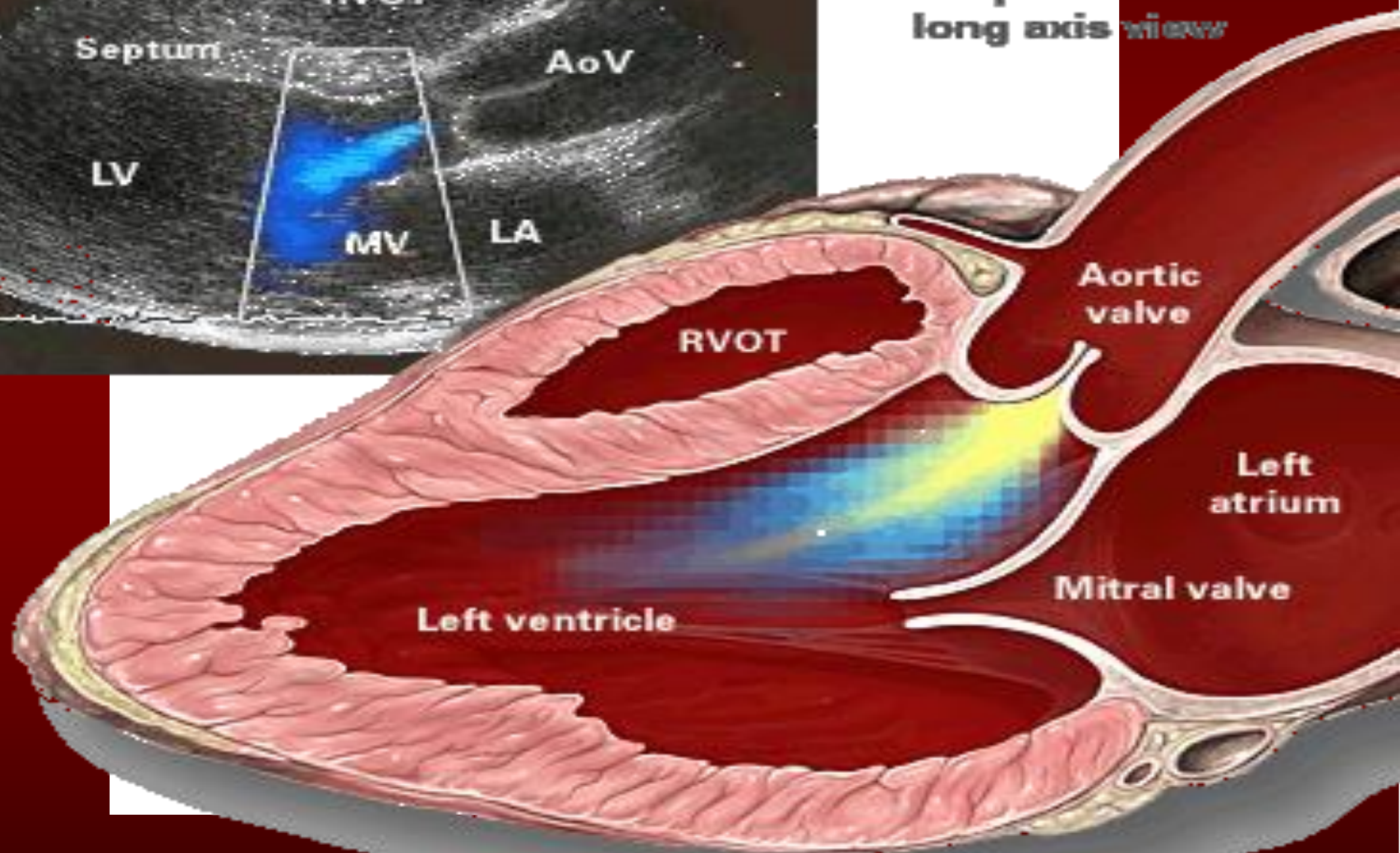
- ANY SYMPTOMATIC Patient with NYHA Class III or IV Symptoms
- Asymptomatic moderate or Severe MS with a pliable valve suitable for PMBV

Aortic Regurgitation

LPLA
view



Left parasternal
long axis view



Aortic Regurgitation Overview

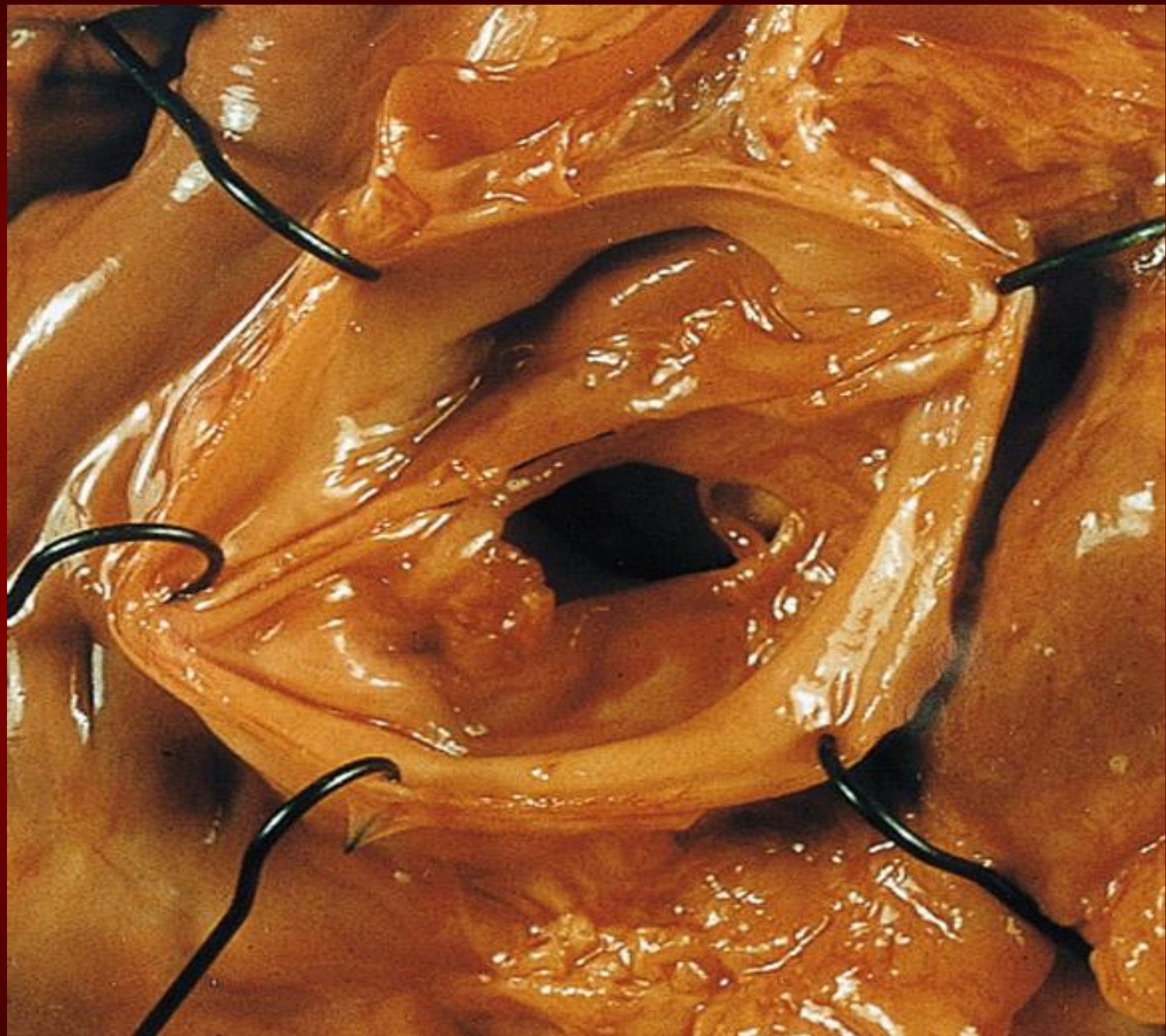- **Definition:** Leakage of blood into LV during diastole due to ineffective coaptation of the aortic cusps

Etiology of Acute AR

- Endocarditis
- Aortic Dissection
- **Physical Findings:**
 - Wide pulse pressure
 - Diastolic murmur
 - Florid pulmonary edema

Treatment of Acute AR

- True Surgical Emergency:
- Positive inotrope: (eg, dopamine, dobutamine)
- Vasodilators: (eg, nitroprusside)
- Avoid beta-blockers
- Do not even consider a balloon pump



Etiology of Chronic AR

- Bicuspid aortic valve
- Rheumatic
- Infective endocarditis

Pathophysiology of AR

- Combined pressure AND volume overload
- **Compensatory Mechanisms:** LV dilation, LVH. Progressive dilation leads to heart failure

Natural History of AR

- **Asymptomatic until 4th or 5th decade**
- **Rate of Progression: 4-6% per year**
- **Progressive Symptoms include:**
 - **Dyspnea:** exertional, orthopnea, and paroxysmal nocturnal dyspnea
 - **Nocturnal angina:** due to slowing of heart rate and reduction of diastolic blood pressure
 - **Palpitations:** due to increased force of contraction

Physical Exam findings of AR

- **Wide pulse pressure:** most sensitive
- Hyperdynamic and displaced apical impulse
- **Auscultation-**
 - **Diastolic blowing murmur** at the left sternal border
 - *Austin flint murmur* (apex): Regurgitant jet impinges on anterior MVL causing it to vibrate
 - *Systolic ejection murmur*: due to increased flow across the aortic valve

TABLE 12-6

Auscultatory and peripheral findings in severe AR: A glossary of eponyms

Sign	Description
Austin Flint murmur ^a	Low-pitched apical mid-diastolic rumble
Corrigan pulse ^a	High-amplitude, abruptly collapsing pulse
Duroziez sign ^a	To-and-fro bruit over femoral artery
Hill sign ^a	>40 mm Hg Δ between popliteal and brachial pressures
Mayne sign	>15 mm Hg drop in SBP with arm elevation pressure
Traube sign	Loud systolic "pistol shots" over the femoral artery
Quincke pulse	Exaggerated reddening and blanching of nail beds
Mueller sign	Visible pulsations of the uvula
de Musset sign	Visible bobbing of the head

The Evaluation of AR

- **CXR:** enlarged cardiac silhouette and aortic root enlargement
- **ECHO:** Evaluation of the AV and aortic root with measurements of LV dimensions and function (cornerstone for decision making and follow up evaluation)
- **Aortography:** Used to confirm the severity of disease

TABLE 12-4**Grading of severity of AR**

Severity of AR	Mild	Moderate	Severe
Qualitative			
Angiographic grade	1+	2+	3+
Doppler central jet width	<25% LVOT	25%–65% LVOT	>65%
Vena contracta width (cm)	<0.3	0.3–0.6	LVOT >0.6
Quantitative			
Regurgitant volume (mL/beat)	<30	30–59	>60
Regurgitant fraction	<30%	30–49	>50
Regurgitant orifice area (cm ²)	<0.1	0.1–0.29	>0.3

Management of AR

- **General:** IE prophylaxis in dental procedures with a prosthetic AV or history of endocarditis.
- **Medical:** Vasodilators (ACEI's), Nifedipine improve stroke volume and reduce regurgitation *only if pt symptomatic or HTN.*
- **Serial Echocardiograms:** to monitor progression.
- **Surgical Treatment:** Definitive Tx

Simplified Indications for Surgical Treatment of AR

- ANY Symptoms at rest or exercise
- Asymptomatic treatment if:
 - EF drops below 50% or LV becomes dilated

Mitral Regurgitation

Chronic Mitral Regurgitation

Overview

- **Definition:** Backflow of blood from the LV to the LA during systole
- Mild (physiological) MR is seen in 80% of normal individuals.

Acute MR

- Endocarditis
- Acute MI:
- Malfunction or disruption of prosthetic valve

Management of Acute MR

- **Myocardial infarction: Cardiac cath or thrombolytics**
- **Most other cases of mitral regurgitation is afterload reduction:**
 - **Diuretics and nitrates**
 - **nitroprusside, even in the setting of a normal blood pressure.**

Management of Acute MR

- **Do not attempt to alleviate tachycardia with beta-blockers. Mild-to-moderate tachycardia is beneficial in these patients because it allows less time for the heart to have backfill, which lowers regurgitant volume.**

Treatment of Acute MR

- Balloon Pump
- Nitroprusside even if hypotensive
- Emergent Surgery

Etiologies of Chronic Mitral Regurgitation

- Myxomatous degeneration (MVP)
- Ischemic MR
- Rheumatic heart disease
- Infective Endocarditis

Pathophysiology of MR

- **Pure Volume Overload**
- **Compensatory Mechanisms:** Left atrial enlargement, LVH and increased contractility
 - Progressive left atrial dilation and right ventricular dysfunction due to pulmonary hypertension.
 - Progressive left ventricular *volume overload* *leads to dilation* and progressive heart failure.

Physical Exam findings in MR

- **Auscultation:** soft S1 and a **holosystolic** murmur at the apex radiating to the axilla
 - S3 (CHF/LA overload)
 - In chronic MR, the intensity of the murmur does correlate with the severity.
- **Exertion Dyspnea:** (exercise intolerance)
- **Heart Failure:** May coincide with increased hemodynamic burden e.g., pregnancy, infection or atrial fibrillation

The Natural History of MR

- **Compensatory phase:** 10-15 years
- Patients with asymptomatic severe MR have a 5%/year mortality rate
- Once the patient's EF becomes $<60\%$ and/or becomes symptomatic, mortality rises sharply
- **Mortality:** From progressive dyspnea and heart failure

Imaging studies in MR

- **ECG:** May show, LA enlargement, atrial fibrillation and LV hypertrophy with severe MR
- **CXR:** LA enlargement, central pulmonary artery enlargement.
- **ECHO:** Estimation of LA, LV size and function.
Valve structure assessment
 - TEE if transthoracic echo is inconclusive

TABLE 12-8**Grading of severity of MR**

Severity of MR	Mild	Moderate	Severe
Qualitative Angiographic grade Doppler central jet width Vena contracta width (cm) LA/LV size	1+ <20% LA area <0.3	2+ 20%–40% LA area 0.3–0.69	3+–4+ >40% LA area >0.7 Enlarged
Quantitative Regurgitant volume (mL/beat) Regurgitant fraction Regurgitant orifice area (cm ²)	<30 <30% <0.2	30–59 30–49 0.2–0.39	>60 >50 >0.4

Management of MR

- **Medications**

- a) Vasodilator such as hydralazine
- b) Rate control for atrial fibrillation with β -blockers, CCB, digoxin
- c) Anticoagulation in atrial fibrillation and flutter
- d) Diuretics for fluid overload

Management of MR

- **Serial Echocardiography:**
 - **Mild:** 2-3 years
 - **Moderate:** 1-2 years
 - **Severe:** 6-12 months
- **IE prophylaxis:** Patients with prosthetic valves or a Hx of IE for dental procedures.

Simplified Indications for MV Replacement in Severe MR

- ANY Symptoms at rest or exercise with
(repair if feasible)
- Asymptomatic:
 - If EF <60%
 - If new onset atrial fibrillation