

University of Babylon  
College of Dentistry  
4<sup>th</sup> stage

# Orthodontics

Dr. Lamis Khidher Mohammed

## Lec.6 Orthodontic tooth movement

### Biology of Orthodontic Tooth movement

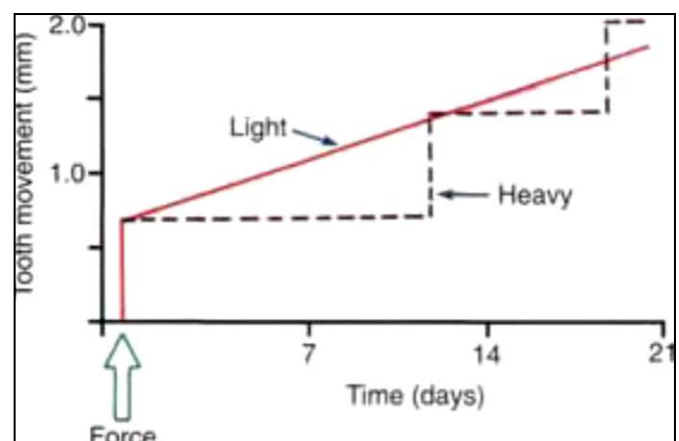
#### Effect of Force magnitude

Physiological and the histological response of the tooth and its surrounding structures to the force differs according to force magnitude if it was heavy or light as following:

#### A- Light continues force

When light but prolonged force is applied to a tooth, blood flow through the partially compressed PDL decreases as soon as fluids are expressed from the PDL space and the tooth moves in its socket (i.e., in a few seconds). Within a few hours at most, the resulting change in the chemical environment produces a different pattern of cellular activity. Animal experiments have shown that increased levels of cyclic adenosine monophosphate (AMP), the "second messenger" for many important cellular functions including differentiation, appear after about 4 hours of sustained pressure. This amount of time to produce a response correlates rather well with the human response to removable appliances. If a removable appliance is worn less than 4 to 6 hours per day, it will produce no orthodontic effects. Above this duration threshold, tooth movement does occur.

The tooth movement occurs when the osteoclasts are formed directly along the bone surface in the area adjacent to the compressed part of the PDL. Such a reaction called "*frontal resorption*" and it is obtained when the PDL be compressed only to a certain extent (so as not to occlude the capillaries) and must cause little or ideally no hyalinization. This is only possible when forces are close to the capillary pulse pressure. The Osteoblasts also are needed to form new bone on the tension side and remodel resorbed areas on the pressure side. With frontal resorption, a steady attack on the outer surface of the lamina dura results in smooth continuous tooth movement, Figure1.



## B- Heavy continuous force

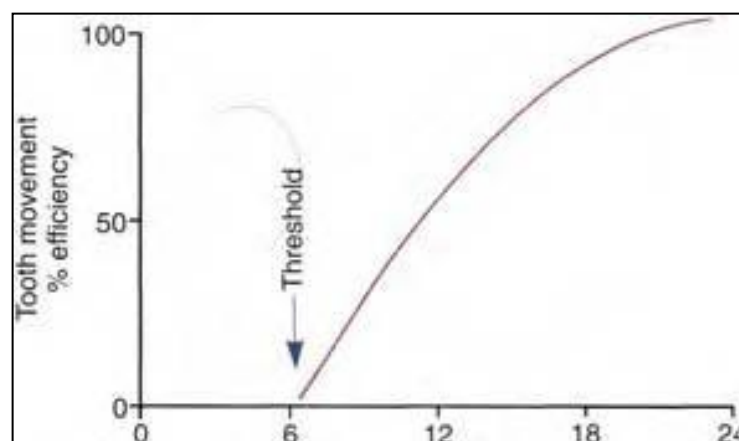
The course of events is different if the sustained force against the tooth is great enough to totally occlude blood vessels and cut off the blood supply to an area within the PDL. When this happens, a sterile necrosis of cellular elements within the PDL, which becomes nonfunctional. Because of the histological appearance of the cells in the region (which lose their distinct structure, the nuclei may shrink and/or disappear) the avascular area has been referred to as "hyalinized". Remodeling of bone bordering the necrotic area of the PDL will be accomplished by cells derived from adjacent undamaged areas.

After a delay of several days, cellular elements begin to invade the necrotic (hyalinized) area. More importantly, osteoclasts appear within the adjacent bone marrow spaces and begin an attack on the underside of the bone immediately adjacent to the necrotic PDL area. This process is appropriately described as "*undermining resorption*", since the attack is from the underside of the lamina dura.

The delay in tooth movement is caused *first* by a delay in stimulating differentiation of cells within the marrow spaces, and *second*, because a considerable thickness of bone must be removed from the underside before any tooth movement can take place. At that point, the tooth "jumps" to a new position, and if heavy force is maintained, there will again be a delay until a second round of undermining resorption can occur, Figure 1.

### *Effect of force duration*

The key to producing orthodontic tooth movement is the application of sustained force. There is a threshold for force duration in humans in the (4-8 hour) range, and that increasingly effective tooth movement is produced if force is maintained for longer durations. Continuous forces, produced by fixed appliances that are not affected by what the patient does, produce more tooth movement than removable appliances unless the removable appliance is present almost all the time.

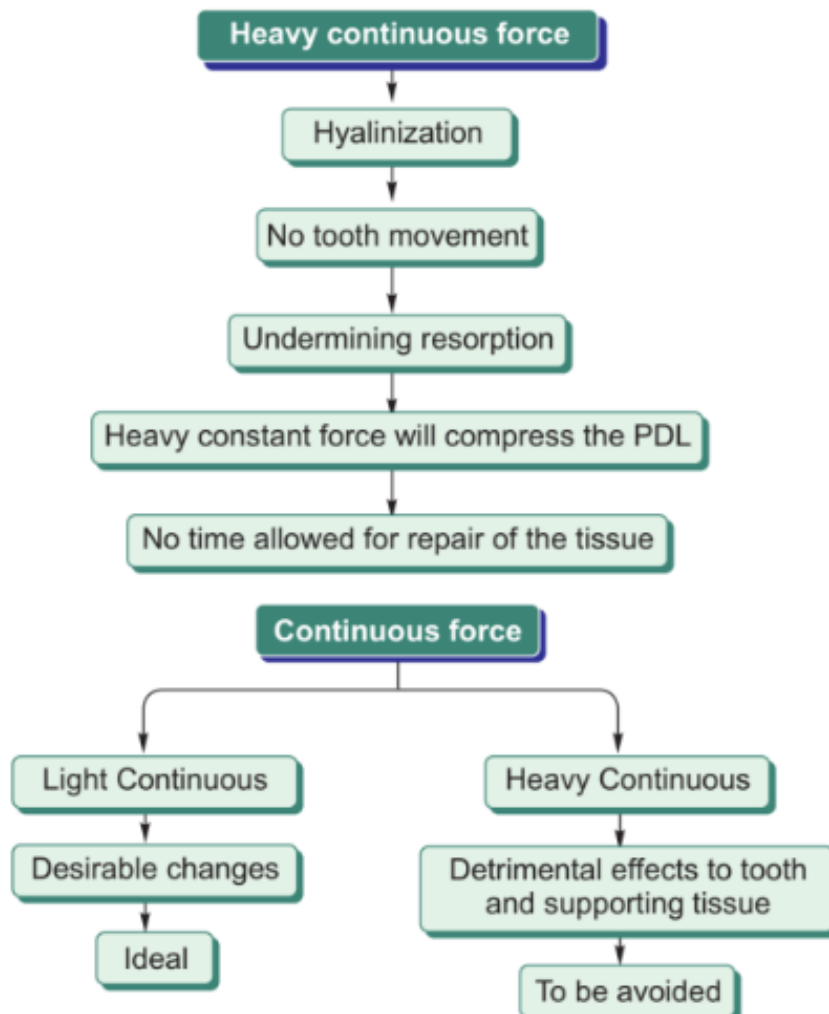
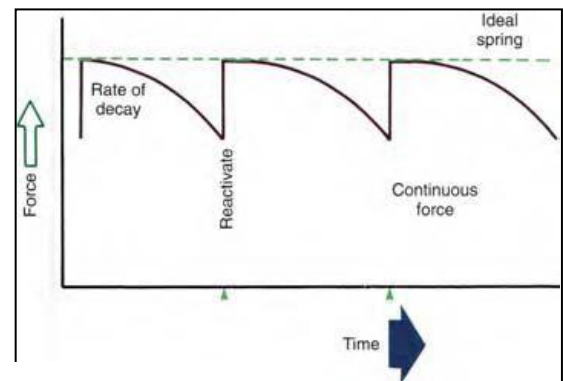


Orthodontic force classified into Continuous, Interrupted, and Intermittent based on the duration and the decay rate of orthodontic force :-

- Continuous—force maintained at some appreciable fraction of the original force between the two successive visits of patient. The force level does not decline to zero .

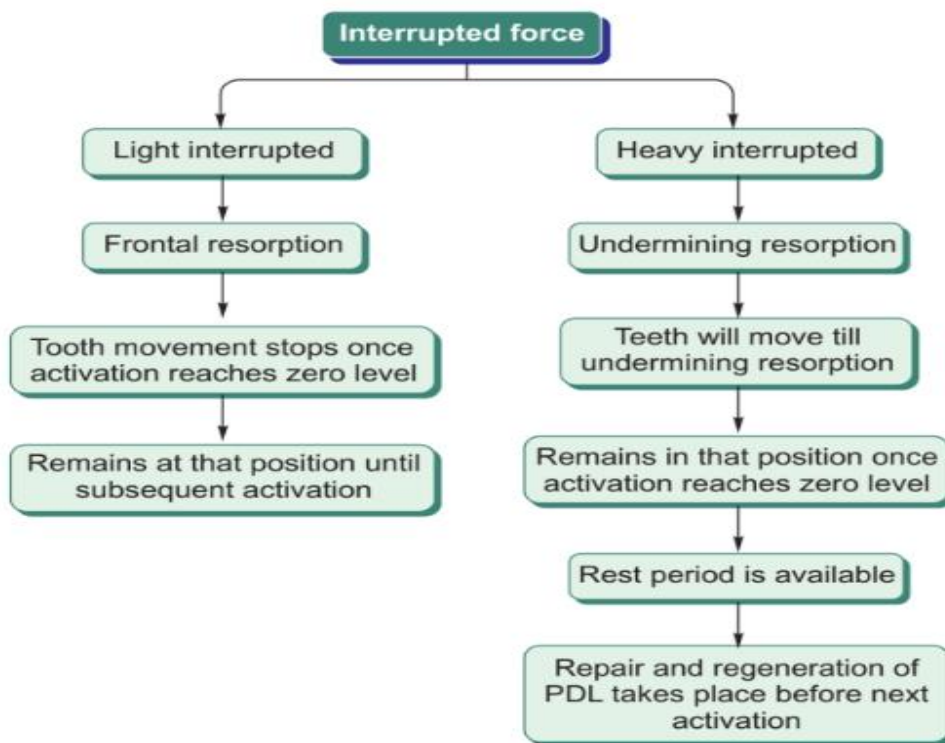
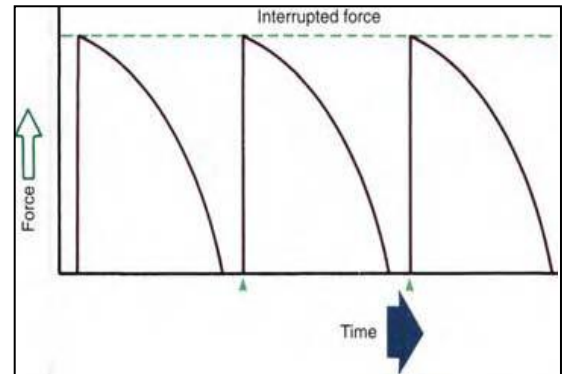
For the continuous force to be effective , it should be a light continuous force that produce smooth progression of tooth movement with direct or frontal resorption.

Heavy continuous force can be detrimental to the tissues as mentioned previously and as summarized in figure below:

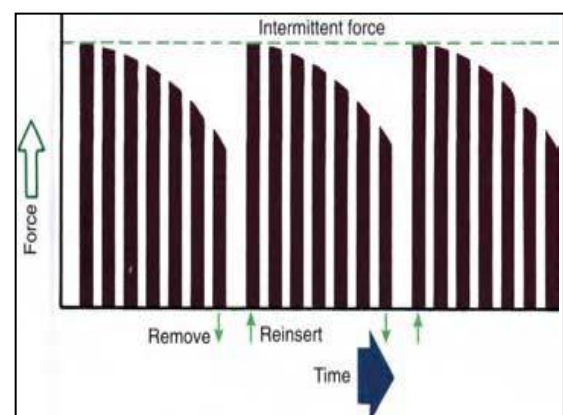


- Interrupted—force levels decline or reduces to zero between the two successive visits of patient. Both continuous and interrupted forces can be produced by fixed appliances that are constantly present.

Interrupted force can be light or heavy forces and its effect summarized in figure below :



- Intermittent—force levels decline abruptly or sudden drop to zero intermittently, when the orthodontic appliance is removed by the patient or perhaps when a fixed appliance is temporarily deactivated, and then return to the original level some time later. When tooth movement occurs, force levels will decrease as they would with a fixed appliance (i.e., the intermittent force can also become interrupted between adjustments of the appliance).



## Deleterious effects of orthodontic force

### **1- Effect on the pulp:**

- Modest and transient inflammatory response within the pulp, at least at the beginning of tooth movement, with no long-term significance.
- A large enough abrupt movement of root apex could sever the blood vessels entering the pulp canal.

### **2- Effect on root structure:**

- Root remodeling is constant feature of orthodontic tooth movement, but permanent loss of root structure would occur only if repair did not replace the initially resorbed cementum.
- According to some studies, endodontically treated teeth are slightly more prone to root resorption during orthodontic than are teeth with normal vitality.
- High than average resorption can be anticipated if the teeth have:
  - ▶ Cortical root with pointed apices.
  - ▶ Distorted root form.
  - ▶ History of trauma.
  - ▶ Root apices in contact with cortical bone.
  - ▶ Excessive force during orthodontic treatment. particularly if heavy continuous force are used.

### **3- Effect on alveolar bone height:**

- Excessive loss of crestal bone height is almost never seen as a complication of orthodontic tooth movement.
- Almost never exceed 1mm, greater changes at extraction sites.

### **4- Mobility:**

- Radiographically, it can be observed that the periodontal ligament space widens during orthodontic tooth movement.
- Heavier the orthodontic force, greater the amount of undermining resorption expected leading to greater mobility.
- If a tooth become extremely mobile during orthodontic treatment, all force should be discontinued until the mobility decreases to moderate level.

### **5- Pain:**

- Pain of any type involves a great deal of individual variation.
- Pain is related to the development of ischemic areas in the PDL. Hence, higher force, more pain.
- If light forces are used, the amount of pain experienced by patients can be decreased having them engaged in repeated chewing during the first 8 hours after the orthodontic appliance is activated.

---

## **Effect of drugs medications on tooth movement :-**

### **1- Orthodontic tooth movement enhancers:**

- Vitamin D administration enhance tooth movement .
- Direct injection of prostaglandin into the PDL shown increase the rate of tooth movement but its painful technique.

### **2- Orthodontic tooth movement depressors :**

- Bisphosphonates (used for treatment of osteoporosis ex: Alendronate)
- Prostaglandin inhibitors (ex: indomethacin that used for arthritis treatment) .