

Evaluation of the Surgical and Pharmacological Treatment of Diabetic Foot Infection: A Retrospective Study

Adil Hassan Aliakbar¹, Malath Azeez Alsaadi^{2*}, Abbas Abd Zaid Barrak³

¹Department of Surgery, College of Medicine, University of Babylon, Babil, Iraq; ²Department of Basic Medical Sciences, College of Dentistry, University of Babylon, Babil, Iraq; ³Ministry of Health, Hilla Teaching Hospital, Iraq

Abstract

Citation: Aliakbar AH, Alsaadi MA, Barrak AAZ. Evaluation of the Surgical and Pharmacological Treatment of Diabetic Foot Infection: A Retrospective Study. Open Access Maced J Med Sci. <https://doi.org/10.3889/oamjms.2019.298>

Keywords: Antibiotics; Diabetic foot; Infection; Outpatients

***Correspondence:** Malath Azeez Alsaadi. Department of Basic Medical Sciences, College of Dentistry, University of Babylon, Babil, Iraq. E-mail: alathazeer1122@gmail.com

Received: 29-Jan-2019; **Revised:** 22-Apr-2019; **Accepted:** 23-Apr-2019; **Online first:** 14-May-2019

Copyright: © 2019 Adil Hassan Aliakbar, Malath Azeez Alsaadi, Abbas Abd Zaid Barrak. This is an open-access article distributed under the terms of the Creative Commons Attribution-NonCommercial 4.0 International License (CC BY-NC 4.0)

Funding: This research did not receive any financial support

Competing Interests: The authors have declared that no competing interests exist

BACKGROUND: Diabetic foot infection is a major cause of patient disabilities and lowers limb amputations, with high treatment costs and hospitalisation requirements.

AIM: Aim of this study was to evaluate surgical wound care plus antibiotic effects in the treatment of mild and moderate diabetic foot infections.

METHODS: This retrospective study involved 60 patients with diabetic foot infections with or without osteomyelitis. The patients were categorised as group 1 mild and group 2 moderate. Both groups were treated using local wound debridement and the systemic administration of antibiotics. Group 1 (16) patients were treated with two regimens of oral antibiotics in two regimens, A (amoxicillin/clavulanate + metronidazole) and B (clindamycin + metronidazole), for 10-14 days. Group 2 (42) patients were treated with oral plus intravenous antibiotics in two regimens, A (ampicillin + cloxacillin + metronidazole) and B (lincomycin + metronidazole), for 6 weeks. The patients followed-up with local wound care specialists for 3 months to evaluate the treatment outcomes (cure, improvement, or failure).

RESULTS: Group 1 had an 80% cure rate under regimen A and a 100% cure rate under regimen B. Group 2 regimen A patients had a 61.5% cure rate and 11.53% improved, while regimen B patients had a 68.75% cure rate and 12.5% improved. Failure in both regimens was 23.8% in 20 patients with osteomyelitis, while 35% were cured and 20% improved during the study period.

CONCLUSION: Local surgical wound care for 3 months with antibiotic regimens for 6 weeks resulted in good response and cure rates, with lower costs and fewer instances of hospitalisation. Intravenous lincomycin and oral metronidazole achieved higher cure responses for moderate diabetic foot infections.

Introduction

Diabetic foot infection is a serious complication of diabetes mellitus that can cause morbidity and disability. It is costly to treat and can be life-threatening, leading to lower limb amputation, and may cause systemic infection and septicemia if not treated properly [1], [2].

International reports indicate that 25-50% of diabetic patients are subject to amputations due to infections. In the United States, diabetic foot infections are associated with a higher annual rate of referral and hospital admission [3], [4].

Reports highlight the negative impact of diabetic foot infections on patients' lives. Diabetic foot infections develop due to the impact of diabetes mellitus on the peripheral nervous system, leading to the motor, sensory, and autonomic neuropathy that cause stress shear, foot deformity, dryness, and peripheral arterial atherosclerosis [5]. All these factors lead to foot ulcers due to minor trauma. Treatment of diabetic foot ulcers plays a crucial role in preventing infection, but recurrent ulceration and infection can occur. The management of diabetic foot infection varies according to the classification and bone involvement. However, outcomes generally depend on local wound care, surgical debridement, dressing changes, and pharmacological treatment [6].

Initiating successful management includes an evaluation of the patient's medical history and health status, maintenance of microcirculation, wound depth, and infectious pathogens. In cases of mild wound infection, an inspection of wound depth, abscess drainage, evaluation of microcirculation, and culture sensitivity tests are important measures to choose the proper antibiotic treatment and avoid infection of adjacent tissue [7], [8]. Moderate and severe diabetic foot infections require more aggressive surgical wound debridement and drainage of abscesses with minor or major amputations in certain cases in addition to long regimens of antibiotic therapy [9], [10].

The proper choice of antibiotics is of great value to cover all the microorganisms involved. The antibiotics should be active against *S. aureus* and streptococci species that are frequently isolated [11]. Different guidelines are available for antibiotic selection with no fixed routes, duration, and/or superiority of certain regimens. However, each protocol depends on the severity of infection, isolated microorganisms, and history of previous antibiotic treatment [12], [13], [14].

The current study aimed to evaluate surgical wound management and antibiotic treatment according to the case severity of diabetic foot infections.

Methods

We conducted a retrospective clinical study to evaluate the surgical and antibiotic treatment of patients who presented at an orthopaedic consultation clinic from October 2015 to November 2016 with diabetic foot infections of mild and moderate severity according to the IDSA classification (Table 1) [2].

Table 1: Diabetic foot infection severity according to IDSA classification

Clinical description	Severity
Manifestations of inflammation (purulence or erythema, pain, tenderness, warmth, or induration); any cellulitis or erythema extends ≤ 2 cm around the ulcer, limited to skin or superficial subcutaneous tissues; no local complications or systemic illness	Mild
Infection in a patient who is systemically well and metabolically stable but has ≥ 2 cm; lymphangitis; spread beneath fascia; deep tissue abscess; gangrene; muscle, tendon, joint, or bone involvement	Moderate
Infection in a patient with systemic toxicity or metabolic instability.	Sever

Patients

A total of 60 patients were involved in the current study. Their clinical data were recorded, including general information, history of diabetes mellitus, history of diabetic foot infection, history of previous amputation, current antibiotic therapy, and

medications .

Examination of the patients included general examination, vital signs, local examination of both feet including neurovascular assessment, and examination of the infected area(s). The patients underwent serological investigations, including random blood sugar, PCV, WBC, C-reactive protein, and ESR. Imaging studies included X-rays of the infected foot with AP and lateral views (Table 2).

Table 2: Patient's clinical data

Criteria	All patients n = 58
Sex ratio female/male	22/36
Age mean \pm SD	61.5 \pm 10.5
Site of infection	Toes = 30 (58) Heel = 6 (58) Other site = 10 (58)
	Mixed (more than one site) = 12 (58)
Patients with osteomyelitis	20 patients (58)
History of the previous infection	46 (58)
History of amputation	18 (58)
Patients need partial or complete toe (s) amputation during wound debridement	16 (58)

Doppler studies of both lower limbs were performed to assess circulation. We then consulted an endocrinologist to control the patients' blood sugar and a vascular surgeon to evaluate their peripheral circulation.

Exclusion criteria were (1) severe types of infection according to the IDSA classification, (2) severe ischemia with gangrenous lesions, and (3) diabetic foot ulcers with no signs of infection.

Treatments

Local wound care

We started with wound debridement under local anaesthesia and drainage of abscesses (after obtaining wound swabs for culture and sensitivity testing). Some wounds required limited surgical resection of parts of the toe or toes followed by irrigation with normal saline and dressing with gauze soaked in 2% iodine solution. According to the severity, the dressings were changed 1-2 times a day. The patients' wounds were followed-up every 5 days, then every 10-14 days for 3 months after initial improvement.

Antibiotic treatment

Empirical antibiotic treatment was as follows:

Group 1. For mild diabetic foot infections according to the IDSA, the patients in regimen A received 1 dose of oral amoxicillin/clavulanate every 12 hours + 1 dose of metronidazole every 8 hours for 10-14 days (Figure 1). The patients in regimen B who were allergic to penicillin or already on penicillin without a response were administered 1 dose of clindamycin every 6 hours + one dose of metronidazole every 8 hours for 10-14 days.

Group 2. For the patients with moderate diabetic foot infection with or without osteomyelitis, those in regimen A received intravenous ampicillin/cloxacillin + metronidazole orally for 5 days and then either repeated this course if the response was inadequate or changed to an oral regimen similar to group 1 regimen A for not less than 6 weeks. The patients in regimen B who were allergic to penicillin or already on penicillin without a response received intravenous lincomycin + oral metronidazole for 5 days and then either repeated this course if the response was inadequate or changed to an oral regimen according to group 1 regimen B for not less than 6 weeks (Figure 1).

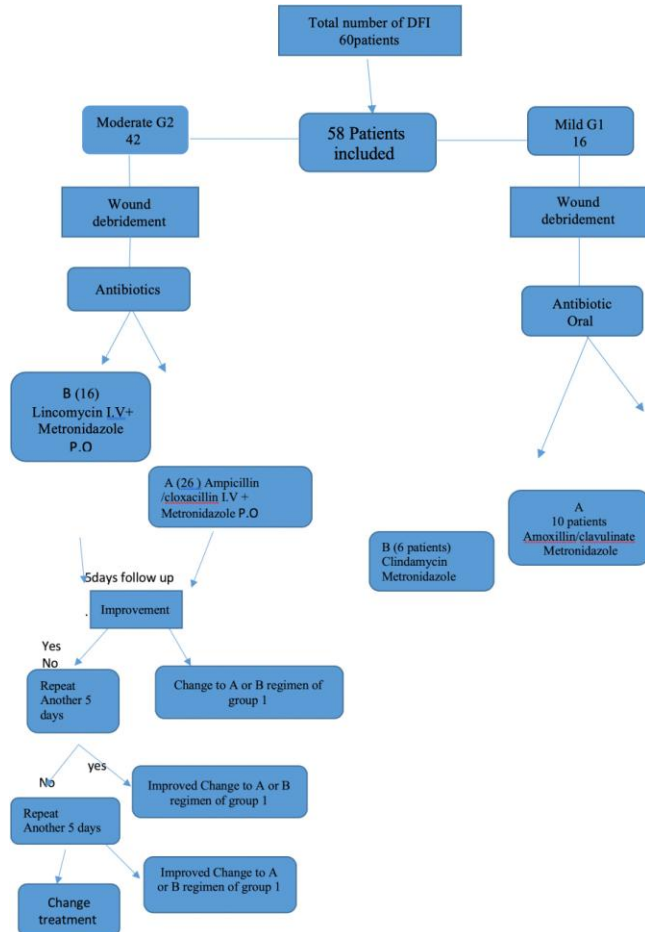


Figure 1: Study design diagram

Drugs

(1) Amoxicillin/clavulanate, 1000 mg oral tablets (CoAmox Acino, Acino, Zurich, Switzerland).

(2) Metronidazole, 500 mg oral tablets (Flagyl, Sanofi-Aventis, Gentilly, France).

(3) Clindamycin hydrochloride, 300 mg oral capsules (Lanacin, Al-Mutahida, Amman, Jordan).

(4) Ampicillin + cloxacillin, 250 mg/250 mg intravenous injection (LDP Torlan, Barcelona, Spain).

(5) Lincomycin hydrochloride, 600 mg intravenous injection every 8 hours (Lincocin, Pfizer,

Puurs, Belgium).

Outcome assessment

We classified the patients according to their responses to management during the follow-up periods, which were every 5 days in the acute stage (for the first 3 weeks), then every 10-14 days for the next 3 months.

The responses according to Lipsky (1997) [15] were (1) cure: all signs and symptoms of inflammation, pus, and osteomyelitis had disappeared, and the wound had begun to heal; (2) improvement: incomplete abatement of the signs and symptoms of infection; and (3) failure: no improvements.

Secondary outcomes involved adverse reactions to the antibiotic regimens.

Results

Overall, 58 patients were included in this study after the exclusion of two cases due to the development of adverse reactions to the medications. Among the patients in group 1 who received regimen A, eight were cured (80%) and 2 (20%) failed to respond and shifted to regimen B in group 1, while 6 patients in group 1 who received regimen B (100%) were cured after a treatment period of 10-14 days (Table 3).

Table 3: Clinical outcome of 16 patients included in group 1 (mild diabetic foot infection)

Group 1 No.16	Patients outcome of both regimen A, B of treatment	Regimen A No.10	Regimen B No.6
Cure	14 (16) 87.5%	8 (10) 80%	100%
Improved	0	0	0
Failed	2 (16) 12.5% shifted to G2	2 (10) 20%	0

A total of 42 patients were included in group 2, and 26 received regimen A; 16 patients were cured, 3 improved, and 7 failed to respond at the end of the treatment period (Table 4).

Table 4: Total clinical outcome of 42 patients included in group 2 at the end of the treatment period (moderate diabetic foot infection)

Group 2 Patients No.42	Total clinical outcome of both regimen	Regimen A No.26	Regimen B No.16
Cure	27 (42) 64.28%	16 (26) 61.5%	11 (16) 68.75%
Improved	5 (42) 11.9%	3 (26) 11.53%	2 (16) 12.5%
Failed	10 (42) 23.8%	7 (26) 26.9%	3 (16) 18.75%

A total of 16 patients in group 2 received regimen B; 11 were cured, 2 improved, and 3 failed to respond at the end of the treatment period (Tables 4 and 5).

Table 5: Clinical outcome of group 2 about duration of parenteral injection

Group 2 Patients No.42	6 weeks regimen including 5 days of injectable treatment		6 weeks regimen including 10 days of injectable treatment		6 weeks regimen including 15 days of injectable treatment	
	A	B	A	B	A	B
	No. (%)	No. (%)	No. (%)	No. (%)	No. (%)	No. (%)
Cure	12 (28.57%)	4 (9.5%)	4 (9.5%)	6 (14.28%)	0	1 (2.3%)
Improved	2 (4.7%)	1 (2.3%)	1 (2.3%)	1 (2.3%)	0	0
Failed	1 (2.3%)	1 (2.3%)	1 (2.3%)	0	5 (11.9%)	2 (4.7%)

Secondary outcomes included diarrhoea and skin rash, which developed in 2 patients in group 1 and required changes in treatment and exclusion. Most of the patients well tolerated the antibiotics with minor gastric upset that was treated with antacids.

The results of culture and sensitivity tests in 21 patients were mainly Gram-positive species including staphylococci and streptococci. Most were mixed infections; three patients had *E. coli*, and one had *Pseudomonas*.

Two patients in group 1 regimen A were switched to group 1 regimen B, and both were cured after 14 days of treatment.

The follow-up period continued for 3 months, including local wound care every 10-14 days (after completion of the antibiotic regimens). As a result, (1) there was no recurrence in the cured cases; (2) 3 of the improved cases were cured at the end of the follow-up period, while 2 cases had to repeat the antibiotic regime; and (3) all of the failed cases resulted in amputation.

Discussion

Diabetes mellitus is a systemic disease associated with complications that lead to morbidity. One of these complications is diabetic foot infection that may end with morbidity and mortality.

Many treatment guidelines lead to good clinical outcomes. All aim for higher success rates with less risk of amputations.

The current study's goal was to evaluate surgical and pharmacological therapy for diabetic foot infection of mild and moderate severity in outpatients both with and without osteomyelitis. We choose the IDSA classification, as it was more applicable to and representative of our cases and easily performed. Severe cases were excluded due to the necessity for hospitalisation. The included patients were treated in an orthopaedic consultation clinic using thorough wound debridement and dressing soaked in iodine to ensure protection from contamination. Wound debridement and care are very important as the initial step in diabetic foot infection treatment to remove all necrotic tissue and drain abscesses. Frequent daily

dressing is a very effective method for controlling infection and reducing the need for long-term antibiotic administration [16], [17], [18].

In this study, we used inexpensive antibiotics, have been widely used for many years, have well-known side effects, and can be administered to outpatients. Also, they include all common types of causative microorganisms of diabetic foot infections. Using these types of antibiotics leads to a success rate, similar to the results of recent studies including new generations of antibiotics that are expensive, require hospital admission, and necessitate similar treatment periods [19], [20], [21].

The cure rate in group 1 was 87.5%, which is acceptable, as the patients had no osteomyelitis and positive responses to the selected empirical antibiotics; there was good coverage of the microorganisms in this wound type with adequate penetration of the infected skin, soft tissue, and bone, in addition to low cost. Our results agree with those of De Vries [22] in a study that retrospectively evaluated the effectiveness of clindamycin and cephalosporin for the treatment of diabetic foot infection caused by *Staphylococcus aureus* and Gram-negative organisms, with an 87% success rate.

Metronidazole was administered to both groups as it is well tolerated and provides antimicrobial activity against most anaerobic microorganisms involved in this condition and colitis caused by *Clostridium difficile* [23]. This could explain the low frequency of adverse reactions observed during the treatment period; adverse reactions occurred in 2 patients in the group treated with oral clindamycin.

In group 2, the cure rate was 64.28% in both regimes, although 20 patients had osteomyelitis, which can affect the success rate. Nevertheless, 35% of the patients with osteomyelitis were cured and 20% improved during the antibiotic regimen, which lasted for 6 weeks, and none relapsed during the 3-month follow-up period. There was no need for hospitalisation and further costs (Table 6).

Table 6: Clinical outcome about osteomyelitis involvement

Group 2 Patients with osteomyelitis No.20	6 weeks regimen including 5 days of injectable treatment		6 weeks regimen including 10 days of injectable treatment		6 weeks regimen including 15 days of injectable treatment		Total No. (%)
	A	B	A	B	A	B	
	No. (%)	No. (%)	No. (%)	No. (%)	No. (%)	No. (%)	
Cure	2 (10%)	0 (0)	1 (5%)	3 (15%)	0	1 (5%)	7 (35%)
Improved	1 (5%)	1 (5%)	1 (5%)	1 (5%)	0	0	4 (20%)
Failed	1 (5%)	1 (5%)	1 (5%)	0 (0)	4 (20%)	2 (10%)	9 (45%)

The success rate of this study was comparable to many others, such as that of Yadlapalli [24], which reviewed 58 patients with diabetic foot infections and osteomyelitis treated for 4-6 weeks via intravenous injection of ceftizoxime, ampicillin/sulbactam, cefoxitin, and vancomycin; 79.3% of the patients were healed, although with a

different regime of antibiotics. Embil et al., [25] retrospectively reviewed 325 patients treated with oral antibiotics and oral plus intravenous antibiotics including metronidazole, clindamycin, amoxicillin/clavulanate, ciprofloxacin, and co-trimoxazole. They found a 75.8% remission rate in the oral plus intravenous regimen, although patients with abscesses and acute osteomyelitis were excluded, unlike the current study.

A review of the failed cases found that most were due to uncontrolled blood sugar, despite consultation with the endocrinologist; this was mainly related to the low socioeconomic status of most of the patients in our study.

In conclusion, patients with diabetic foot infections treated with surgical debridement and antibiotic regimens had favourable responses and cure rates during the study period, with lower costs and hospitalisation rates. Local wound care and good local follow-up improved the success rate and reduced the duration of antibiotic treatment. Oral clindamycin and metronidazole have superior success rates in patients with mild diabetic foot infections and intravenous lincomycin and oral metronidazole show a higher cure rate among moderate diabetic foot infection patients with or without osteomyelitis.

Ethical approval

All procedures performed in studies involving human participants were in accordance with the ethical standards of the institutional research committee and with the 1964 Helsinki declaration and its later amendments or comparable ethical standards.

Acknowledgements

We thank the orthopaedic consultation clinic employees for their cooperation in providing all the necessary recorded information.

References

- Mills JL Sr, Conte MS, Armstrong D.G, Frank B, Schanzer PA, Sidawy N, et al. The Society for Vascular Surgery Lower Extremity Threatened Limb Classification System: risk stratification based on Wound, Ischemia, and foot Infection (Wifli). *J Vasc Surg.* 2014; 59(1):22034.e1. <https://doi.org/10.1016/j.jvs.2013.08.003> PMID:24126108
- Lipsky AB, Berendt AR, Cornia PB, Pile C, Peters EG, Armstrong DG, et al. Infectious Diseases Society of America clinical practice guideline for the diagnosis and treatment of diabetic foot infections. *Clin Infect Dis.* 2012; 54(12):e132-e173. <https://doi.org/10.1093/cid/cis346> PMID:22619242
- Karagöz G, Kadanalı A, Öztürk S, Çakar Ş, Çomoğlu Ş, Doğan F. The analysis of the cost and amputation rates of hospitalized diabetic foot infection patients. *Int J Diabetes Dev Ctries.* 2017; 37:201. <https://doi.org/10.1007/s13410-016-0524-3>
- Skrepnek GH, Mills JL, Lavery LA, Armstrong DG. Health care service and outcomes among an estimated 6.7 million ambulatory care diabetic foot cases in the US. *Diabetes Care.* 2017; 40(7):936-42. <https://doi.org/10.2337/dc16-2189> PMID:28495903
- Armstrong DG, Boulton AJ, Bus SA. Diabetic foot ulcers and their recurrence. *New England Journal of Medicine.* 2017; 376(24):2367-75. <https://doi.org/10.1056/NEJMra1615439> PMID:28614678
- Lavery LA, Davis KE, Berriman SJ, Braun L, Nichols A, Kim PJ, Margolis D, Peters EJ, Attinger C. WHS guidelines update: diabetic foot ulcer treatment guidelines. *Wound Repair and Regeneration.* 2016; 24(1):112-26. <https://doi.org/10.1111/wrr.12391> PMID:26663430
- Kasiya MM, Mang'anda GD, Heyes S, Kachapila R, Kaduya L, Chilamba J, Goodson P, Chalulu K, Allain TJ. The challenge of diabetic foot care: Review of the literature and experience at Queen Elizabeth Central Hospital in Blantyre, Malawi. *Malawi Medical Journal.* 2017; 29(2):218-23. <https://doi.org/10.4314/mmj.v29i2.26> PMID:28955436 PMID:PMC5610299
- Tan JS, Friedman NM, Hazelton-Miller C, Flanagan JP, File Jr TM. Can aggressive treatment of diabetic foot infections reduce the need for above-ankle amputation? *Clin Infect Dis.* 1996; 23(2):286-291. <https://doi.org/10.1093/clinids/23.2.286> PMID:8842265
- Bader MS. Diabetic foot infection. *American Family Physician.* 2008; 78(1):71-9.
- Faglia E, Clerici G, Caminiti M, Quarantiello A, Gino M, Morabito A. The role of early surgical debridement and revascularization in patients with diabetes and deep foot space abscess: retrospective review of 106 patients with diabetes. *The Journal of foot and ankle surgery.* 2006; 45(4):220-6. <https://doi.org/10.1053/j.jfas.2006.04.002> PMID:16818148
- Eleftheriadou I, Tentolouris N, Argiana V, Jude E, Boulton AJ. Methicillin-resistant *Staphylococcus aureus* in diabetic foot infections. *Drugs.* 2010; 70(14):1785-97. <https://doi.org/10.2165/11538070-000000000-00000> PMID:20836573
- Lipsky BA, Hoey C, Cruciani M, Mengoli C. Topical antimicrobial agents for preventing and treating foot infections in people with diabetes. *Cochrane Database of Systematic Reviews.* 2014(3). <https://doi.org/10.1002/14651858.CD011038>
- Lazzarini L, Lipsky BA, Mader JT. Antibiotic treatment of osteomyelitis: what have we learned from 30 years of clinical trials? *International journal of infectious diseases.* 2005; 9(3):127-38. <https://doi.org/10.1016/j.ijid.2004.09.009> PMID:15840453
- Akhi MT, Ghotaslou R, Memar MY, Asgharzadeh M, Varshochi M, Pirzadeh T, Alizadeh N. Frequency of MRSA in diabetic foot infections. *International Journal of Diabetes in Developing Countries.* 2017; 37(1):58-62. <https://doi.org/10.1007/s13410-016-0492-7>
- Lipsky BA, Baker PD, Landon GC, Fernau R. Antibiotic therapy for diabetic foot infections: comparison of two parenteral-to-oral regimens. *Clinical infectious diseases.* 1997; 24(4):643-8. <https://doi.org/10.1093/clind/24.4.643> PMID:9145738
- Kavitha KV, Tiwari S, Purandare VB, Khedkar S, Bhosale SS, Unnikrishnan AG. Choice of wound care in diabetic foot ulcer: a practical approach. *World journal of diabetes.* 2014; 5(4):546. <https://doi.org/10.4239/wjd.v5.i4.546> PMID:25126400 PMID:PMC4127589
- Hobizal KB, Wukich DK. Diabetic foot infections: current concept review. *Diabetic foot & ankle.* 2012; 3(1):18409. <https://doi.org/10.3402/dfa.v3i0.18409> PMID:22577496

PMCID:PMC3349147

18. Elraiyah T, Domecq JP, Prutsky G, Tsapas A, Nabhan M, Frykberg RG, Hasan R, Firwana B, Prokop LJ, Murad MH. A systematic review and meta-analysis of débridement methods for chronic diabetic foot ulcers. *J Vasc Surg*. 2016; 63(2):37S-45S. <https://doi.org/10.1016/j.jvs.2015.10.002> PMID:26804366

19. Smieja M. Current indications for the use of clindamycin: A critical review. *Can J Infect Di*. 1998; 9(1):22-28. <https://doi.org/10.1155/1998/538090>

20. Noel GJ, Bush K, Bagchi P, Ianus J, Strauss RS. A randomized, double-blind trial comparing ceftobiprole medocartil with vancomycin plus ceftazidime for the treatment of patients with complicated skin and skinstructure infections. *Clinical Infectious Diseases*. 2008; 46:647-55. <https://doi.org/10.1086/526527> PMID:18225981

21. Saltoglu N, Dalkiran A, Tetiker T, Bayram H, Tasova Y, Dalay C, et al. Piperacillin/tazobactam versus imipenem/cilastatin for severe diabetic foot infections: a prospective, randomized clinical

trial in a university hospital. *Infectious Diseases*. 2010; 16:1252-7. <https://doi.org/10.1111/j.1469-0691.2009.03067.x> PMID:19832720

22. De Vries MG, Ekkelenkamp MB, Peters EJ. Are clindamycin and ciprofloxacin appropriate for the empirical treatment of diabetic foot infections? *Eur J Clin Microbiol Infect Dis*. 2014; 33(3):453-6. <https://doi.org/10.1007/s10096-013-1977-7> PMID:24220766

23. Alavi A, Bader MS, Sibbald RG. Management of diabetic foot infections with appropriate use of antimicrobial therapy. *Clin Res Foot Ankle*. 2014:1-9. <https://doi.org/10.4172/2329-910X.S3-010>

24. Yadlapalli N., Vaishnar A., Sheehan P. Conservative management of diabetic foot ulcers complicated by osteomyelitis. *Wounds*. 2002; 14:31-35.

25. Embil JM, Rose G, Trepman E, Math MC., Duerksen F, Simonsen JN, et al. Oral antimicrobial therapy for diabetic foot osteomyelitis. *Foot Ankle Int*. 2006; 27(10):771-779. <https://doi.org/10.1177/107110070602701003> PMID:17054876