

Repair of Traumatic Arteriovenous Fistula of 24 Years

Duration

A Case Report

Hayder Sabeeh Nsaif MBChB, FIBMS (CTS)

Department of Surgery, College of Medicine, Babylon University, Babylon, Iraq

الخلاصة:

تعتبر إصابات الطلق الناري عالية السرعة إصابات خطيرة على الحياة عند حدوثها، إلا أن مضاعفاتها المزمنة قد تسبب تحدياً طبياً من ناحية العلاج و مقبولية النتائج وهذا ما نراه بوضوح عند دراسة الحالة الطبية التالية بتمعن.

Abstract

Background

Arteriovenous fistula (AVF) formation is an uncommon clinical manifestation of arterial trauma. A delayed diagnosis of AVF of 15 years had been reported, underscoring the potential for missing these injuries.

Patient Presentation

A fifty years old male presented with left lower limb heaviness and pain associated with leg swelling, color changes, ulcerations and offensive discharge with physical signs of traumatic AVF at site of previous trauma and vascular exploration

Results

Successful surgical repair of long standing left sided traumatic femoro-femoral fistula.

Conclusion

In long standing traumatic AVF, the final surgical procedure undertaken will ultimately be determined by peroperative findings whatever the initial preoperative plan was.

The Case

A fifty years old male presented with left lower limb heaviness and pain, mainly at the leg and foot, dull in nature , continuous, aggravated by walking and standing, associated with leg swelling, color changes with ulcerations and offensive discharge from the anteromedial aspect of the leg. His complaints started at 1991, but the whole complaints were mild and started to increase until recently when his symptoms started to interfere with his daily activities and work and this was first medical consultation for his problem and the date was April/ 2010.

Past surgical history revealed shell trauma to the lateral aspect of left upper thigh during the war at 1986, for which referral was done from Basrah city to Baghdad city (700 km) where certain vascular surgery was done three days post trauma, with no available data now relevant to the surgery undertaken with no postoperative follow up following discharge from hospital.

On examination, there was an obvious left anteromedial thigh scar of the previous surgery with original trauma scar lateral to it (Fig. 1), thrill and bruit over the femoral pulse site. The left leg was swollen, hyperpigmented with secondary varicosities over Greater Saphenous Vein distribution and ulcers with offensive discharge and crustations mainly over the shin with signs of stasis dermatitis and obvious skin infection (Fig. 2). Notably, there were no signs and/or symptoms neither of limb ischemia nor of heart failure.

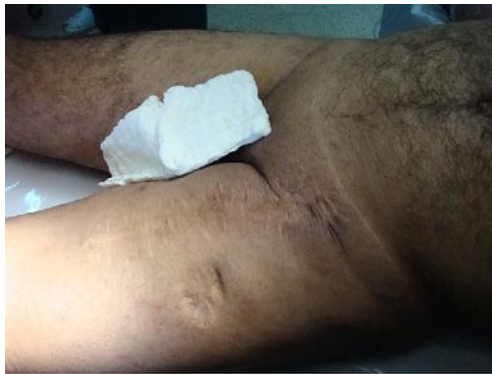

Figure 1

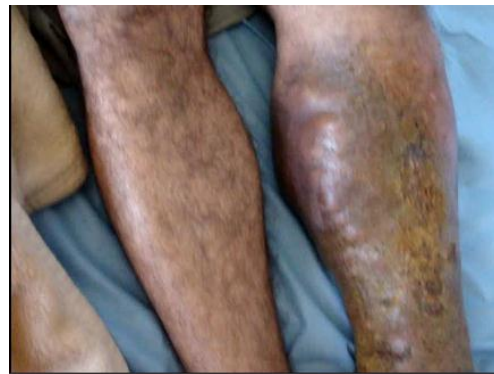

Figure 2

On investigations, Doppler study revealed presence of a fistula between common femoral artery and vein. Angiographic study further confirmed the presence of the fistula between common femoral artery and vein with cystic changes in the vein and its proximal parts and more dilated and tortuous artery proximally (fig. 3). Echocardiographic study revealed only a borderline LV hypertrophy and no signs of heart failure.

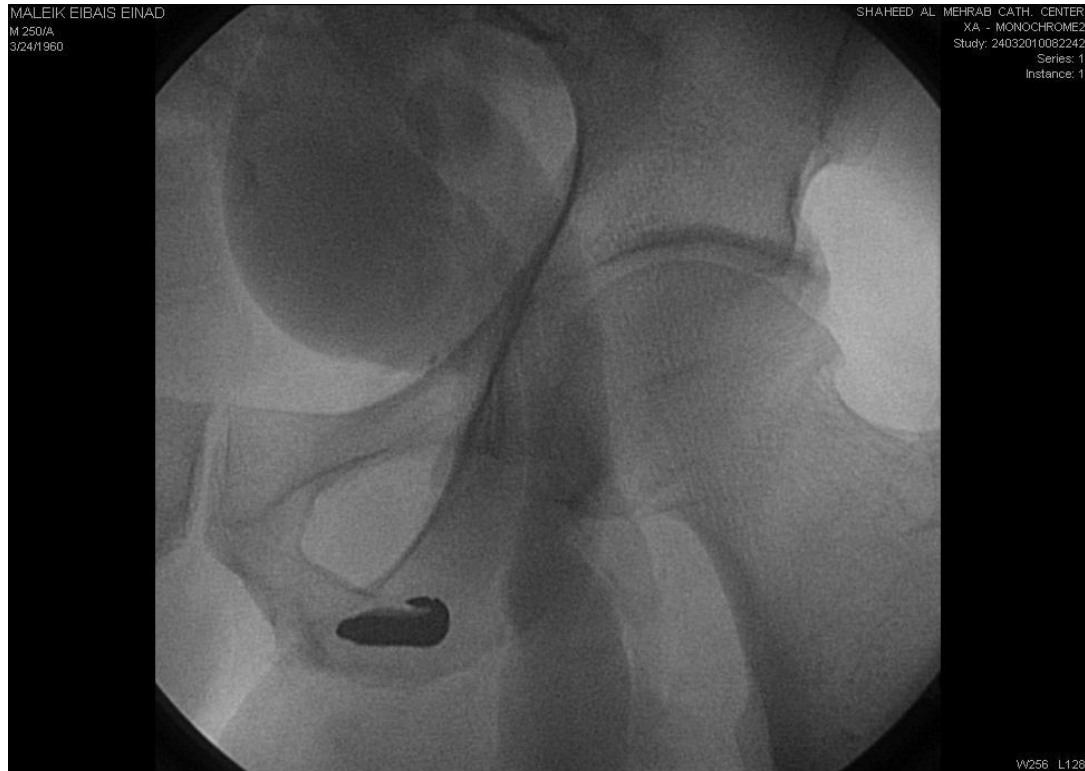


Figure 3

Management

Surgery performed on 23/05/2010, extended left anteromedial thigh incision was used in an attempt to control the four limbs of the fistula. Our main aim was to directly suture and closes the fistula entering through the venous portion after control of its four limbs since the primary repair has been the gold standard treatment for accessible pathological fistulae¹. Unfortunately, after 3 hours of surgical adhesiolysis, all what we achieved is just proximal and distal control of the arterial limbs of the fistula; proximal arterial control achieved after retroperitoneal access to left external iliac artery. Attempts for identification of the venous limbs of the fistula were unsuccessful since the venous limbs were strongly encased by fibrous tissue both proximally and distally. Believing that further search for the venous limbs was unwise decision; we decided to change our surgical plan by bypassing the arterial segment of the fistula after its exclusion and ligation. This was achieved by anastomosing a synthetic Dacron graft end-to-side with the dilated common femoral artery (the proximal limb) and end-to-end with the mid superficial femoral artery (distal limb), keeping the venous component intact and in continuity. Surgical site was closed with insertion of a single Redivac drain (Fig. 4).

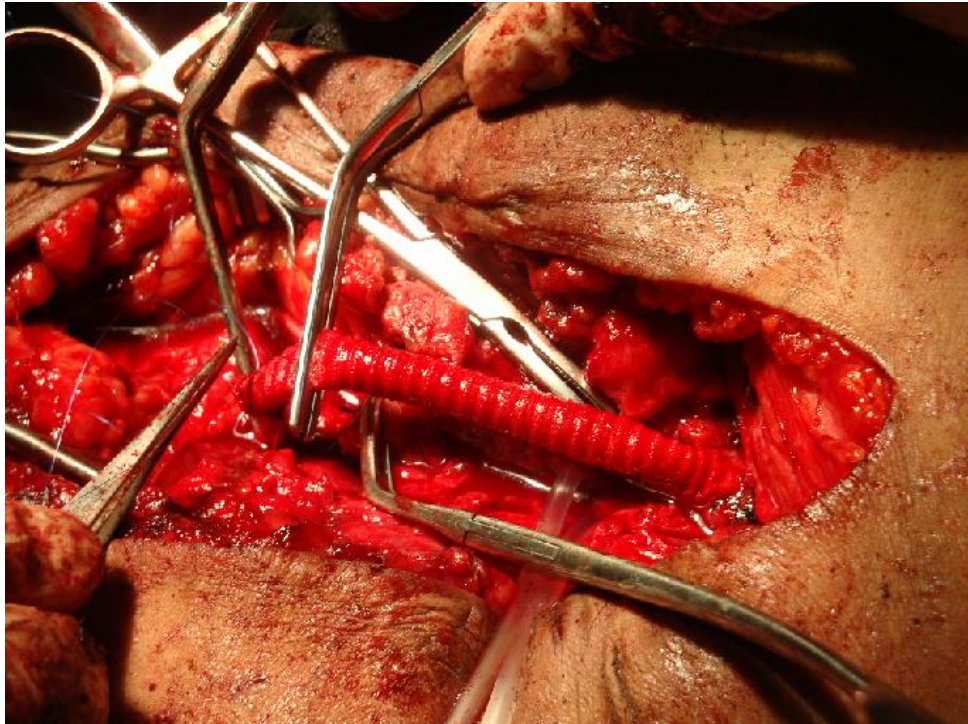


Figure 4

Postoperative course was uneventful apart from slight scrotal swelling at day one which was successfully managed conservatively .Drain removed 2 days later. Patient discharged home four days postoperatively on antibiotics and anticoagulants to be seen one week later.

Follow Up

Patient had been seen after 5 days from discharge. He presented with severe cellulitis, wound infection and dehiscence, but there were no signs of ischemia. Patient was admitted immediately on broad spectrum antibiotic cover, local care of the wound in preparation for wound exploration which was done 2 days later. On exploration, huge infected hematoma was evacuated with local tissue debridement. The graft itself showed no gross complications. Patient kept admitted with close observation. Wound left opened with the synthetic graft exposed (arrows in fig. 5 and 6) with daily change of dressing and heavy antibiotic cover. Wound culture yielded a polymicrobial infection of the surgical site.

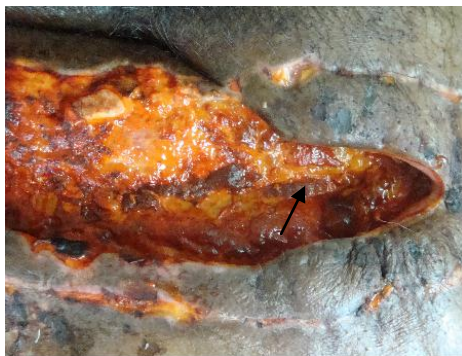

Figure 5

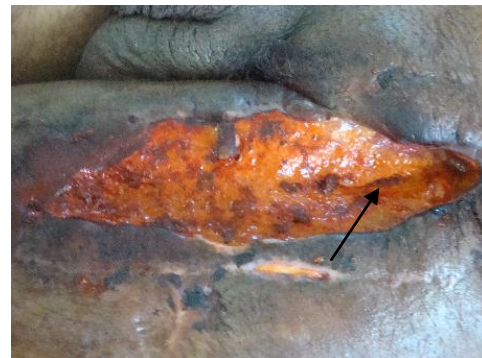

Figure 6

Accordingly, local care of the wound was empirical. Healing achieved by secondary intention (Fig. 6).

Long Term Follow Up

On regular follow up, complete healing of the wound occurred with marked improvement of chronic leg infections and gradual resolution of signs of chronic dermatitis and chronic edema as demonstrated in figures 7 and 8, both taken on 27/11/2010.

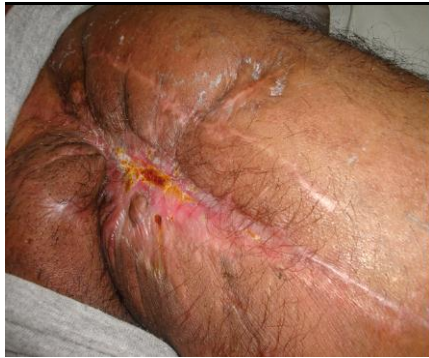

Figure 7

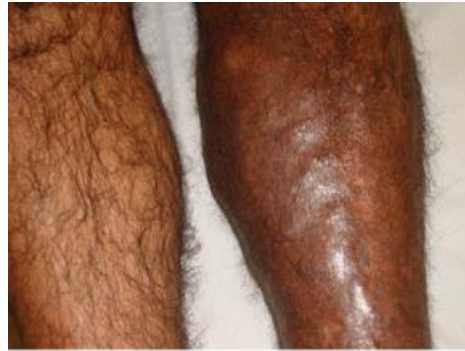

figure 8

On clinical examination there was no detectable thrill. Faint bruite continue to be present as it is an accepted finding according to our surgical approach. Follow up Doppler study on 27/11/2010 confirmed complete ablation of the fistula (Fig.9).

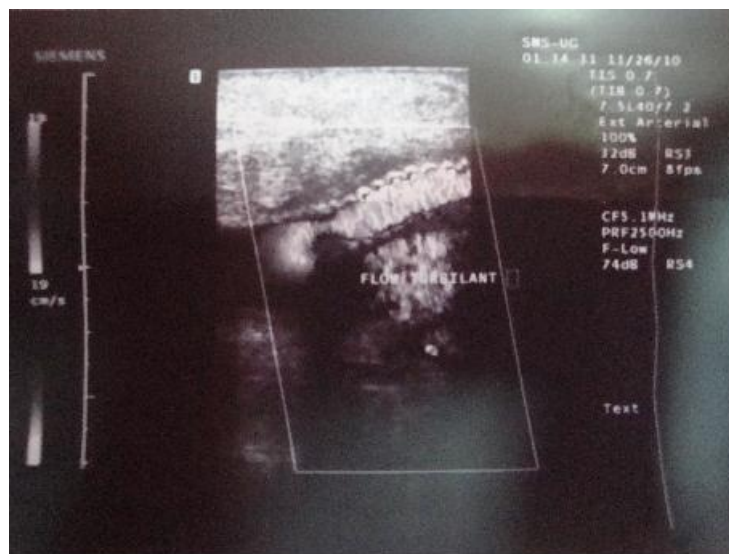

Figure 9

Discussion

The Case

Arteriovenous fistula formation is an uncommon clinical manifestation of arterial trauma. AVF have been reported after penetrating, blunt, and iatrogenic trauma²⁻⁶. In relation to our current case report, taking clinical history in consideration, we may suggest the following possible etiologies:

1. Traumatic, overlooked AVF from the start keeping in our mind that there was no preoperative angiographic assessment.
2. Traumatic AVF at time of presentation but with inadequate operative management.
3. Iatrogenic AVF complicating surgical vascular exploration or repair.

The most common anatomic sites of traumatic AVFs are the arteries of the neck and thoracic outlet (54%), AVFs in the upper (22%) and lower limbs (20%) are less common³, our case belong to the less common category. Delayed diagnosis of AVF of 15 years had been reported, underscoring the potential for missing these injuries^{3,7-11}, our case is even presented later.

About 20% of cases who presented with AVF greater than 1 week after injury manifest symptoms distant from the site of injury, including superficial venous dilatation (12%), congestive heart failure (4%), and pulsatile tinnitus (4%)³. Chronic AVF may induce venous hypertension in the affected extremity, producing edema, varicosities, static dermatitis, or venous ulceration^{3,11}. In our case the long term sequelae of raised venous pressure were so obvious. This classical clinical presentation coupled with the marked physical findings of thrill, machinery-like murmur associated with a remote history of vascular trauma suggested a provisional diagnosis of AVF. Confirmatory Duplex scan was done to confirm our clinical diagnosis since the ability of duplex ultrasonography to identify AVFs in anatomically accessible areas makes it the imaging test of choice¹³⁻¹⁵. Further angiographic assessment was done in order to precisely delineate any possible long term vascular changes because it is well reported that AVF persisting for several years induces dilatation and ectasia of the proximal artery with the corresponding vein becoming thick-walled and dilated¹⁶.

Management

The complexity of surgical repair of AVFs is often significantly greater than other types of arterial trauma and necessitates careful preoperative planning¹⁷. For that reason peer reviews was asked and in particular regarding the proximal control of the arterial portion of the fistula keeping in mind the possible need for laparotomy. Nevertheless, our approach started with anteromedial thigh incision. The operative approach to AVF repair should permit proximal and distal arterial control remote from the fistula because the immediate vicinity of the AVF may be encased in reactive fibrosis. Because of the venous hypertension, the dissection often is hindered by the presence of engorged veins that are prone to bleed with minimal provocation¹⁷, we were successful in achieving good arterial control both proximally at external iliac artery and distally at mid-superficial femoral artery without accidental vascular trauma. Arterial control should be accompanied simultaneously by proximal and distal venous control to minimize backbleeding from the fistula when the injured artery is explored. When the venous control is not feasible, control may be obtained within the fistula using digital pressure, sponge sticks, or balloon catheters until the venous injury is repaired¹⁶. Frustrating attempts to achieve venous control of fistula were unyielding secondary to extensive thick fibrosis caused by 2 important factors:

the previous vascular exploration and the long standing AVF. Although no accidental vascular injury was made, extensive thick fibrosis prevented direct closure of the fistula. An alternative option was exclusion and bypassing of the arterial fistulous portion combined with immediate arterial reconstruction following the basic principles of arterial repair. Arterial repair usually requires an interposition graft. The choice of conduit is based primarily on proper size match¹⁷. Accordingly an end-to-side anastomosis was performed at proximal arterial side (dilated common femoral artery) combined with an end-to-end anastomosis distally (distal end of mid superficial femoral artery after ligation of proximal end). The venous component of fistula was kept undisturbed.

Follow Up

Many factors contributed to the formation of such complications, the most important are:

1. Preoperative factors: impaired local defense mechanisms, pre-existing remote skin infection with discharge and possible bacteremia.
2. Peroperative factors: large wound, lengthy surgery, improper wound closure because of dense scar tissue, bleeding with insufficient drainage and use of synthetic implants.
3. Postoperative factors: probable early discharge, probable early removal of drain, delayed hematoma formation and poor home care due to low socioeconomic class.

Some of these factors are avoidable while others are not and I think most of the complications occurred because we were obliged to change our original plan and to use a synthetic material in such grossly abnormal surgical field.

Postoperative surgical exploration of the wound indicated a Szilagyi's infection of grade II (infection involving subcutaneous tissue)¹⁸ for which conservative measures were applied with perfect urgent facilities to interfere once there is anastomotic dehiscence, bleeding or ischemia. Secondary wound healing occurred after many weeks of conservative management as shown in fig.7.

Conclusion

The complexity of surgical repair of AVFs is often significantly greater than other types of arterial trauma and necessitates careful preoperative planning, but in long standing traumatic AVF, the final surgical procedure undertaken will ultimately be determined by peroperative findings whatever the initial preoperative plan was.

References:

1. H.H.G. Estacott, A.E. Thompson: Treatment of acquired arteriovenous fistulae. *Rob and Smiths Operative Surgery* 239, 1985
2. Rich NM, Hobson RW, Collins GJ: Traumatic arteriovenous fistulas and false aneurysms: A review of 558 lesions. *Surgery* 78:817, 1975.
3. Robbs JV, Karrim AA, Kadwa AM, Mars M: Traumatic arteriovenous fistula: Experience with 202 patients. *Br J Surg* 81:1296, 1994.
4. Snyder LL, Binet EF, Thompson BW: False aneurysm with arteriovenous fistula of the anterior tibial artery following fracture of the fibula. *Radiology* 143:405, 1982.
5. DeCasas R, Lazaro FJ, Garcia-Raygo MR, Arias J: Arteriovenous fistula after interlocking nailing of the femur: a case report. *J Trauma*38:303, 1995.
6. Wolford H, Peterson SL, Ray C, Morgan SJ: Delayed arteriovenous fistula and pseudoaneurysm after an open tibial fracture successfully managed with selective angiographic Embolisation. *J trauma* 51:781, 2001.
7. Escobar GA, Escobar SC, Marquez L, et al: Vascular trauma: late sequelae and treatment. *J Cardiovasc Surg* 21:35, 1980.
8. Linder F: Acquired arterio-venous fistulas: Report of 223 operated cases. *Ann Chir Gynaecol* 74:1, 1985.
9. Hegarty MM, Angorn IB, Gollogly J, Baker LW: Traumatic arteriovenous fistulae. *Injury* 7:20, 1975.
10. Perry MO: Complications of missed arterial injuries. *J Vasc Surg* 17: 399, 1993.
11. Erdol C, Baykan M, Goyce M, et al: Congestive heart failure associated with chronic venous insufficiency and leg ulcers secondary to an arteriovenous fistula caused by a shotgun wound 15 years ago. *Vasa* 31:125, 2002.
12. Kent KC, McArdle CR, Kennedy B, et al: A prospective study of the clinical outcome of femoral pseudoaneurysm and arteriovenous fistulas induced by arterial puncture. *J Vasc Surg* 17:113, 1993.
13. Allen BT, Munn JS, Stevens SL, et al: Selective non-operative management of pseudoaneurysm and arteriovenous fistulae complicating femoral artery catheterization. *J Cardiovasc Surg* 33:440, 1992.
14. Toursarkissian B, Allen BT, Petrinec D, et al: spontaneous closure of selected iatrogenic pseudoaneurysm and arteriovenous fistulae. *J Vasc Surg* 25:805, 1997.
15. S. Martin Lindenauer: Acquired arteriovenous fistula. *Current Therapy in Vascular Surgery*.842, 1995.
16. John G. Brawley, J. Gregory Modrall: Traumatic Arteriovenous Fistulas. *Rutherford Vascular Surgery*. 112: 1619, 2005.
17. Szilagi DE, Smith RF, Elliott JP, et al: infection in arterial reconstruction with synthetic grafts. *Ann Surg* 176: 321, 1972.