



The Patho-Histological Change of Fetus Amniotic Sac as a Result of Bacterial Infection

Sura I. A. Jabuk¹, Susan I. A. Jabuk², Rasha J. alwarid³, Raflaa S.H. Hussein¹

¹University of Babylon, College of Science, Department of Biology, Babylon, Iraq.

²Al hilla Teaching Hospital Babylon Health Directorate

³University of Babylon, College of Dentistry, Department of microbiology, Babylon, Iraq.

Abstract

Amniotic fluid is defined as a transparent liquid that is present in the uterus during pregnancy. In this study obtain 100 sample of vaginal swaps(50 from normal birth and 50 from caesarean), 100 samples of amniotic fluid (50 samples from normal birth and 50 samples from caesarean) from pregnant women revision born lounge in Hilla teaching hospital, and 50 samples of amniotic sac from the caesarean women to made histological section. The result showed the number of positive swaps of bacteria was 81 (81%) , while positive samples from amniotic fluid was 74 (74%) from the total 100 sample and present relationships between vaginal infection and the present of bacteria in the amniotic fluid .The type of aerobic bacteria isolated was *Escherichia coli* ,*Pseudomonas aeruginosa*, *Bacillus subtilis*, *Klebsiella pneumonia*, *Staphylococcus epidermidis*, *Staphylococcus aureus*, *Streptococcus mutans*, *Proteus mirabilis* and anaerobic bacteria was *Peptostreptococcus sp.* *Neisseria gonorrhoeae*, *Lactobacillus sp.* and *Actinomyces sp.* were isolated from amniotic fluids and vaginal swabs. then injection the same bacteria isolated in mice and made histological section from mice amniotic sac. Cross section of amniotic tissues in both of women and mice showed infiltration of lymphocyte, hemorrhage and elongation of epithelial cell as a result of bacterial infection.

Keywords: *Amniotic fluid, Amniotic sac, Caesarean, Vaginal infection. In vitro, In vivo.*

Introduction

Amniotic fluid is defined as a transparent liquid that is present in the uterus during pregnancy. The fetus grows within this sac for 9 months and surrounding with the amniotic fluid (1).

The important of amniotic fluid during the pregnancy period is:

- Protects the fetus from exposure to microbial infection.
- Protects the fetus from any trauma.
- Helps to complete the growth of the fetal lungs(2).
- Helps to grow fetal muscles and bones.
- Maintains a normal temperature so that the fetus does not feel hot or cold.

- Help the fetus to move freely without any difficulty (3).

The amount of fluid in often reaches one liter, but this amount increased (Polyhydramnios) or decreased (Oligohydramnios) belong to the number of reasons, In both cases you should make sure to see the doctor routinely to make sure your pregnancy is well and the fetus is growing without any abnormal problems (1).

In both cases, high or low amniotic fluid may be a sign of fetal suffering from certain congenital malformations, a rupture of fetal membranes or certain problems in the placenta and other causes (3). The amniotic fluid is free from microorganisms, but it is exposed to contamination when the pregnant

mother suffers of repeated vaginal infections during pregnancy lead to the present microorganism in the amniotic fluid (2).

The Aim of this Study was

- Isolated and identification of bacteria from amniotic fluids and vagina.
- Study the relationships between vaginal infection and the present of bacteria in the amniotic fluids *in vivo* and *in vitro*.
- Study the patho-histological change of the fetus amniotic sac of women and mice

Material and Method

Vaginal Swaps

Obtain 100 vaginal swaps from pregnant women (50 from normal birth and 50 from caesarean) and taken to the microbiology laboratory to identification the isolated bacteria (4).

Amniotic Fluids

Obtain 100 samples of amniotic fluid from pregnant women revision born lounge in Hilla teaching hospital by using sanitizer and clean container (50 from normal birth and 50 from caesarean) and taken to the microbiology laboratory to identification the isolated bacteria (1).

Identification of Bacteria

The sample cultured on the different media (MacConkey's agar, Blood agar, Eosin methylene blue agar, chocolate agar and Brain-Heart Infusion agar plates) under aerobic and anaerobic condition, then investigations the bacteria isolated by using different biochemical test and gram's stain(4).

Amniotic Sac Collection

Obtain 50 samples from the amniotic sac from caesarean of the fetus in the tube contain formal saline and then made the histological section to study the histological change (3).

Experimental Mice

Eight female and three male mice were selected at the age of 2-3 months and each two females were crossed with one male and two female mice as control. Visible of vaginal plug designated as indicator on mating, which was considered the first day of pregnancy. After one week, the female mice were injection by intra-vaginal with bacterial suspension (*E.coli* & *N. gonorrhoeae*) contain about 10^5 cell / ml, in addition to control mice injected with normal saline solution, after about 7 days of injection, the pregnant mice were dissected and re-isolated of bacteria from amniotic fluid, then a part of the amniotic sac was placed in the formal saline solution until tissue sections were made to study tissue changes due to bacterial infection compared with control mice(5).

Statistical Analysis

Statistical analysis was performed by using SPSS statistical computer software.

Result and Discussion

The result showed the number of positive swaps of bacteria was 81 (81%) from the total 100 sample (5) Statistical analysis showed significant difference between positive and negative samples figure (1).The similar result obtain by Jabuk, *et al.*, (6). The result showed the number of positive samples of bacteria isolated from amniotic fluid was 74(74%) from the total 100 sample and present the number of positive sample in age 21-25 was 20 (20%) from total 32 (32%) more than anther age figure (2) Statistical analysis showed significant difference between positive and negative samples.

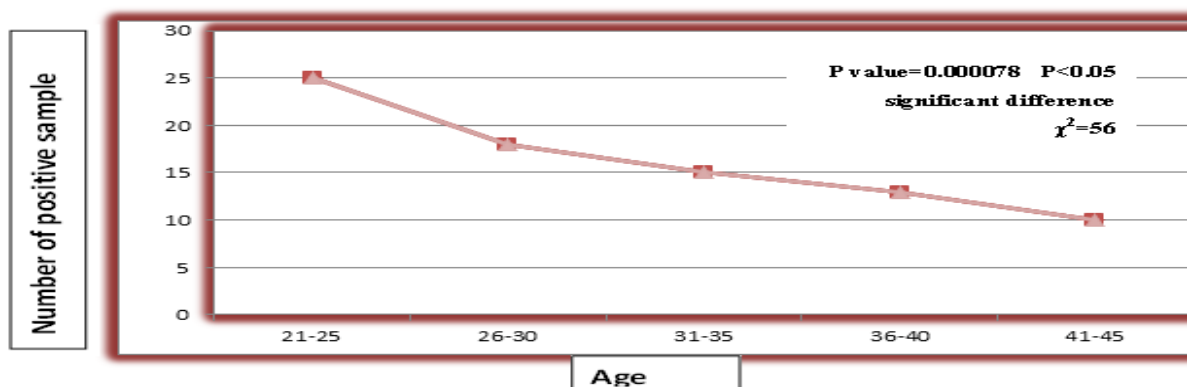


Figure 1: The number of positive vaginal swabs sample according to the age

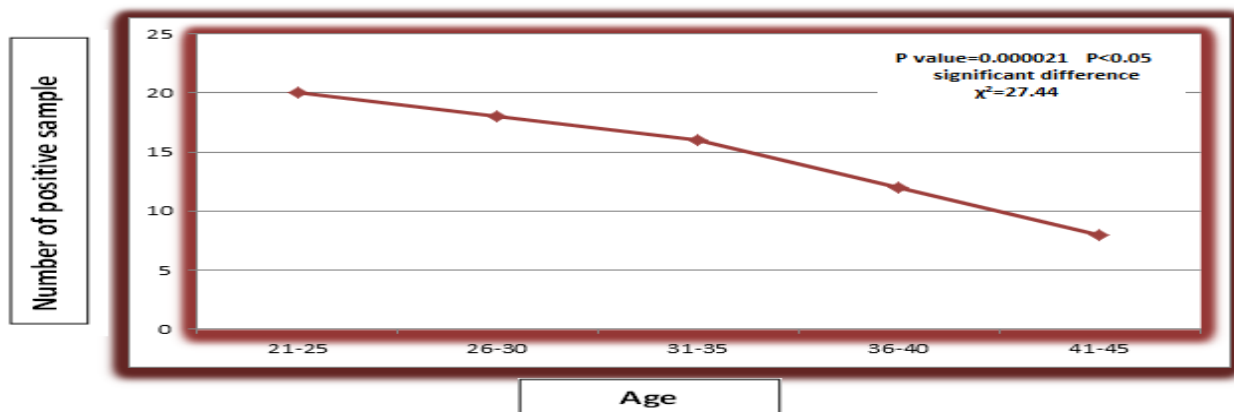


Figure 2: The number of positive amniotic fluid sample according to the age

When taken the sample of amniotic fluid present that 56 % normal amniotic fluid, 28 % polyhydramnios and 16 % oligohydramnios from the total 100 samples table (1) Statistical analysis showed

significant difference between them . The same result obtain from Tasneem *et al.*, (7) when present the percentage of normal amniotic fluid was 59 more than another type (oligohydramnios 20% and polyhydramnios 21%).

Table 1: Distribution the amount of amniotic fluid according to the age

Nature of Amniotic fluid	Normal AFI	Polyhydramnios	Oligohydramnios	Total No.(%)
No. of positive samples (%)	37(37)	23(23)	14(14)	74(74)
No. of negative samples (%)	19(19)	5(5)	2(2)	26(26)
Total No.(%)	56(56)	28(28)	16(16)	100(100)

P value=0.0018P<0.05 significant difference $\chi^2=49.04$

When observed the nature of amniotic fluid present that 22% clear ,36 thick and 48 % thin from the total number Table (2). Statistical analysis showed significant

difference between the nature type of amniotic fluid while Tasnee *metal.* (7) present the percentage of clear type more anther type.

Table 2: The number and percentage of positive and negative samples according to the nature of amniotic fluid

Nature of Amniotic fluid	Thin	Thick	Clear	Total No. (%)
No. of positive samples (%)	34 (34)	24(24)	16(16)	74(74)
No. of negative samples (%)	8(8)	12(12)	6(6)	26(26)
Total No. (%)	42(42)	36(36)	22(22)	100(100)

P value=0.0000024 P<0.05 significant difference $\chi^2=33.92$

The culture ,microscopic and biochemical test diagnosis number of aerobic and anaerobic type of bacteria isolated from vaginal swap and amniotic fluid of the pregnant women list in table (3) similar the result obtain by jabuk, S.I. (8) .

isolated and number of genus *N. gonorrhoeae* more than another type of anaerobic bacteria (9).George *et al.*, (10) also present the number of isolated *E. coli* more than another type. The result showed the women under go repeating vaginal infection by bacteria contain the same bacteria in the amniotic fluid surrounding the fetus during the pregnancy.

The result showed the number of genus *E.coli* more than another type of aerobic bacteria

From this we conclude the present of the vaginal infection (11).
bacteria in the amniotic fluid as a result of

Table 3: The type and number of bacteria isolated from vaginal swap and amniotic fluid of the pregnant women

Type of bacteria	NO. of bacteria isolated from vagina	NO. of bacteria isolated from amniotic fluid
Aerobic		
<i>Escherichia coli</i>	30	25
<i>Pseudomonas aeruginosa</i>	7	0
<i>Bacillus subtilis</i>	10	8
<i>Klebsiella pneumoniae</i>	14	10
<i>Staphylococcusepidermidis</i>	15	12
<i>Staphylococcus aureus</i>	24	18
<i>Streptococcus mutans</i>	10	0
<i>Proteusmirabilis</i>	11	8
Anaerobic		
<i>Peptostreptococcus sp.</i>	9	5
<i>Neisseria gonorrhoeae</i>	11	8
<i>Lactobacillus sp.</i>	5	0
<i>Actinomyces sp.</i>	7	1

The histological section of amniotic sac showed the present many pathological change such as infiltration of lymphocyte, hemorrhage and elongation of epithelial cell (Figure 1,2). This pathological change as a

result of different virulence factor produced from the isolated bacteria such as toxin (enter toxin & exotoxin), hemolysis, adherence compare with the amniotic tissue prepared from non-infected women (12).

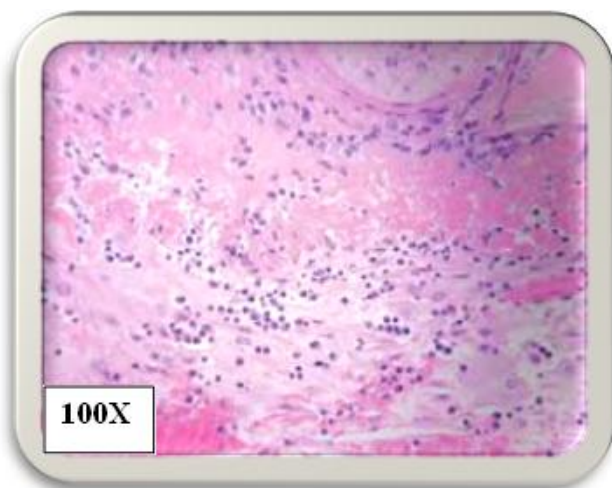


Figure 1: Cross section of women amniotic tissue showed infiltration of lymphocyte staining with hematoxylin and eosin

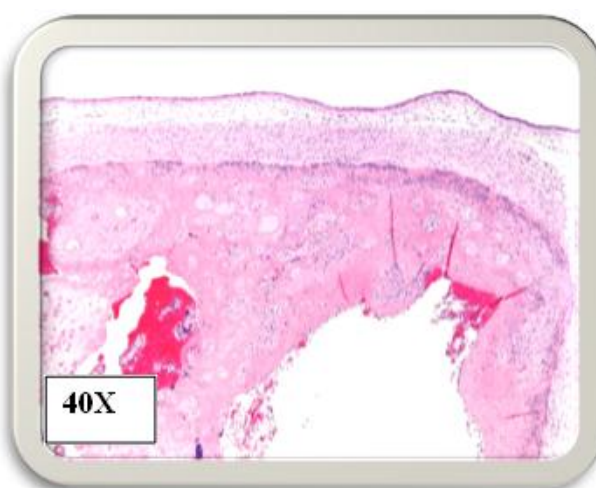


Figure 2: Cross section of women amniotic tissue showed hemorrhage staining with hematoxylin and eosin

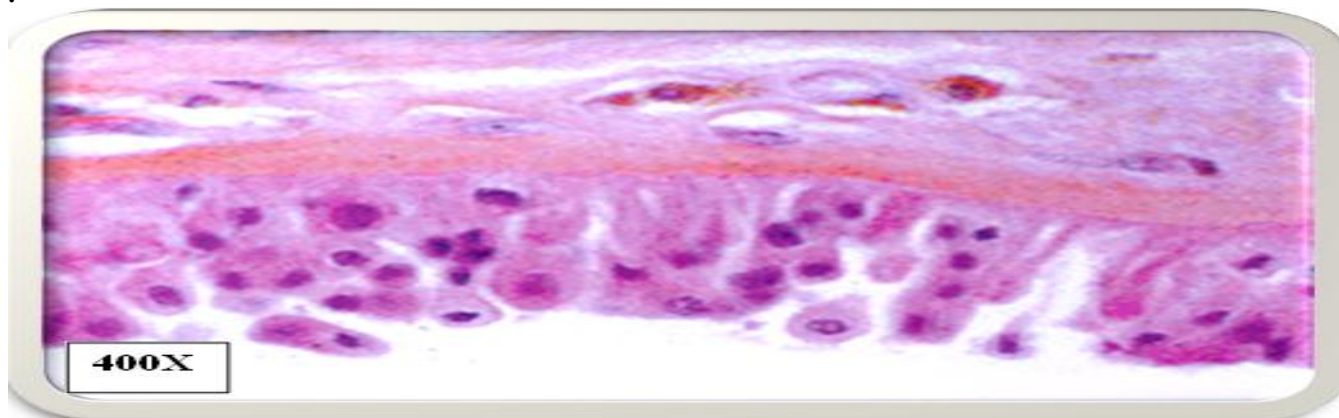


Figure 3: cross section of women amniotic tissues showed elongation of epithelial cell staining with hematoxylin and eosin.

After 1 week from intra-vaginal injection of mice by *E.coli* and *N. gonorrhoeae* kill the mice and dissecting, then re isolated of bacteria from amniotic fluid and present the histological change in the amniotic sac after made the histological section showed in picture (4,5) compare to the normal amniotic sac (control) (Figure 6). This pathological

change as a result of different virulence factor produced from the intra-vaginal injection bacteria (*E.coli* and *N. gonorrhoeae*) such as toxin (enter toxin & exotoxin), hemolysis, adherence compare with the amniotic tissue prepared from non-infected mouse (control) (13,14).

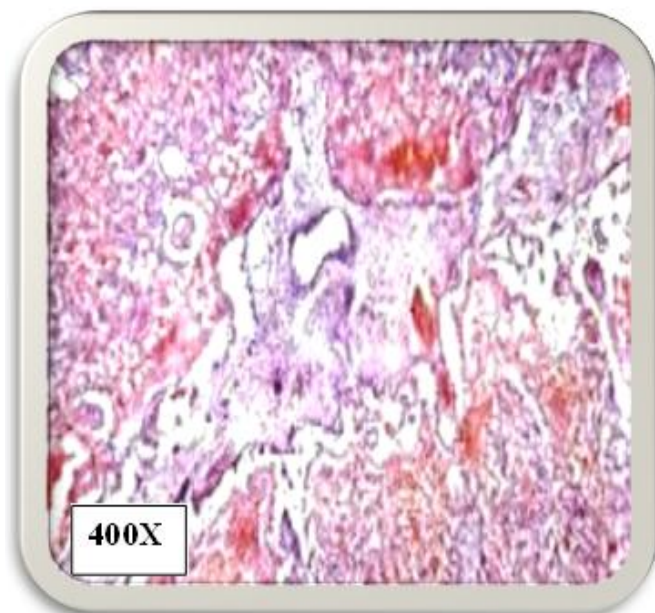


Figure 4: Cross section of mice amniotic tissues showed hemorrhage and staining with hematoxylin and eosin.

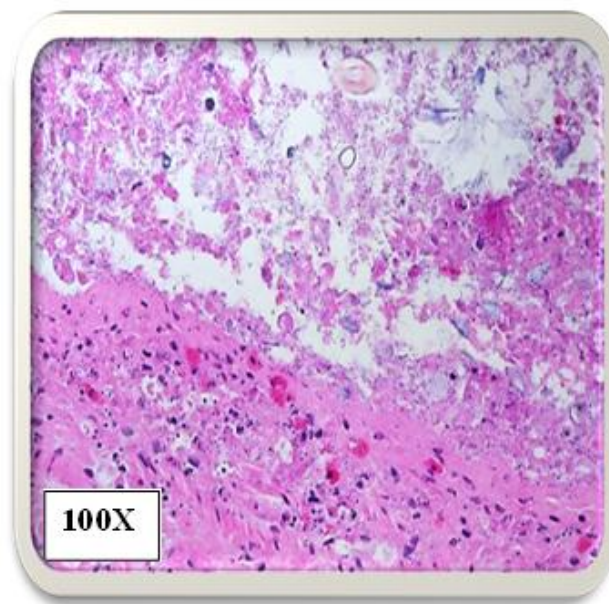


Figure 5: Cross section of mice amniotic tissues showed infiltration of lymphocyte staining with hematoxylin and eosin.

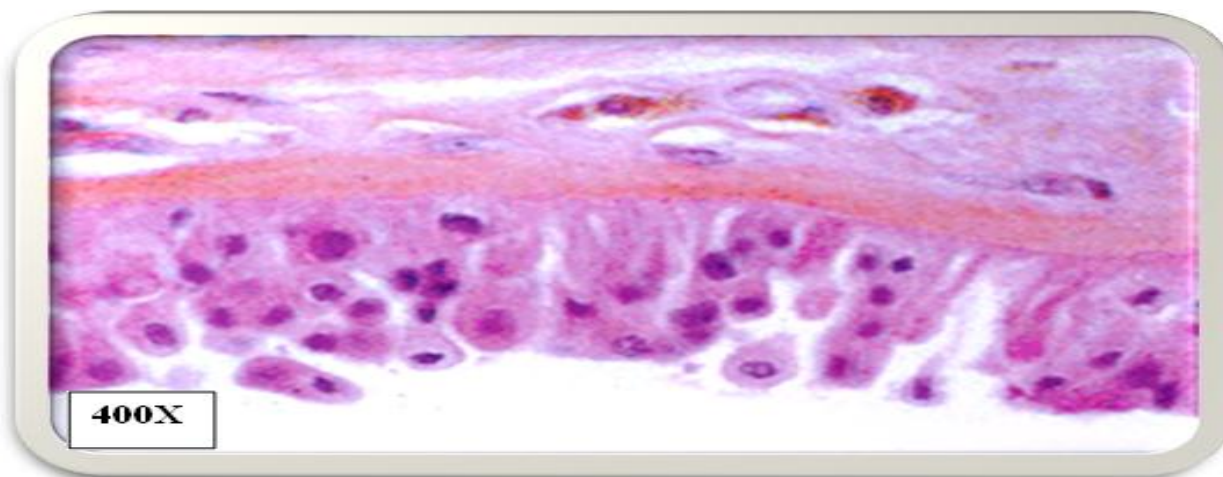


Figure 6: cross section of normal mice amniotic tissues (normal) staining with hematoxylin and eosin.

References

1. Aesha, P Pate HV (2014) Role of amniotic fluid index in pregnancy. I.A.I.M. 2(8)1-12.
2. Roberto R, Christoph S et al (2008) Detection of a microbial bio film in intra-amniotic infection Am. J. Obstet. Gynecol. 198(1): 130-135.
3. Xing-Long T Ling, W Tan-Bi (2009) Potential Function of Amniotic Fluid in Fetal Development—Novel Insights by Comparing the Composition of Human Amniotic Fluid with Umbilical Cord and Maternal Serum at Mid and Late Gestation. J. Chin. Med.Assoc.72 (7):368-373.
4. Jabuk SI (2014). Prevalence of aerobic bacterial vaginosis among Intrauterine Contraceptive Device user's women in Hilla city. J. of Bab. Uni./P. and App. Sci. 22(9): 2424-2431.
5. BayatP, Eslamirad Z, Shojaee S (2013) Toxoplasmosis: Experimental Vaginal Infection in NMRI Mice and Effect on Uterin, Placenta and Fetus Tissues. Iran Red Cres Med J. 15(7).

6. Jabuk SIA, Hussian R, SH Jabuk SIA (2014) Different method for diagnosis bacterial vaginosis in married woman in Hilla city. IOSR-JDMS. 13 (12): 46–51.
7. Tasneem SA, Ashwini K, Muhammad K, Farquana Q (2014) A Study of Amniotic Fluid Index in Term Pregnancy Int.J.CurrRes.Aca.Rev.2 (11): 147-152.
8. Jabuk SI (2013).Asymptomatic Bacteriuria and Pyuria in pregnant women in Hilla city: Causative agents and Antibiotic sensitivity .J. of Baby. Uni. /Pur. and App. Sci. 8(21)
9. Kahraman k, İsa A (2011) The Relation of In trapartum Amniotic Fluid Index to Perinatal Outcomes. J. Med. Sci. 1(1):1–7.
10. Karl E, Miller MD (2006) Diagnosis and Treatment of Neisseriagonorrhoeae Infections. Am. Fam. Physician. 73(10):1779-1784.
11. George L, Mendz N, Kaakoush, Julie AQ (2013) Bacterial a etiological agents of intra amniotic infections and preterm birth in pregnant women. Fron. Cell. And Infec. Micro. 3(58): 1-7.
12. Melike BY, Emine S, Osman S, Yusuf P (2012) Comparison of aerobic conjunctival bacterial flora in pregnant, reproductive -aged and postmenopausal women. 5(6):731-736 .
13. Xiwen H, Jiangchao L, Qianqian Z, Lingyun Z, Lijing W (2016) Phosphoinositide 3-Kinase (PI3K)Subunit p110δ Is Essential for Trophoblast Cell Differentiation and Placental Development in Mouse.Scient.Rep.1-12.
14. Hassan N, Habibollah P, Masoumeh J, Abolhassan A, Jalal G Alexander, Seifalian M (2008) Properties of the amniotic membrane for potential use in tissue engineering .Eur. cell and material .15:88-99.

Appendix

Table 1: The number and percentage of bacterial isolated from vaginal swabs according to the age

Age	No of Negative (%)	No of positive (%)	Total No. (%)
21-25	9(9)	25(25)	34 (34)
26-30	5(5)	18(18)	33(33)
31-35	3(3)	15(15)	18(18)
36-40	1(1)	13(13)	14(14)
41-45	1(1)	10(10)	11(11)
Total No.(%)	19(19)	81(81)	100 (100)

P value=0.000078 P<0.05 significant difference

$\chi^2=56$

Table 2: The number and percentage of bacterial infection in amniotic fluid samples according to the age

Age	No of Negative samples (%)	No of positive samples (%)	Total No.(%)
21-25	12(12)	20(20)	32 (32)
26-30	8(8)	18(18)	26(26)
31-35	4(4)	16(16)	20(20)
36-40	2(2)	12(12)	14(14)
41-45	0(0)	8(8)	8(8)
Total No.(%)	26(26)	74(74)	100 (100)

P value=0.000021 P<0.05 significant difference

$\chi^2=27.44$