

Biochemical and Histopathological Changes Caused by Atorvastatin in Gentamicin Treated Rats

Fatima Adnan Alzubaidi¹, Radhwan M. Hussein², Zainab Sajid Mohammed³,
Enass Najem Oubaid⁴

¹Department of Pharmacology and Toxicology, College of Pharmacy, University of Babylon. Iraq.

²College of Pharmacy /University of Ahl AL-Bayt. Iraq.

³College of Pharmacy /University of Ahl AL-Bayt. Iraq.

⁴Department of Pharmacology and Toxicology, College of Pharmacy, University of Babylon. Iraq.

Received: 04th July, 19; Revised: 06th August, 19, Accepted: 07th September, 19; Available Online: 25th September, 2019

ABSTRACT

Introduction: Gentamicin is a member of the antibiotic group (aminoglycosides), it's very effective in the management of many gram-negative bacterial infections, but its nephrotoxic effect is considered the major limiting factor. The protective role of Atorvastatin against this adverse effect in male rats was investigated in this study.

Materials and methods: Thirty adult Wistar male rats were included in the study, they were divided into 3 groups randomly with ten rats in each one, rats in group (1) were given normal standard diet and considered as control. Rats in Group 2 were given gentamicin in a dose of 100 mg per kg per day, intraperitoneally for four weeks, while rats in Group 3 were given gentamicin in a dose of 100 mg per kg per day, intraperitoneally together with atorvastatin 10 mg/kg/day orally for four weeks.

Results: treatment with Gentamicin elevated the level of serum urea, cystatin C, creatinine, total oxidant status, and tissue malondialdehyde (MDA) significantly while decreased total antioxidant status significantly. Treatment with Atorvastatin reduced the level of serum urea, creatinine, total oxidant status, and tissue MDA significantly while increased total antioxidant status significantly. Renal damage in gentamicin treated rats was determined markedly with histopathological studies in the glomeruli and renal tubules.

Conclusion: coadministration of statins with gentamicin can reduce the nephrotoxicity induced by gentamicin treatment.

Keywords: Antioxidant status, Atorvastatin, Gentamicin, Renal function and Total oxidant.

International Journal of Pharmaceutical Quality Assurance (2019); DOI: 10.25258/ijpqa.10.3.1

How to cite this article: Alzubaidi, F.A., Hussein, R.M., Mohammed, Z.S. and Oubaid, E.N. (2019). Biochemical and histopathological changes caused by Atorvastatin in Gentamicin treated rats. International Journal of Pharmaceutical Quality Assurance 10(3): 105-109.

Source of support: Nil

Conflict of interest: None

INTRODUCTION

Gentamicin is one of the Aminoglycoside antibiotics that are commonly used in the treatment of many serious gram-negative bacterial infections. They are bactericidal against most gram-negative bacteria including Enterobacter, Klebsiella, Salmonella, Escherichia coli, Proteus, Pseudomonas, Serratia, and Shigella. They also have a synergistic effect against gram-positive organisms such as Staphylococcus epidermidis.¹ The antibacterial activity of aminoglycosides results from inhibition of protein synthesis in the bacteria through binding to the 30s ribosomal subunit irreversibly.²

Gentamicin usually induced nephrotoxicity and renal function impairment,^{3,4} the specific mechanism of gentamicin induced nephrotoxicity may be due to the accumulation of gentamicin in the proximal convoluted tubules that impairs mitochondrial function, affects tubular transport, increases

oxidative stress and forms free radicals that mostly results in kidney atrophy. These changes are usually reversible, but long term treatment with gentamicin can result in irreversible renal injury.⁵

Atorvastatin which is one of the drug class statins is a competitive inhibitor of HMG-CoA reductase enzyme; the rate-limiting step in cholesterol synthesis, therefore it is indicated for lowering blood cholesterol level and preventing cardiovascular disease through its anti-inflammatory effect that plays a role in plaque stabilization and prevention of strokes.^{6,7} Statins have additional effects, called 'pleiotropic effects' which involve anti-inflammatory, anti-oxidant, anti-proliferative, pro-apoptotic and antifibrotic effects as well as improving renal hemodynamics so that these effects can protect the diseased kidney depending on the pathophysiological mechanism of renal damage and the stage of progression.^{8,9}

The aim of the study was to investigate the possible protective effect of atorvastatin on gentamicin-induced renal toxicity in the rat model.

MATERIALS AND METHODS

A total of 30 mature Wistar male rats (100–150 g) were included in this study. The animals were taken from the Animal House of the College of Medicine, University of Kufa and kept in polypropylene coops in the Animal House, College of Medicine, University of Babylon at temperature (25 ± 2°C). Rats were allowed to access a commercial pellet diet and water ad libitum freely. The Protocol of this study was approved by the Local Research Ethics Committee in the College of Pharmacy, University of Babylon, and in agreement with International Requirements of the Experimental Animal Research. The rats were left 1-week for adaptation then divided into three groups randomly, each group with ten rats, as in the following: Group 1 rats were given normal standard diet and considered as a control group. The baseline values of all measured parameters were obtained from this group. Group 2 rats were given gentamicin 100 mg/kg/day (Megental [Menarini International; Italy]), intraperitoneally for four weeks.¹⁰ Group 3 rats were given gentamicin in a dose of 100 mg/kg/day intraperitoneally together with Atorvastatin 10 mg per kg per day orally, by gavage tube, (Atorvastatin Sandoz; Australia) for four weeks.¹¹ After the 4 weeks blood samples were obtained from all rats to determine the experimental parameters which include serum level of urea, creatinine, cystatin C, total antioxidant status (TAS), total oxidant status (TOS) and tissue malondialdehyde (MDA) (considered as one of the lipid peroxidation end-products in the cells) in addition to histological study for kidney. Rats underwent laparotomy under chloroform anesthesia and 3 mL of blood was taken from the heart directly, the blood samples were left for 30 minutes in serum tube to stand and clot, then centrifuged at 3000 rpm for 10 minutes, and the experimental parameters were measured from the resulted serum.

The two kidneys also were isolated from every rat, the first one was maintained in formalin 10% to study the histopathological changes and the second one was washed with ice-cold 0.9% saline to remove any RBCs or clot, then was stored in deep freezer at -80°C to measure tissue concentration of MDA according to Tomotsu et al. method.

DETERMINATION OF SERUM PARAMETERS

Estimation of urea was performed depending on the procedure provided with the kit from the Biomerieux company, creatinine was determined depending on the procedure supplied with the kit from Syrbio company.¹³⁻¹⁶ Serum cystatin-C was estimated using Enzyme-Linked Immunosorbent Assay (ELISA) method. Kits that are commercially available were used for determination of TAS and TOS, according to Erel, O. methods.¹⁷

HISTOPATHOLOGICAL STUDY

Paraffin-embedded histological sections of a kidney that were stained with hematoxylineosin and prepared according

to Bancroft and Steven method. Then a light microscope was used to examine them and determine the changes in the tubules and glomeruli. The diameters of the glomeruli and renal tubules were measured using Ocular micrometer and stage micrometer.¹⁸

STATISTICAL ANALYSIS

By using Statistical Package for Social Science (SPSS 24 IBM, Armonk, United state America), the results were expressed as mean ± standard error of mean (SEM), all the differences in means of the variables between control and gentamicin group, and Gentamicin with atorvastatin group were analyzed by analysis of variance (one way ANOVA) test. A significant difference was set at a p-value of < 0.05.

RESULTS

The mean ± SEM of creatinine for control, gentamicin, and gentamicin with atorvastatin, groups were 0.77 (± 0.03) mg/dL, 1.27 (± 0.04) mg/dL, 0.79 (± 0.02) mg/dL, respectively. ANOVA showed a very high significant elevation (p < 0.001) in the mean of creatinine in the gentamicin group in comparison with control and Gentamicin with atorvastatin groups, as shown in Figure 1.

The mean ± SEM of urea for the control group, gentamicin group, and gentamicin with atorvastatin group were 37.76 (± 2.45) mg/dL, 72.43 (± 2.84) mg/dL, 38.91 (± 0.59) mg/dL, respectively. ANOVA showed very high significant elevation (p < 0.001) in urea mean in gentamicin group in comparison with (control and Gentamicin with atorvastatin groups) as shown in (Figure 1).

The mean ± SEM of Cystatin c for the control group, gentamicin group, and Gentamicin with atorvastatin group were 0.86 (± 0.04) mg/L, 2.23 (± 0.13) mg/L, 0.9 (± 0.01) mg/L respectively. ANOVA showed very high significant elevation (p < 0.001) in the mean of Cystatin c in gentamicin group in comparison with (control and Gentamicin with atorvastatin groups) as shown in (Figure 1).

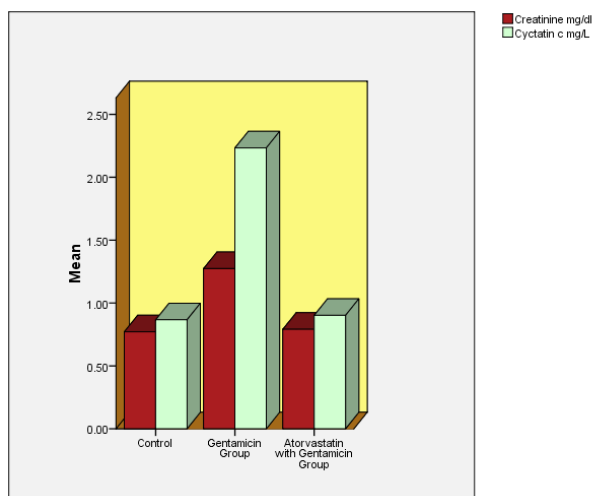


Figure 1: Mean ± SEM for creatinine and cystatin c in the control group, gentamicin group, and Gentamicin with atorvastatin groups.

The mean \pm SEM of MDA for control group, gentamicin group, and Gentamicin with atorvastatin group were 0.76 (\pm 0.03) nmol/mg, 2.5 (\pm 0.1) nmol/mg, 0.88 (\pm 0.01) nmol/mg, respectively. ANOVA showed very high significant elevation ($p < 0.001$) in the mean of MDA in the gentamicin group in comparison with (control and Gentamicin with atorvastatin groups) as shown in Figure 2.

The mean \pm SEM of TAS for the control group, gentamicin group, and gentamicin with atorvastatin group were 4.59 (\pm 0.16) mmol Trolox Equiv. Per L, 2.32 (\pm 0.2) mmol Trolox Equiv. per L, 4.24 (\pm 0.07) mmol Trolox Equiv. Per L, respectively. ANOVA showed a very high significant decrease ($p < 0.001$) in the mean of TAS in the gentamicin group in comparison with (control and Gentamicin with atorvastatin groups) as shown in Figure 2.

The mean \pm SEM of TOS for the control group, gentamicin group, and gentamicin with atorvastatin group were 10.92 (\pm 0.29) μ mol H₂O₂ Equiv./L, 17.94 (\pm 0.45) μ mol H₂O₂

Equiv./L, 10.63 (\pm 0.17) μ mol H₂O₂ Equiv./L, respectively. ANOVA showed very high significant elevation ($p < 0.001$) in the mean of TOS in the gentamicin group in comparison with (control and Gentamicin with atorvastatin groups) as shown in Figure 2.

RESULTS OF HISTOPATHOLOGICAL EXAMINATIONS

Figure 3 represents the histological micrographs of kidney from the control group (Group I), which revealed normal histology.

Gentamycin administrations to rats result in glomerular dilation, mild glomerulonephritis, congestion in addition to necrotic cells that are seen among the tissue with brush border loss and dilation of the interstitial connective tissue among renal tubules with enlargement, abnormal morphology of renal tubules, with the regenerative process (Figure 4).

Treatment with atorvastatin revealed a significant degree of protection for the tubules and glomeruli Figure 5.

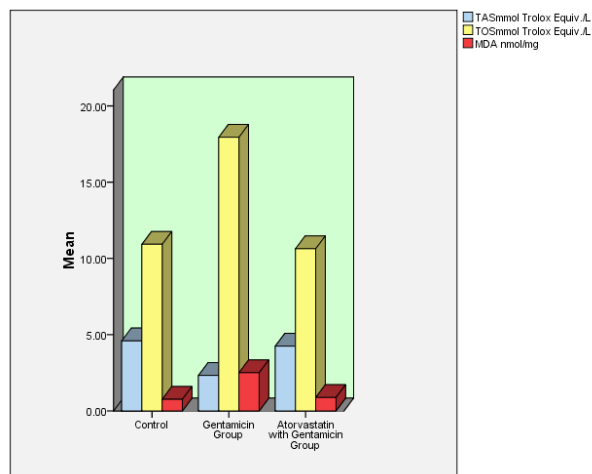


Figure 2: Mean \pm SEM for TAS, TOS, and MDA in the control group, gentamicin group, and Gentamicin with atorvastatin groups.

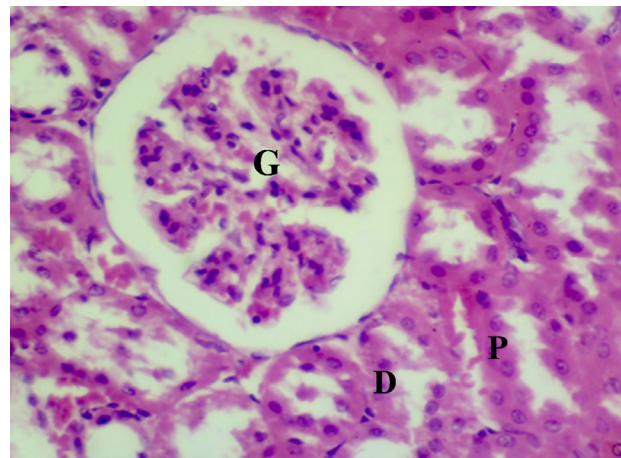


Figure 3: Photomicrograph showing normal section of rats' kidney of group I: (G) glomeruli (tuft of blood capillary). (P) renal proximal convoluted tubule, (D) renal distal convoluted tubule. (H&E stain 400x)

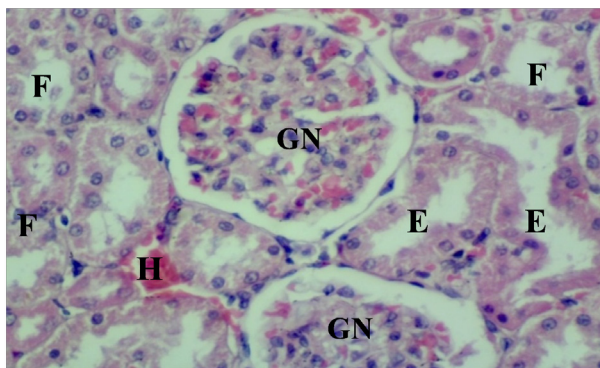


Figure 4: Histopathological changes of Kidney in group II (rats treated with gentamicin at dose 100 mg per kg per day i.p. for four weeks) demonstrated: necrotic and degenerative changes with abnormal shape and hemorrhage of the glomeruli (GN). Severe damage with disruption of epithelial lining cells was noticed. In the proximal convoluted tubules, complete disrupted epithelium and varying degree of necrosis were seen (E). Distal convoluted tubules revealed damage with flattened epithelium and elongated nuclei (F) in addition to hemorrhage (H).

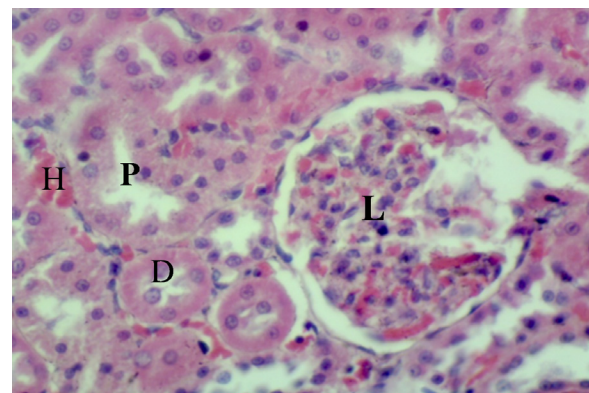


Figure 5: Histopathological changes of Kidney in group III of rats treated with gentamicin 100 mg per kg per day intraperitoneally concomitantly with Atorvastatin 10 mg per kg per day for four weeks revealed less damage, infiltration of polymorphonuclear cells inside capillary tuft (L), normal arrangement of tubules and normal brush border of proximal convoluted tubules (P), with mild hemorrhage (H) normal epithelial lining of distal convoluted tubule with vacuolization of nuclei (D).

Table 1: Effect of 4 weeks treatment with Gentamicin alone and with atorvastatin on the diameters of glomeruli and renal tubules of kidney.

Groups	Diameter of glomerulus of kidney (μm)	Diameter of proximal convoluted tubules of kidney (μm)	Diameter of distal convoluted tubules of kidney (μm)
Control	71.61 \pm 0.56	64.06 \pm 1.4	24.71 \pm 1.56
Gentamicin 100mg/kg	82.50 \pm 0.83	71.53 \pm 1.1	31.11 \pm 0.20
Gentamicin 100mg /kg+ Atorvastatin 10 mg/kg	70.10 \pm 2.38	68.26 \pm 0.8	25.50 \pm 0.60
L.S.D. 0.05	1.63	0.83	0.59

Regarding the effect on the diameters of glomeruli and renal tubules; it was found that gentamicin treatment results in significant raise ($p < 0.05$) in the diameters of glomeruli and renal tubules in comparison with the control group, while concomitant treatment with atorvastatin revealed normal diameters in comparison with the control group, Table 1.

DISCUSSION

Effect of Gentamicin on selected parameters

Injections of gentamicin in a dose of 100 mg per kg per day results in decreased renal function as characterized by increased serum urea and creatinine levels.

Serum urea level increased significantly, and this finding is consistent with that reported by A.A. Al-Dhawalie, this may be attributed to increasing the production of urea nitrogen due to protein catabolism, and insufficient excretion of urea nitrogen.¹⁹ Serum creatinine level increased significantly, and this result was consistent with a previous study performed by Al-Majed et al.,²⁰ this is due to reduction in glomerular filtration rate.²¹ Tissue MDA level increased significantly, and this finding was consistent with that obtained by Karatas et al.,²² this means that gentamicin treatment-induced lipid peroxidation as a results of oxidative stress production which is mediated by superoxide anions from the mitochondrial origin and hydroxyl radicals from hydrogen peroxide.²³

Cystatin C is a member from the cysteine protease family. It's a protein produced by cells that contain a nucleus at a constant rate. It has a low molecular weight so that it can be filtered readily through the glomeruli, and then in the proximal tubule, it undergoes reabsorption and metabolism.²⁴ Therefore, serum cystatin C level is a good indicator for evaluation of renal function, and its level starts to increase during renal disorders even when there is a moderate decline in GFR, so it's considered to be a more sensitive indicator than serum creatinine.^{25,26} Therefore, the significant elevation in serum cystatin c level in this study can be attributed to a reduction in the glomerular filtration rate.

Renal toxicity from gentamicin is usually attributed to the generation of reactive oxygen species.²⁷ This study revealed significant elevation in TOS and decreased in TAS in a nephrotoxic group compared to the control group. These findings are in harmony with studies of Hozayen et al., who found that administration of gentamicin to rats increases

hydrogen peroxide production in renal cortical mitochondria which results from increased production of superoxide anions. Both hydrogen peroxide and Superoxide anion can interact to form hydroxyl radical, which is reactive and unstable radical.²⁸

Effect of atorvastatin treatment on the studied parameters

Serum urea and creatinine levels decreased significantly, and this may be attributed to increasing glomerular filtration rate similar to that reported by Rajiv Agarwal, MD.²⁹ Tissue MDA level decreased significantly and this finding is in harmony with that found by V. Tandon et al, this is attributed to increasing nitric oxide which acts as a scavenger for superoxide free radical anions that is responsible for LDL oxidation,³⁰ in addition statins can reduce free radical generation, and this can explain the significant decrease in TOS and increase in TAS after atorvastatin treatment.³¹

Serum cystatin C decreased significantly after atorvastatin treatment, and this result was similar to that was found by (Akiko et al.), and this can be due to increase in glomerular filtration rate.³²

Histopathological examination of the kidney for the control group revealed normal histology, while those of gentamicin treated rats showed extensive damage. This may be attributed to the generation of the highly reactive species as a result of oxidative stress induced by gentamicin. On the contrary, the treatment with atorvastatin revealed a significant degree of protection for the tubules and glomeruli and this can be due to its antioxidant properties. These results came in consistent with other studies that demonstrated histological changes in kidney tissue of animals treated with gentamicin and the protective effects of various agents.³³⁻³⁵

CONCLUSION

This study showed that high dose gentamicin treatment can cause nephrotoxicity that can be prevented by coadministration of atorvastatin.

REFERENCES

- 1 Nouani, H., G.A. Kojouri and S. Habibian. Gentamicin and phenylbutazone nephrotoxicity in a calf, *Int. J. pharmacol.*, 2; 2006: 581-583.
- 2 S.Nayak-Rao. Aminoglycoside use in renal failure. *Indian journal of nephrology*, 20(3); 2010.

- 3 Parlakpinar, H. et al. Protective role of caffeic acid phenethyl ester (cape) on gentamicin-induced acute renal toxicity in rats. *Toxicology*, 207; 2005: 169-177.
- 4 Polat, A. et al. protective role of aminoguanidine on gentamicin-induced acute renal failure in rats. *Acta Histochem.*, 108; 2006: 365-371.
- 5 Markowitz, G.S. and M.A. Perazella, . Drug induced renal failure: A focus on tubulointerstitial disease. *Clin. Chim. Acta*, 2005: 351-583.
- 6 Villa, J; Pratley, RE . Ezetimibe/simvastatin or atorvastatin for the treatment of hypercholesterolemia in patients with the metabolic syndrome: the VYMET study. *Curr Diab Rep* 10 (3); 2010: 173–5.
- 7 McCormack, T et al. Incremental cholesterol reduction with ezetimibe/simvastatin, atorvastatin and rosuvastatin in UK General Practice (IN-PRACTICE): randomised controlled trial of achievement of Joint British Societies (JBS-2) cholesterol targets. *Int J Clin Pract* 64 (8); 2010: 1052–61.
- 8 Fried LF. Effects of HMG-CoA reductase inhibitors (statins) on progression of kidney disease. *Kidney Int* ; 74; 2008: 571–576.
- 9 Kerstin Amann and Kerstin Benz. Statins—beyond lipids in CKD. *Nephrol Dial Transplant*, 26; 2011: 407–410.
- 10 Veeresh Babu SV et al. Anogeissus latifolia prevents gentamicin induced nephrotoxicity in rats. *Int.J.Ph.Sci.*, 3(1); 2011
- 11 Ozbek E, et al . Atorvastatin prevents gentamicin-induced renal damage in rats through the inhibition of p38-MAPK and NF-kappaB pathways. *Ren Fail*;31(5); 2009:382-92.
- 12 Tomutso n. et al. Can malondialdehyde be used as biological marker of progression in neurodegenerative diseases? *J. Neurol.* 249; 2002:367-47.
- 13 Wills M.R.and Savory J. . Biochemistry of renal failure. *Ann. Clin. Lab. Sci.*; 11(4); 1981: 292-299.
- 14 Henry, R.J.,. Clinical chemistry, principles and technique, Harper and low, 1974: p.543.
- 15 Sunred, Shangai Yehua Biological Technology Co., Ltd., Shanghai, China) (Catalog No: 201-11-0146) with the working principle suggested by the producer.
- 16 Erel, O. . A novel automated direct measurement method for total antioxidant capacity using a new generation, more stable ABTS radical cation. *Clinical Biochemistry.*, 37(4); 2004 :277-285.
- 17 Erel, O. . A new automated colorimetric method for measuring total oxidant status. *Clinical Biochemistry.*, 38(12); 2005: 1103-1111.
- 18 Bancroft, J. D. ; and Stevens, A. (). Theory and Practice of Histological Techniques. Fourth edition. New York: Churchill Livingstone. 1999: pp 312.
- 19 A.A. Al-Dhawali. Influence of Baseline Serum Calcium Level on Gentamicin Nephrotoxicity in Neonates at a Teaching Hospital in Saudi Arabia. *World Applied Sciences Journal* 12 (7); 2011: 924-928.
- 20 A.A. Al-Majed, et al. protective effect of oral Arabic gum administration on gentamicin induced nephrotoxicity in rats. *Pharmacol. Res.*, 46; 2002:445-451.
- 21 B.V.S. Lakshmi and M. Sudhakar. Protective effect of zingiber officinale on gentamicin-induced nephrotoxicity in rats. *International journal of pharmacology*, 2010; ISSN 1811-7775.
- 22 Karatasx, Y., et al. Effect of tempol (4-hydroxy tempo) on gentamicin-induced nephrotoxicity in rats. *Fundam. Clin. Pharmacol.* 18; 2004: 79–83.
- 23 Basnakian, A. G., Kaushal, G. P., and Shah, S. V.. Apoptotic pathways of oxidative damage to renal tubular epithelial cells. *Antioxid. Redox Signal.* 4; 2002: 915–924.
- 24 Borges RL, et al. Is cystatin C a useful marker in the detection of diabetic kidney disease? *Nephron Clin Pract.* 114; 2010: c127-34.
- 25 Ozdemir AV, Akagac A, Mizrak ES. The Importance of Cystatin C in the Early Diagnosis of Renal Dysfunction in Renal Function Disorders. *Turk J Biochem* 13; 2015:51-8.
- 26 Demirtas S, Bozbas A, Akbay A. Diagnostic value of serum cystatin C for evaluation of hepatorenal syndrome. *Clin Chim Acta* 311; 2001:81-9.
- 27 Lobo, V., et al. Free radicals, antioxidants and functional foods: Impact on human health. *Pharmacogn Rev.*, 4(8); 2010: 118–126.
- 28 Hozayen, W., Bastawy, M. and Elshafeey, H.. Effects of aqueous purslane (portulaca oleracea) extract and fish oil on gentamicin nephrotoxicity in albino rats. *Nature and Science.*, 9(2); 2011: 47-62.
- 29 Rajiv Agarwal,MD . Effect of statin on renal function. *Mayo Clin Proc.*;82(11); 2007:1381-1390.
- 30 V. Tandon, et al. Pleiotropic effects of statins. *Indian J Pharmacol*;37(2); 2005:77-85.
- 31 Cordle A, et al. Mechanisms of statin-mediated inhibition of small G-protein function. *J Biol Chem* 280; 2005: 34202–34209.
- 32 Akiko Takazakura, et al. Renoprotective effects of atorvastatin compared with pravastatin on progression of early diabetic nephropathy. *journal of diabetes investigation*, 6(3); 2015: 346–353.
- 33 Rajitha Panonnummal, Joyamma Varkey and Dinoop D R. Protective effect of Atorvastatin against Vancomycin induced nephrotoxicity in albino rats. *Pharmacie Globale (IJCP)*, 8 (10); 2011.
- 34 Mustafa Cekmen, et al. Pomegranate Extract Attenuates Gentamicin-Induced Nephrotoxicity in Rats by Reducing Oxidative Stress. *Renal Failure*, 35(2); 2013: 268–274.
- 35 Karadeniz A, et al. Spirulina platensis protects against gentamicin-induced nephrotoxicity in rats. *Phytother Res.*22; 2008:1506–1510.